

THE GIANT CLAM:

AN ANATOMICAL AND HISTOLOGICAL ATLAS

JOHN H. NORTON AND GARETH W. JONES

Queensland Department of Primary Industries,
Oonoonba Veterinary Laboratory,
PO Box 1085,
TOWNSVILLE 4810
Queensland
Australia

Australian Centre for International Agricultural Research
Canberra 1992.

The Australian Centre for International Agricultural Research (ACIAR) was established in June 1982 by an Act of the Australian Parliament. Its mandate is to help identify agricultural problems in developing countries and to commission collaborative research between Australia and developing country researchers in fields where Australia has special research competence.

Where trade names are used this constitutes neither endorsement of, nor discrimination against, any product by the Centre.

ACIAR MONOGRAPH SERIES

This peer-reviewed series contains the results of original research supported by ACIAR, or material deemed relevant to ACIAR's research objectives. The series is distributed internationally, with an emphasis on the Third World.

© Australian Centre for International Agricultural Research,
GPO Box 1571, Canberra, ACT 2601

Norton, J.H. and Jones G.W. 1992. The Giant Clam: an anatomical and histological atlas. ACIAR Monograph. 142 p.


ISBN 1 86320 066 5

Typesetting and page layout by Sun Photoset Pty Ltd, Brisbane.

Printed by Watson Ferguson & Co., Brisbane.


ACKNOWLEDGMENTS

The authors sincerely thank the following individuals and organisations for their contributions which made this manual possible: Associate Professor John Lucas for the invitation to participate in the Giant Clam project, for his extensive support throughout the project and for reviewing this atlas; Dr. Denis Hoffmann for his efforts in procuring the funds; the Australian Centre for International Agricultural Research (ACIAR) for funds to complete the work; the staff of the Oonoonba Veterinary Laboratory for technical support, in particular, Mr Ian Anderson for support, for guidance and for reviewing this atlas; Dr Steve Johnson for reviewing this atlas; Mr Malcolm Shepherd and Mrs Helen Long for histopathology; Mrs Thea Linnan, Miss Ellise Schwarz and Miss Sherrie Milsom for typing the manuscript; Miss Mareya Dashorst for line drawings; Mr Andrew Fisk for caring for the clams; Mr Jan Kaczmarek for translating scientific papers; Mr Doug Freckelton and staff of both the Animal Research Institute and Department of Primary Industries' Fisheries Libraries for the acquisition of references; Mr Howard Prior of the Animal Research Institute for electron-microscopy; Mrs Heather Winsor of the James Cook University for electronmicroscopy; Mr Leigh Winsor of the Zoology Department, James Cook University for assistance with histochemistry; Dr Richard Braley and Mr Jeremy Barker of James Cook University for advice; the staff of the Orpheus Island Research Station for the supply of clams; staff from the following ACIAR collaborating centres: University of the Philippines Marine Science Institute, Bolinao, Philippines; Silliman University Marine Laboratory, Dumaguete, Philippines; Fisheries Division, Ministry of Primary Industries, Fiji; Fisheries Department, Tonga; Ministry of Marine Resources, Rarotonga, Cook Islands; Professor Brian Morton of the University of Hong Kong for technical advice; Dr. P. Graham Oliver of the National Museum of Wales for reviewing this atlas.



CONTENTS

Foreword	7	The Kidney and Pericardial Glands	
Introduction	9	Kidney — anatomy	84
The Shell		Pericardial gland — anatomy	85
Shell — morphology	16	Kidney — histology	87
Shell — comparative anatomy	21	Pericardial gland — histology	88
The Mantle and Water Chambers		The Nervous System, the Hyaline Organs and the Statocysts	
Mantle — anatomy	26	Nervous system — anatomy	94
Water chambers — anatomy	28	Hyaline organs — anatomy	96
Mantle — comparative anatomy	30	Statocysts — anatomy	96
Mantle — histology	31	Nervous system — histology	99
The Ctenidia and Labial Palps		Hyaline organs — histology	99
Ctenidia — anatomy	38	Statocysts — histology	100
Labial palps — anatomy	40	The Gonads	
Ctenidia — comparative anatomy	41	Gonad — anatomy	104
Ctenidia — histology	42	Gonad — histology	105
Labial palps — histology	44	The Zooxanthellal Tube System and Zooxanthellae	
The Adductor Muscle		Zooxanthellal tube system — anatomy	110
Adductor muscle — anatomy	50	Zooxanthellal tube — histology	114
Adductor muscle — histology	51	Zooxanthellae — histology	114
The Byssal Organ and Foot		Relevant Literature	119
Byssal organ and foot — anatomy	56	Glossary	125
Byssal organ and foot — comparative anatomy	57	Histological stains	131
Byssal organ and foot — histology	58	Techniques	135
The Digestive System		Index	139
Digestive system — anatomy	64		
Digestive system — histology	66		
The Heart and Haemolymph System			
Heart — anatomy	74		
Pericardium — anatomy	75		
Arterial system — anatomy	75		
Venous system — anatomy	76		
Heart and haemolymph system — histology	79		




FOREWORD

Giant clams are a source of food, and a source of income from the sale of meat and shell, for many of the peoples of the Indo-Pacific region. The depletion of stocks of giant clams and the need for a suitable species for mariculture led to several major projects aimed at the culture of this unique group of animals.

Once the giant clam had been successfully cultured, a need arose for information on diseases and disease status. Information was needed to diagnose causes of abnormalities, sickness and death as well as a basis for the translocation of disease-free and parasite-free juvenile clams to restock depleted areas. The diagnosis of disease presupposes an adequate knowledge of the anatomy and histology of these animals, hence the study which produced this manual.

The aim of this manual was to produce a simple, easy-to-follow guide to the anatomy and histology of the Giant Clam *Tridacna gigas*, together with some information on the comparative anatomy of the other species of giant clam. It should be a text which is very useable, especially by people in the developing countries of the Pacific region. The techniques described here were chosen not only because they worked, but, where possible, because they were relatively simple, cheap and safe. The materials needed are more available than alternatives. This manual is **not** intended as an academic treatise on anatomy and histology, nor does it include embryology, developmental anatomy and physiology. The comparative anatomy of the 8 species of clams is given where available. There are likely to be many more differences than those recorded here but they await the availability of further resources. This manual has many figures but little text since 'one picture is worth ten thousand words'.

The techniques used to produce this manual are also included for those who wish to try them.



INTRODUCTION

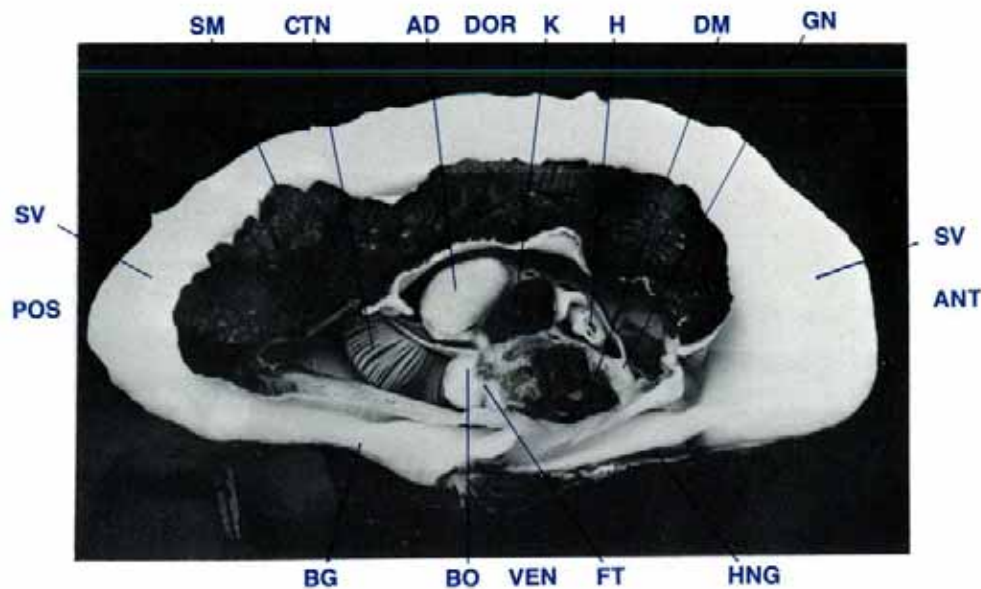


Figure 1 A mid-longitudinal section of a clam to show the internal organs (35 cm shell length, formalin fixed).

AD adductor muscle, ANT anterior, BG byssal gape, BO byssal organ, CTN ctenidia, DM digestive mass, DOR dorsal, FT foot, GN gonads, H heart, HNG hinge, K kidney, POS posterior, SM siphonal mantle, SV shell valve, VEN ventral.

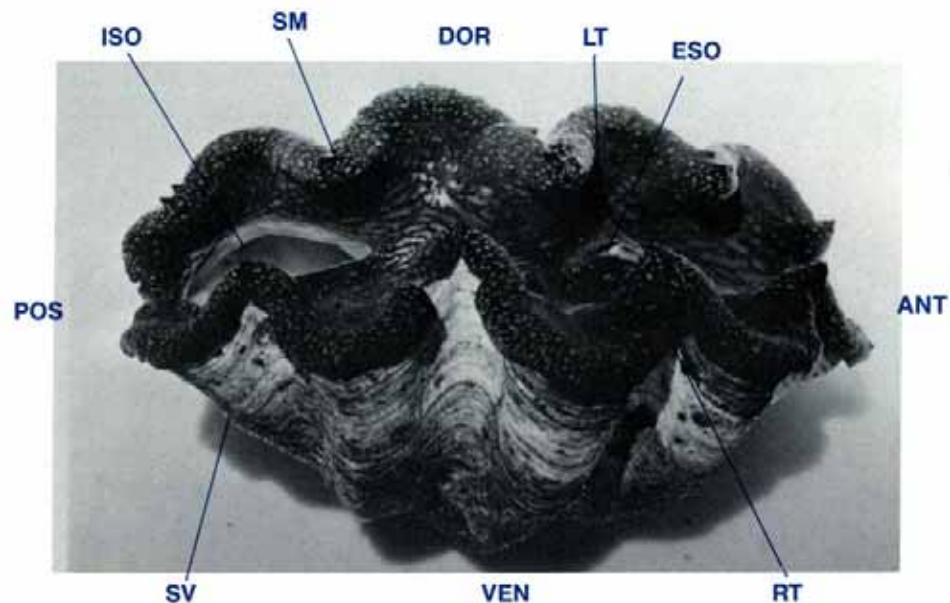


Figure 2 Dorsolateral view of a live clam (35 cm shell length).

ANT anterior, DOR dorsal, ESO excurrent siphonal orifice, ISO incurrent siphonal orifice, LT left, POS posterior, RT right, SM siphonal mantle, SV shell valve, VEN ventral.

Overview

Giant clams are classified as follows:

Phylum:	Mollusca
Class:	Bivalvia
Order:	Veneroida
Superfamily:	Cardiacea
Family:	Tridacnidae
Genus:	<i>Tridacna</i> and <i>Hippopus</i>
Species:	<i>T. gigas</i> , <i>T. derasa</i> , <i>T. maxima</i> , <i>T. crocea</i> , <i>T. squamosa</i> , <i>T. tevoroa</i> , <i>H. hippopus</i> , <i>H. porcellanus</i>

The giant clams are different to other bivalve molluscs (Yonge 1975). They orient themselves with their hinge surface adjacent to the sea bed. The siphonal tissue is greatly expanded to become the dorsal siphonal mantle. Within this mantle large numbers of symbiotic algae, dinoflagellates *Symbiodinium microadriaticum*, commonly called zooxanthellae, live. The only other bivalve which has symbiotic algae is the heart cockle *Cardinium* sp. and in this species, the algae are not in the siphonal tissue. The giant clam (Figs 1, 2) has an external skeleton of two shell valves joined by a hinge ventrally. The valves are closed by a large, central adductor muscle. The organs are enclosed within a mantle of tissue which secretes the shell valves. The dorsal part of the mantle contains algae which

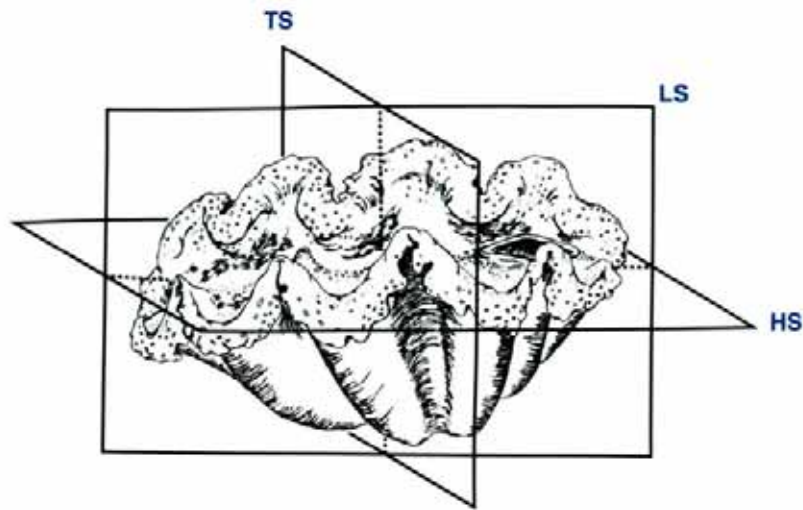


Figure 3 Three dimensional drawing to show the planes in which the clam has been sectioned in this atlas.

HS horizontal section, LS longitudinal section, TS transverse section.

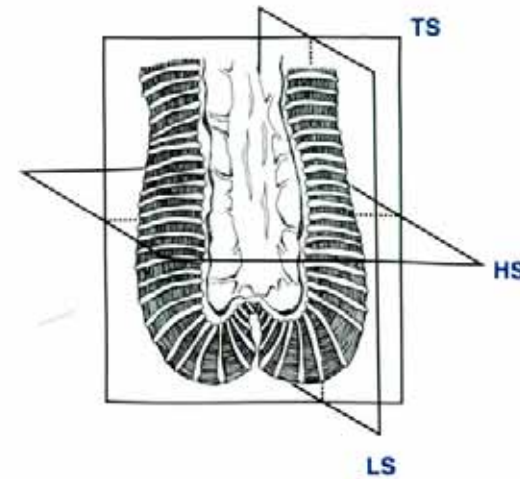


Figure 4 Three dimensional drawing to show the planes in which the lamella of the ctenidia has been sectioned in this atlas.

HS horizontal section, LS longitudinal section, TS transverse section.

supply nutrients to the clam. The presence of algae (zooxanthellae) in the clam's expanded siphonal tissue (= siphonal mantle) is unique. The clam has two pairs of ctenidia (gills) for oxygen exchange and to filter the sea water for food. There is a stomach, intestine and digestive gland. A bi-lobed kidney is present for the excretion of wastes. A heart pumps haemolymph through an open circulatory system. A foot enables the small clam to move around while a byssus anchors the clam to the sea bed. A simple nervous system is present. Male and female gonads form around the digestive mass.

Species

This is a description of *T. gigas* unless otherwise noted.

Orientation

Most bivalves orientate themselves so that the hinge is dorsal. To follow a similar convention when describing the orientation of the giant clam, whose hinge is ventral, would lead to unnecessary confusion.

For the purpose of this atlas, the clam is orientated by calling the hinge and byssal gape edges ventral, and the free, outer edges of the shell valves dorsal (Fig. 2). The mouth is anterior and is located in the 'hinge' end of the clam. The byssal gape and the incurrent siphonal orifice through which the ctenidia (gills) are visible in the live clam are posterior. This follows the descriptions as used by Rosewater (1965).

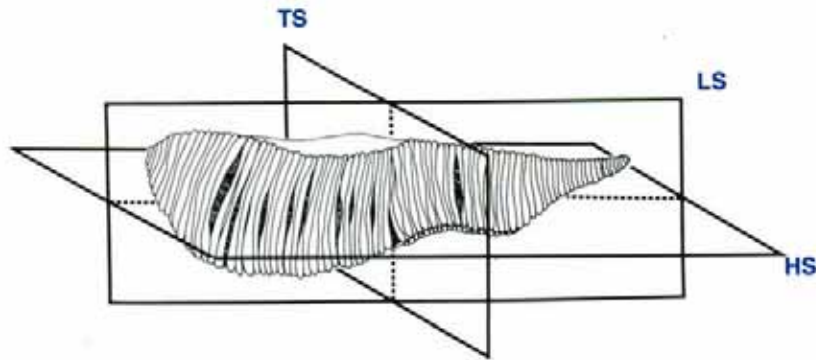


Figure 5 Three dimensional drawing to show the planes in which the demibranch of the ctenidia has been sectioned in this atlas.
HS horizontal section, **LS** longitudinal section, **TS** transverse section.

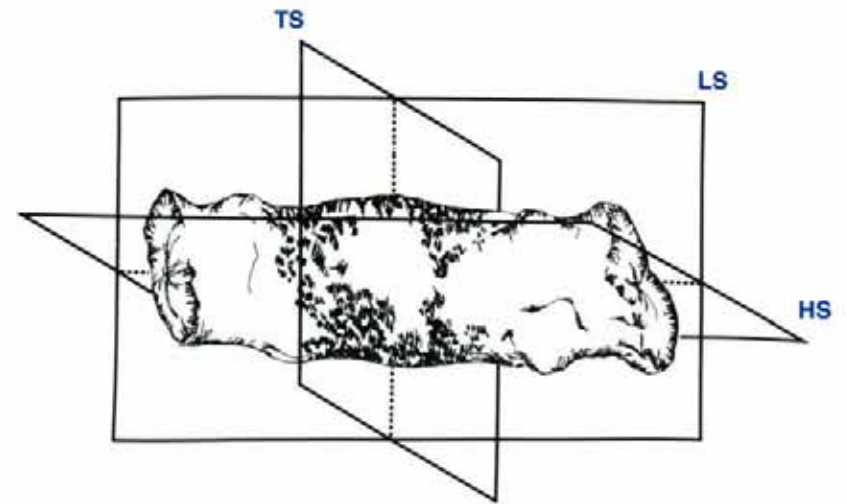


Figure 6 Three dimensional drawing to show the planes in which the adductor muscle has been sectioned in this atlas.
HS horizontal section, **LS** longitudinal section, **TS** transverse section.

Histological Descriptions and Stains

Unless otherwise stated, the histological descriptions are of tissues stained by haematoxylin and eosin.

Abbreviations

Abbreviations used in the captions of the figures are as follows:—

cm	centimetres
H & E	haematoxylin and eosin stain
HS	horizontal section
LS	longitudinal section
MgCl ₂	magnesium chloride
PAS	periodic acid-schiff stain
PAS/diastase	periodic acid-schiff stain /diastase digestion
PTAH	phosphotungstic acid haematoxylin stain
TS	transverse section

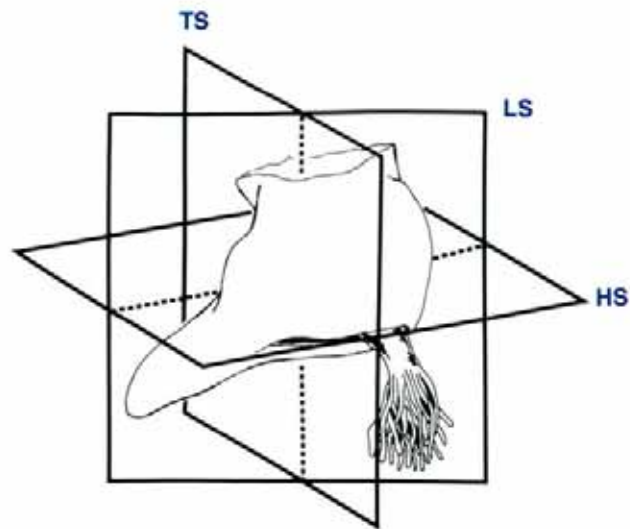


Figure 7 Three dimensional drawing to show the planes in which the byssal organ and foot has been sectioned in this atlas.

HS horizontal section, **LS** longitudinal section, **TS** transverse section.

Orientation of Photographs


Where possible, photographs have been presented with the dorsal aspect of the clam towards the top of the photograph.

Scale of Photographs

Bar scales are quoted in micrometres.

Sectioning of Tissues

- | | |
|--------------|---|
| TS | a transverse section cut at right angles and vertical to the longitudinal axis of the clam (Fig. 3). |
| LS | a longitudinal section cut parallel and vertical to the longitudinal axis of the clam (Fig. 3). |
| HS | a horizontal section cut parallel to the surface on which the clam rests when in a normal attitude and at right angles to the longitudinal axis (Fig. 3). |
| Note: | In the figure captions, TS, LS and HS refer to the clam. However, if sections are cut in reference to a specific organ, that organ's name will precede the symbol indicating the type of section, e.g. 'adductor muscle TS' is a transverse section across the longitudinal axis of this muscle (Fig. 6). |



THE SHELL

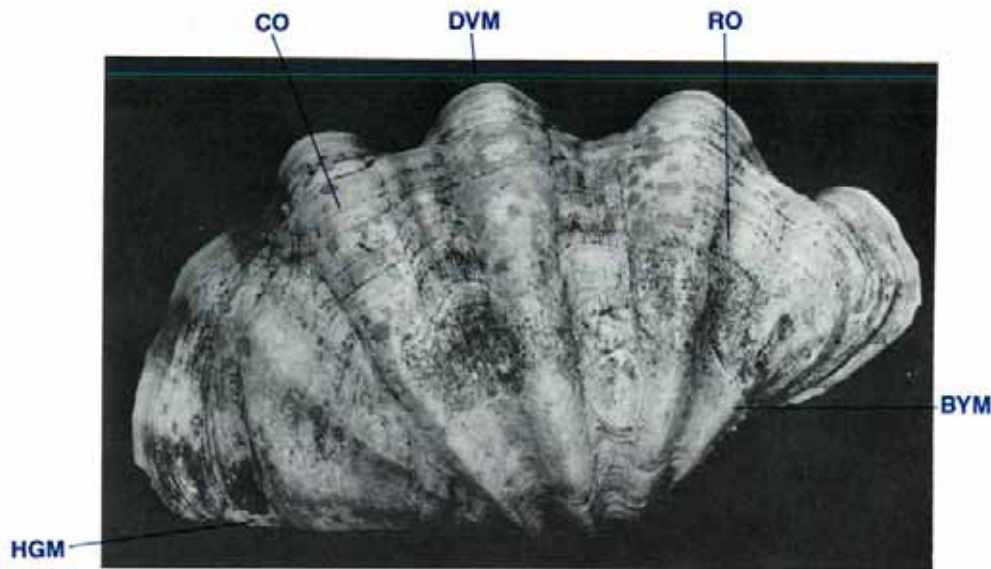


Figure 8 Lateral, external view of left valve (shell length 35 cm).
BYM byssal margin, **CO** concentric ornamentation, **DVM** dorsal valve margin, **HGM** hinge margin, **RO** radial ornamentation.

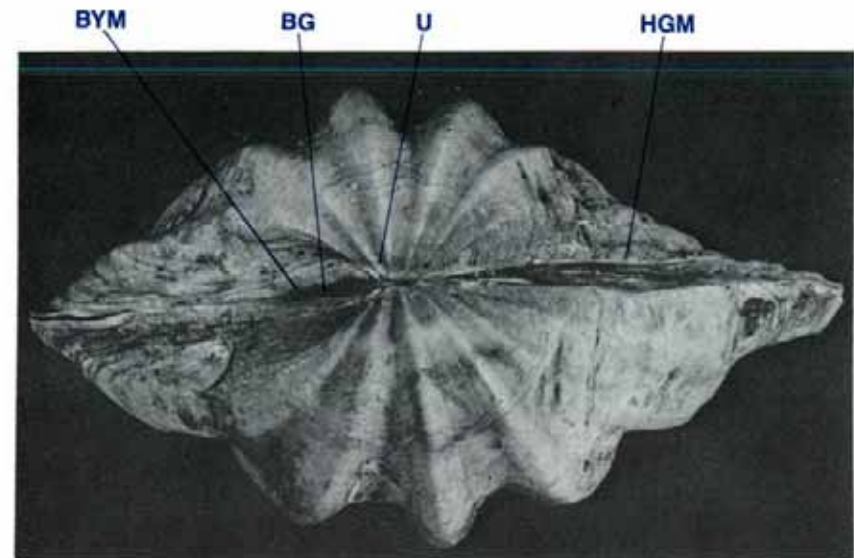


Figure 9 Ventral, external view of both valves (shell length 35 cm).
BG byssal gape, **BYM** byssal margin, **HGM** hinge margin, **U** umbo.

Shell — Morphology

External Shell Surface

The shell or external skeleton consists of two similar valves, one left and one right valve, joined ventrally by a thick inner and a thin outer hinge ligament. The shell valves are suboval to fan-shaped in outline and the angle formed at the umbos by the hinge margin and the byssal margin usually exceeds 150° (Fig. 8). The hinge margin is approximately half the length of the shell (Fig. 9). The valves are moderately to strongly inflated and have a small to nearly closed byssal orifice (Fig. 9). The external surfaces are rough, greyish white and are encrusted with a range of marine organisms. The wall of each valve is thicker ventrally

than dorsally and has a primary radial sculpture of 4 to 6 strongly convex, rib-like folds. Secondary radial ornament consists of rather evenly spaced riblets on both the folds and their broad interstices. The radial riblets are interrupted by fine concentric lines of growth. Scales are limited to the summit of folds near the umbos. The dorsal shell margins are broadly fan-shaped in outline and undulate with a series of 4–5 sharply pointed medially projecting interdigitating processes representing extremities of rib interstices (Fig. 10). The edge of the byssal orifice has a series of 4–7 shallow grooves (Fig. 11).

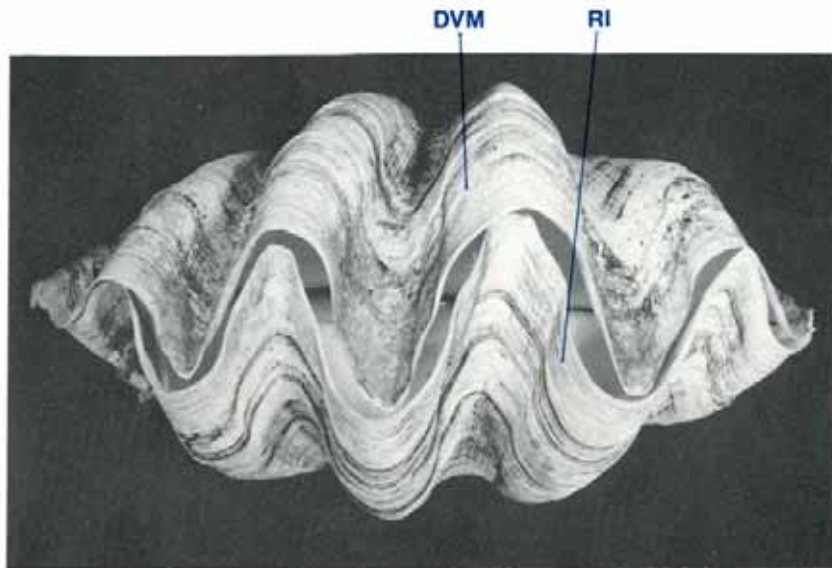


Figure 10 Dorsal view of the margins of the shell valves (shell length 35 cm).
DVM dorsal valve margin, **RI** rib interstices.

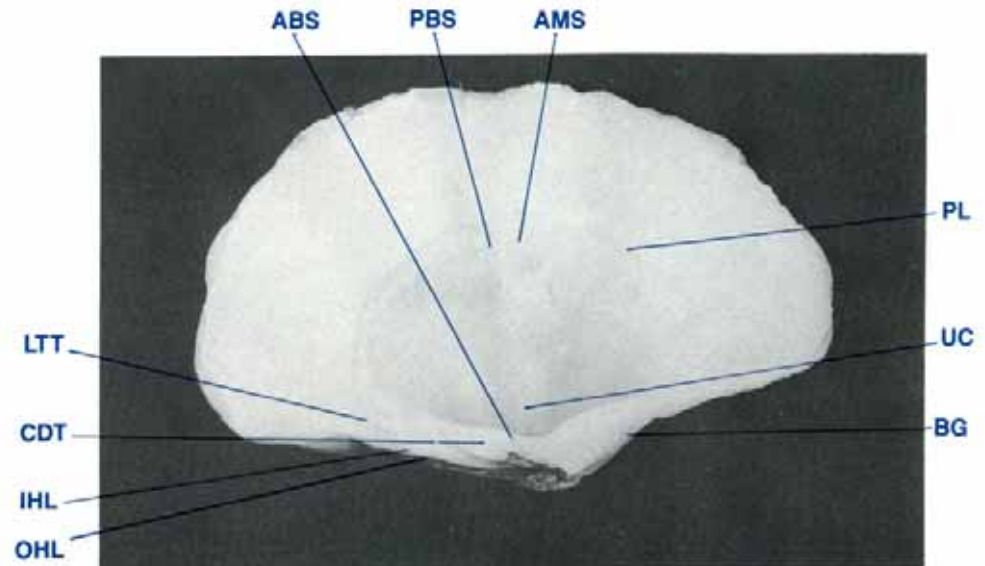


Figure 11 Inner surface of right valve (shell length 20 cm).

ABS anterior byssal/pedal retractor muscle scar, **AMS** adductor muscle scar, **BG** byssal gape (edge), **CDT** cardinal tooth, **IHL** inner hinge ligament, **LTT** lateral tooth, **OHL** outer hinge ligament, **PBS** posterior byssal/pedal retractor muscle scar, **PL** pallial line, **UC** umbonal cavity.

Internal Shell Surface

The interior of the valves is porcellaneous and white (Fig. 11). Midway between the dorsal margin of the shell valve and the umbo, there is a thin scar, the pallial line, which is the attachment for the siphonal mantle retractor muscles. The pallial line runs from above the lateral tooth around the middle inner surface of each valve and then turns ventrally to run parallel to the byssal gape margin a short distance medial to that structure. It ends in the umbonal cavity. The area enclosed by the pallial line is the lateral boundary of the lateral mantle cavity. Its surface is dull white compared to the remainder of the internal valve surface which is glossy white. Adjacent to the pallial line dorsally and posterior to the centre of the valve is the large, circular

adductor muscle scar. Adjacent to the upper portion of this scar and just anterior to it, is the posterior pedal/byssal retractor muscle scar which is less than half the size of the adductor muscle scar. The muscle scar surfaces are glossy white.

Hinge Region

When the hinge region is viewed dorsally from within the clam (Fig. 12), two sets of interlocking teeth are seen. Anteriorly there are the small lateral teeth, adjacent to the anterior end of the pallial line. When the shell valves close, the right lateral tooth closes dorsal to the left lateral tooth. Moving posteriorly towards

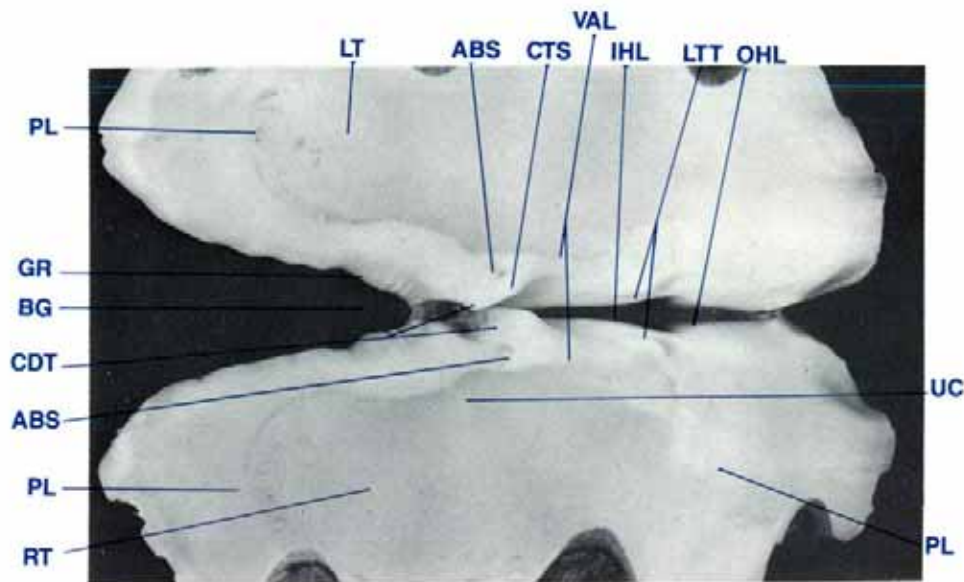


Figure 12 Byssal gape and ligamental hinge region viewed dorsally from inside the left and right shell valves (shell length 20 cm).

ABS anterior byssal/pedal retractor muscle scar, **BG** byssal gape, **CDT** cardinal teeth, **CTS** cardinal tooth socket, **GR** grooves, **IHL** inner hinge ligament, **LT** left, **LTT** lateral teeth, **OHL** outer hinge ligament, **PL** pallial line, **RT** right, **UC** umbonal cavity, **VAL** visceral-pallial attachment lines.

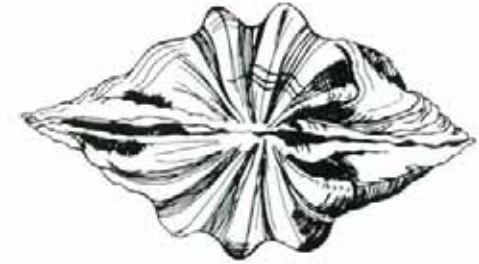

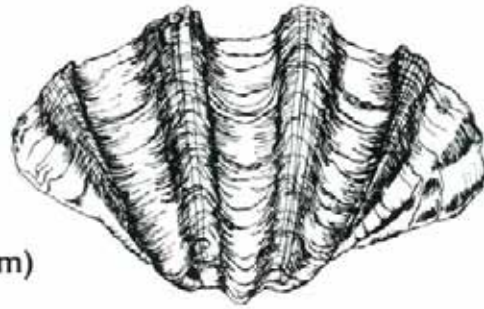
the byssal gape, the large paired elongated cardinal teeth are seen. When the shell valves close, the left cardinal tooth closes dorsal to the right cardinal tooth which inserts into a groove below the left cardinal tooth, the cardinal tooth socket.

Lateral to the cardinal teeth are the attachment scars of the anterior byssal/pedal retractor muscles. Also lateral to the cardinal teeth are the visceral-pallial attachment lines to which the muscle bands surrounding the digestive and reproductive organs anchor. The umbonal cavities where the posterior pallial line on each shell valve ends are also to be found here.

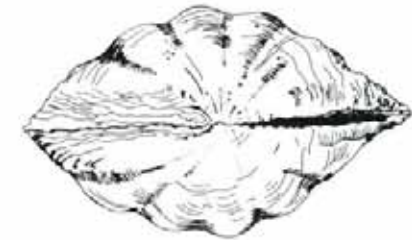
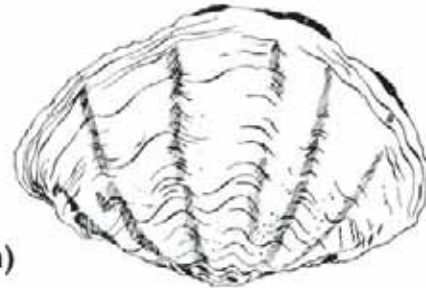Between the shell valves, there are two amber-coloured hinge ligaments, an outer and an inner (Figs 11, 12). The outer hinge

ligament is the thinner of the two and joins the shell valves for the full length of the hinge margin. The inner hinge ligament is much thicker than the outer ligament and joins the shell valves along the hinge margin from the umbo to just beneath the lateral teeth.

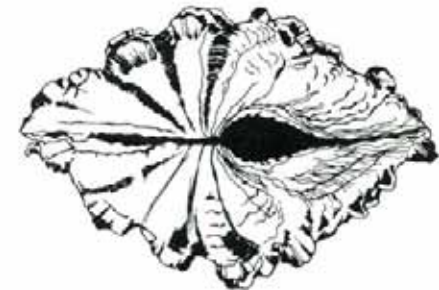
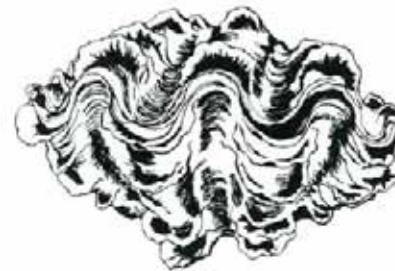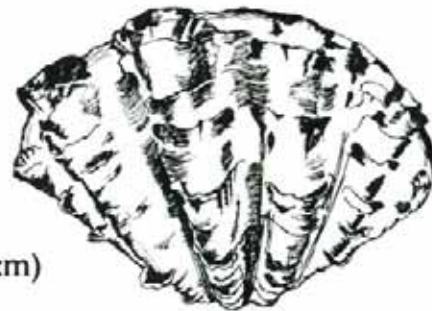T. gigas shell (shell length 35cm)



T. derasa shell (shell length 20cm)



T. squamosa shell (shell length 17cm)



T. maxima shell (shell length 18cm)

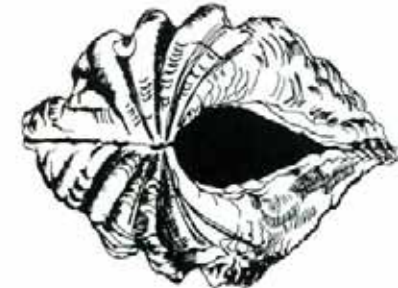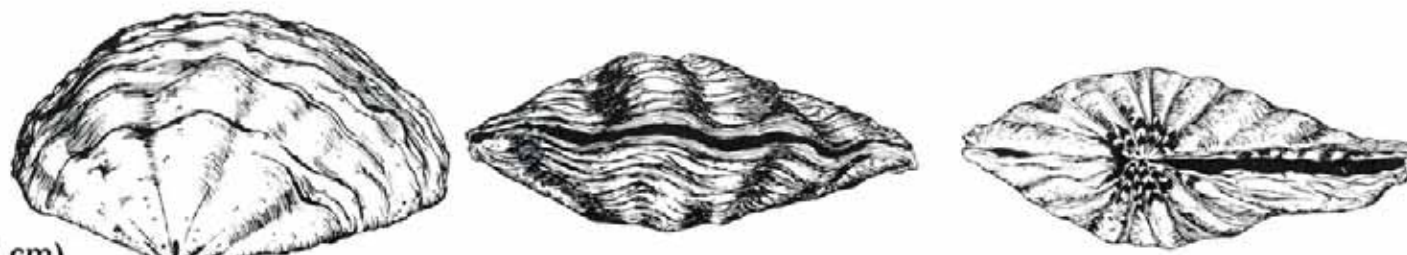


Figure 13 Lateral, dorsal and ventral views of the shell valves of *T. gigas*, *T. derasa*, *T. squamosa* and *T. maxima*.


T. crocea shell (shell length 10 cm)



T. tevoroa shell (shell length 45 cm)



H. hippopus shell (shell length 22 cm)



H. porcellanus shell (shell length 15 cm)

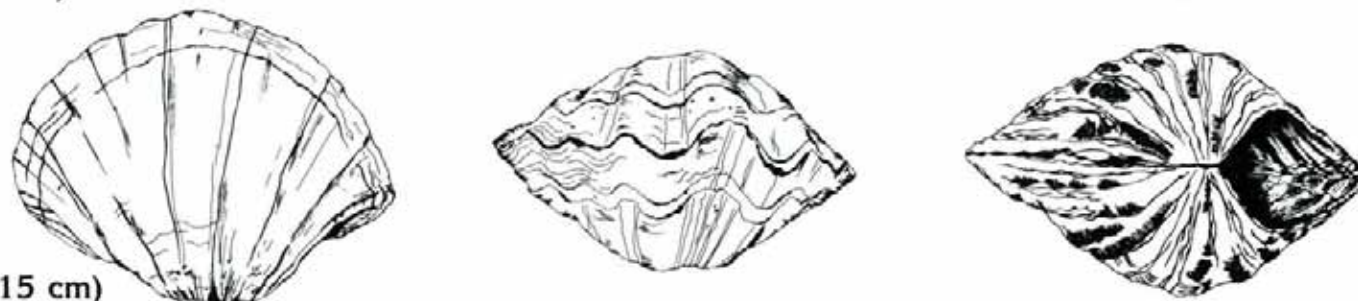


Figure 14 Lateral, dorsal and ventral views of the shell valves of *T. crocea*, *T. tevoroa*, *H. hippopus* and *H. porcellanus*.

Key to the Shell Morphology of the Giant Clams

- | | |
|--|---|
| <p>1a. Location of umbo central 2</p> <p>1b. Location of the umbo other than central 3</p>
<p>2a. Upper valve margins, smooth and undulating.
Shell shape, semicircular.
Adult shell contains scutes <i>T. squamosa</i> (Fig. 13)</p> <p style="margin-left: 40px;">Maximum size — 40cm
Umbo location — central
Shell colour — white (orange,pink)
Rib depth — moderate to deep
Byssal gape — small to medium
Tightly fitting teeth along byssal orifice — absent
Adductor muscle scar location — posterior
Byssal retractor muscle scar area : adductor muscle scar
area ratio — less than 0.25
Hinge length : shell length ratio equal to or greater than 0.5</p> <p>2b. Upper valve margins, smooth with elongate triangular projections.
Shell shape, broadly sub-oval to fan shaped.
Scutes absent in adults <i>T. gigas</i> (Fig. 13)</p> <p style="margin-left: 40px;">Maximum size — greater than 100 cm
Umbo location — central
Shell colour — white (yellow)
Rib depth — deep
Byssal gape — small
Tightly fitting teeth along byssal orifice — absent
Adductor muscle scar location — posterior
Byssal retractor muscle scar area : adductor muscle scar area ratio 0.25
Hinge length : shell length ratio — approximately 0.5</p> | <p>3a. Byssal gape absent 4</p> <p>3b. Byssal gape present 5</p>
<p>4a. Strawberry-red blotches in bands on the exterior.
Shell, elongate to ovate triangular, or sub-rhomboidal.
Rib depth, deep <i>Hippopus hippopus</i> (Fig. 14)</p> <p style="margin-left: 40px;">Maximum size — 45 cm
Scutes in adult — absent
Umbo location — posterior
Upper valve margins — undulating with uneven edge
Byssal gape — absent
Tightly fitting teeth along byssal orifice — present
Adductor muscle scar location — central
Byssal retractor muscle scar — absent
Hinge length : shell length ratio — equal to or greater than 0.5</p> <p>4b. Coloured occasionally with pale, strawberry blotches, scattered or concentric.
Shell shape, semicircular.
Rib depth, shallow to moderate .. <i>Hippopus porcellanus</i> (Fig. 14)</p> <p style="margin-left: 40px;">Maximum size — 45 cm
Scutes in adults — absent
Umbo location — posterior
Upper valve margins — undulating with uneven edge
Byssal gape — absent
Tightly fitting teeth along byssal orifice — present
Adductor muscle scar location — anterior to central
Byssal retractor muscle scar — absent
Hinge length : shell length ratio — greater than 0.5</p> |
|--|---|

- 5a. Location of umbo posterior 6
 5b. Location of umbo anterior 7
- 6a Shell white with no colouration or coloured blotches
 *T. derasa* (Fig. 13)
- Rib depth — moderate to shallow
 Maximum size — 60 cm
 Shell shape — semicircular
 Scutes in adults — absent
 Umbo location — posterior
 Upper valve margins — smooth, undulating
 Byssal gape — small
 Tightly fitting teeth along byssal orifice — absent
 Adductor muscle scar location — posterior
 Byssal retractor muscle scar area : adductor muscle
 scar area ratio — less than 0.25
 Hinge length : shell length ratio — greater than 0.5
- 6b. Shell with strawberry-red bands on the ventral region of
 the external radial folds. *T. tevoroa* (Fig. 14)
- Rib depth — shallow
 Maximum size — 53cm
 Shell shape — semicircular
 Scutes in adults — absent
 Umbo location — posterior
 Upper valve margins — smooth, undulating
 Byssal gape — small
 Tightly fitting teeth along byssal orifice — absent
 Adductor muscle scar location — posterior
 Byssal retractor muscle scar area : adductor muscle
 scar area ratio — less than 0.25
 Hinge length : shell length ratio — greater than 0.5
- 7a. Shell, triangular, ovate.
 Rib depth, shallow.
 Maximum size, 15 cm *T. crocea* (Fig. 14)
- Scutes in adults — present
 Umbo location — anterior
 Shell colour — white (orange)
 Upper valve margins — smooth, undulating
 Byssal gape — large
 Tightly fitting teeth along byssal orifice — absent
 Adductor muscle scar location — posterior to central
 Byssal retractor muscle scar area : adductor muscle
 scar area ratio — 0.5
 Hinge length : shell length ratio — less than 0.5
- 7b. Shell, elongate to short obtuse, triangular.
 Rib depth, moderate. *T. maxima* (Fig. 13)
- Maximum size — 35cm
 Scutes in adults — present
 Umbo location — anterior
 Shell colour — white
 Upper valve margins — smooth, undulating
 Rib depth — moderate
 Byssal gape — large
 Tightly fitting teeth along byssal orifice — absent
 Adductor muscle scar location — posterior
 Byssal retractor muscle scar area : adductor muscle
 scar area ratio — 1.0
 Hinge length : shell length ratio — less than 0.5





THE MANTLE AND WATER CHAMBERS

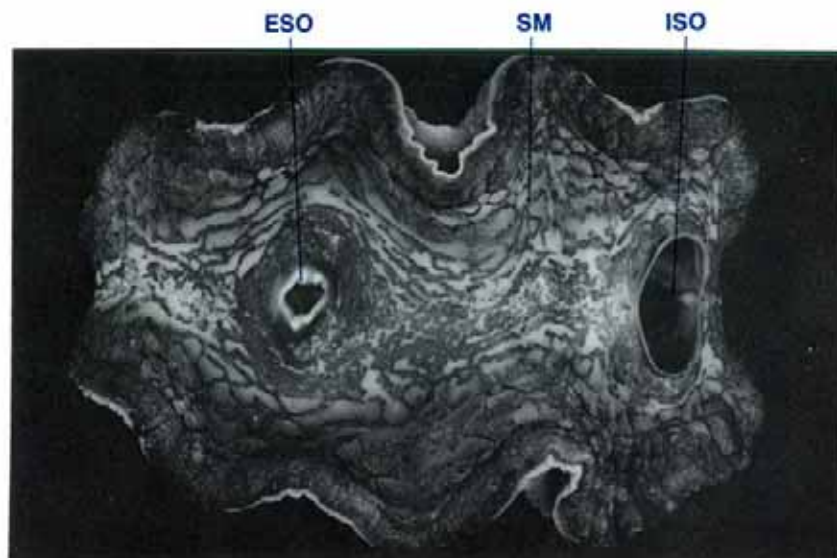


Figure 15 Dorsal view of a clam showing the siphonal mantle, shell valves removed (shell length 20 cm, MgCl₂ sedated).

ESO excurrent siphonal orifice, ISO incurrent siphonal orifice, SM siphonal mantle.

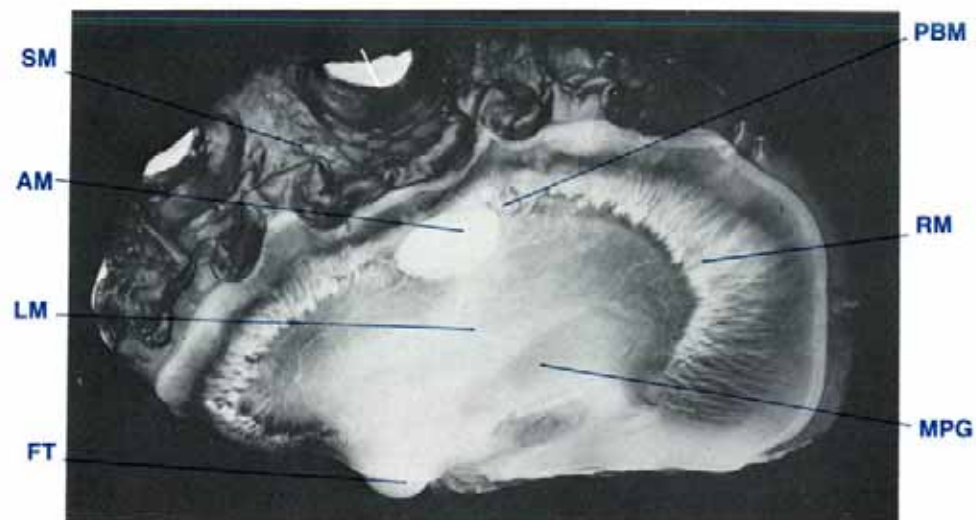

Figure 16 Lateral view of a clam showing the lateral mantle, right shell valve removed (shell length 35 cm, MgCl₂ sedated).

AM adductor muscle, FT foot, LM lateral mantle, MPG mantle pericardial gland, PBM posterior byssal/pedal retractor muscle, RM retractor muscles (siphonal mantle), SM siphonal mantle.

Mantle — Anatomy

The mantle encloses the soft organs. It has three openings, the incurrent and excurrent siphonal orifices, and the byssal gape (Figs 15, 17). The mantle has two main parts, a thick muscular, pigmented siphonal or dorsal mantle (Fig. 15) and a thin, translucent lateral mantle (Figs 16, 17). The lateral edge of the siphonal mantle and the edge of the lateral mantle adjacent to the byssal gape have three parallel folds namely the inner, middle and outer folds.

The siphonal mantle (Fig. 15) which is visible in a relaxed clam with its shell valves open, is the greatly expanded inner fold. This fold covers the area between the valves and extends beyond and

over the upper edges of the shell valves when the clam is open (Fig. 2). The inner folds of each side are fused along the longitudinal midline except for the elongated incurrent siphonal orifice in the posterior end of the mantle and the small, nozzle-shaped excurrent siphonal orifice in the anterior half of the mantle. No guard tentacles are present around the incurrent siphonal orifice. Zooxanthellae and iridophores colour the inner fold of the siphonal mantle. Numerous iridescent blue/green circles surround the hyaline organs or 'eyes' which are present mainly along the edge of the siphonal mantle (Fig. 130). Numerous white retractor muscles (Fig. 16) attach the siphonal mantle to the inner surface of each shell valve along the pallial line. The middle and outer folds of the siphonal mantle are not easily seen in a normal living clam (Figs 16, 24). They consist of

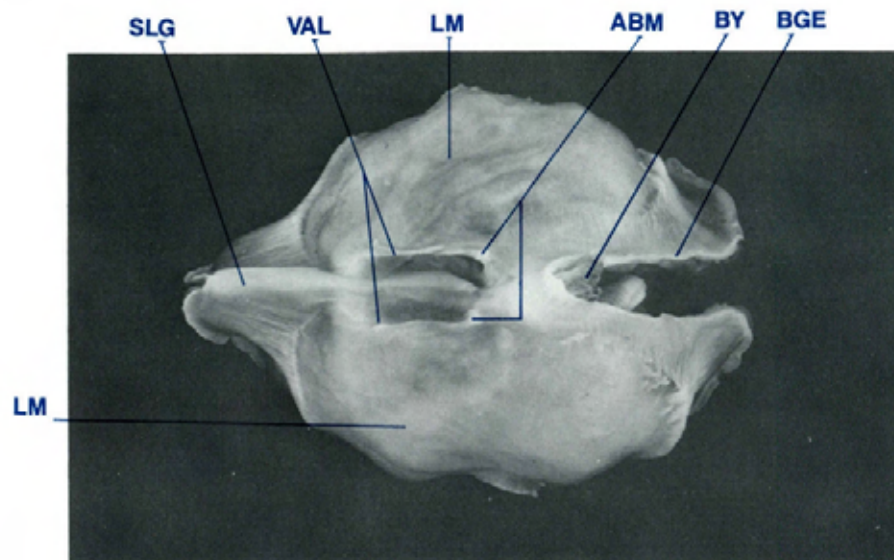


Figure 17 Ventral view of a clam to show the lateral mantle, shell valves removed (shell length 20 cm, MgCl₂ sedated, formalin fixed).

ABM anterior byssal/pedal-retractor muscles, **BGE** byssal gape edge, **BY** byssus, **LM** lateral mantle, **SLG** supraligamental (hinge) gland, **VAL** visceral-pallial attachment lines.

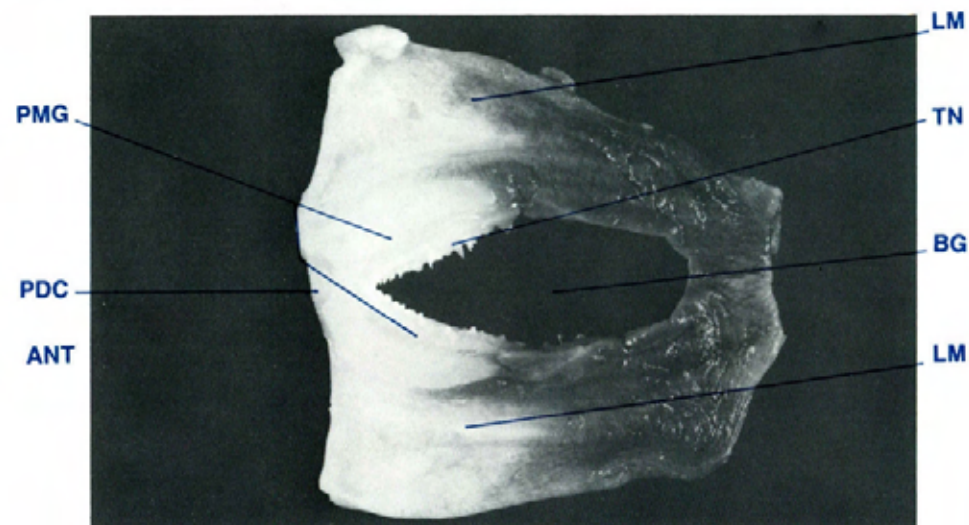


Figure 18 Dorsal view of the pallial mucous gland (shell length 20 cm, MgCl₂ sedated).

ANT anterior, **BG** byssal gape, **LM** lateral mantle, **PDC** pedal cavity, **PMG** pallial mucous gland, **TN** tentacles.

two parallel folds between the large inner fold and the inner surface of the shell valve. The inner surface of the outer fold contains the periostracal gland.

The lateral mantle (Figs 16, 17) is a thin, translucent membranous structure which covers the inner surfaces of the shell valves. It is attached to the siphonal mantle ventral to that organ's attachment to the shell valves along the pallial line. The lateral mantle adheres closely to the inner surface of each shell valve and meets ventrally over the ligamental hinge area to form the mantle isthmus. Below this latter structure there is the supraligamental or hinge gland. The normally non-existent space between the lateral mantle and the inside of each shell valve is the extra-pallial cavity. Lateral to the supraligamental gland, the mantle and the muscular wall of the digestive mass and reproductive organ are attached to the shell valves along the

visceral-pallial attachment lines (Figs 12, 17). Posteriorly, the mantle is attached to the shell valves along the pallial line adjacent to the byssal gape (Figs 11, 12).

The edge of the lateral mantle, adjacent to the byssal gape, has three folds similar to those of the siphonal mantle (Fig. 31). However, there are differences. The inner fold is small. The middle fold is large and has tentacles. The outer fold contains the periostracal gland on its inner surface. Between the three folds of the byssal gape edge and the inner surface of the lateral mantle is the pallial mucous gland (Fig. 18). It is a large, white, collar-shaped organ which is wider anteriorly than posteriorly. A depression in the anterior of the gland is the pedal cavity into which the end of the foot retracts.

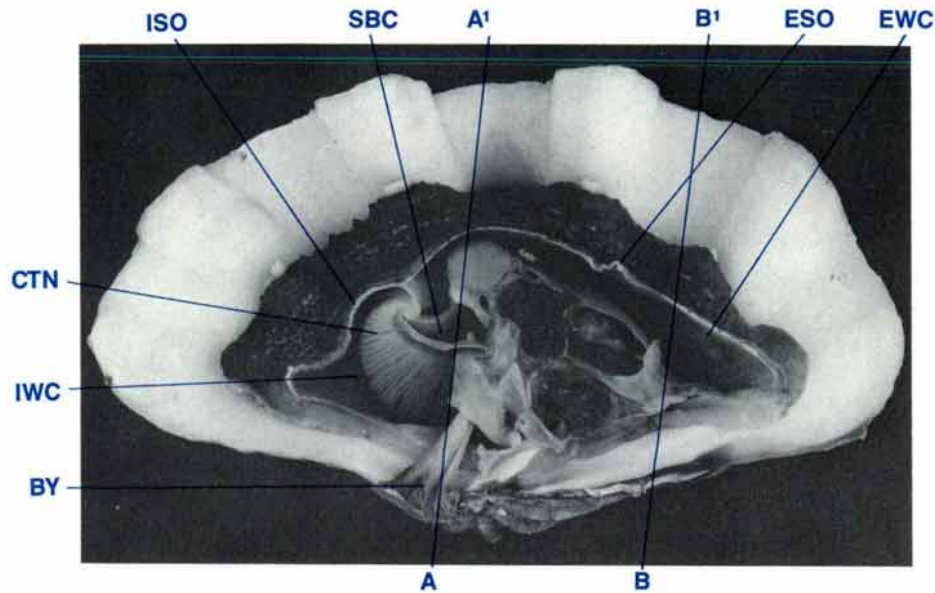


Figure 19 A mid-longitudinal section of a clam showing the water chambers (shell length 35 cm, $MgCl_2$ sedated, formalin fixed).

BY byssus, **CTN** ctenidia, **ESO** excurrent siphonal orifice, **EWC** excurrent water chamber, **ISO** incurrent siphonal orifice, **IWC** incurrent water chamber, **SBC** suprabranchial water compartment.

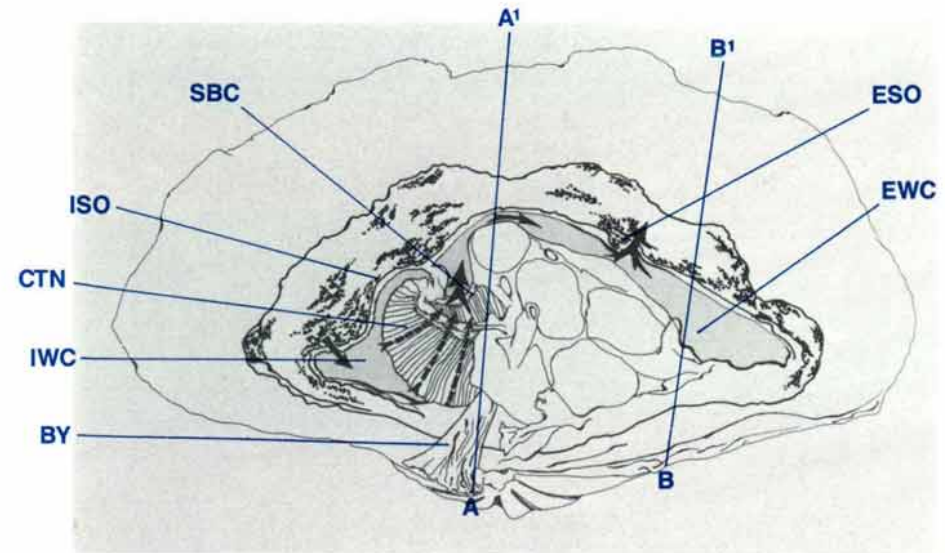


Figure 20 Diagrammatic view of Figure 19 to show water chambers; arrows indicate water flow.

BY byssus, **CTN** ctenidia, **ESO** excurrent siphonal orifice, **EWC** excurrent water chamber, **ISO** incurrent siphonal orifice, **IWC** incurrent water chamber, **SBC** suprabranchial water compartment.

An external view of the lateral mantle shows other features. These include the ends of the adductor and posterior byssal/pedal retractor muscles (Fig. 16), the anterior byssal/pedal retractor muscle (Fig. 17), the visceral-pallial attachment lines (Fig. 17) and brown or orange-brown areas in the antero-ventral aspect of the lateral mantle on each side of the clam, the mantle pericardial gland (Fig. 16).

Water Chambers — Anatomy

The water chambers consist of two main compartments, the incurrent water chamber and the excurrent water chamber (Figs 19, 20).

Water enters the incurrent water chamber through the elongated incurrent siphonal orifice at the posterior end of the siphonal mantle. The boundaries of this chamber include the inner surface of the lateral mantle, the ctenidia, labial palps, oral groove, the lower portion of the byssal organ, the byssus and the foot (Figs 19, 21).

Water passes between the ctenidial filaments into the supra-branchial water compartment of the excurrent water chamber.

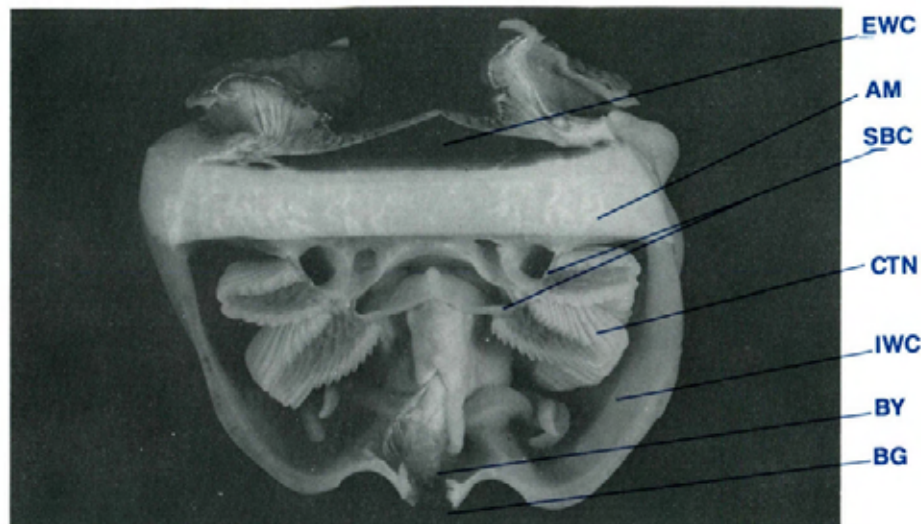


Figure 21 Rear view of a transverse section (A-A' of Figure 19) of clam to show water chambers (shell length 20 cm, MgCl₂ sedated, formalin fixed).

AM adductor muscle, BG byssal gape, BY byssus, CTN ctenidia, EWC excurrent water chamber, IWC incurrent water chamber, SBC suprabranchial water compartment.

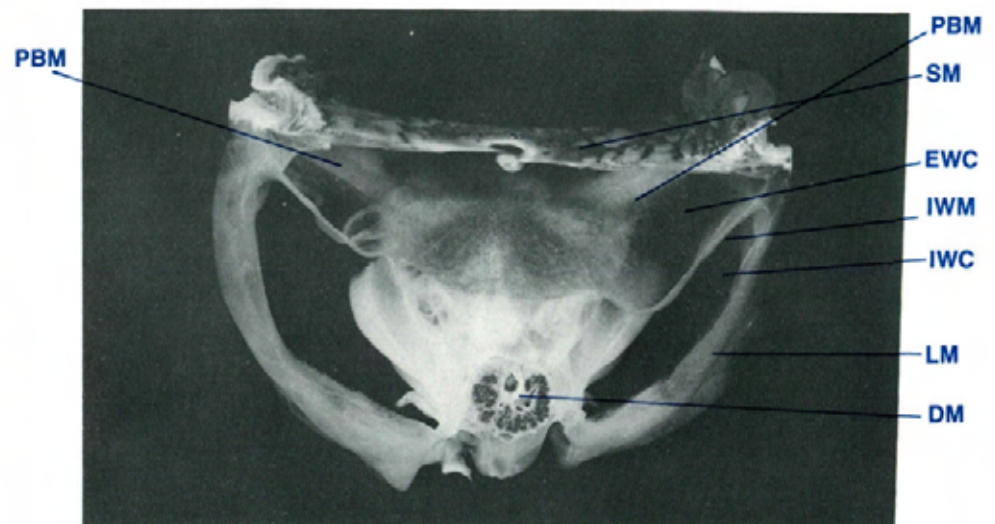


Figure 22 Anterior view of a transverse section (B-B' of Figure 19) to show the inter-water-chamber membrane which separates the incurrent from the excurrent water chambers (TS, shell length 20 cm, MgCl₂ sedated, formalin fixed).

DM digestive mass, EWC excurrent water chamber, IWC incurrent water chamber, IWM inter-water-chamber membrane, LM lateral mantle, PBM posterior byssal/pedal retractor muscles, SM siphonal mantle.

This compartment is bounded by the dorsal surface of the ctenidia, the surfaces of the ctenidial suspensory ligaments including the internal surface of the siphonal partition (refer anatomy of ctenidia), and the kidneys, digestive, reproductive and byssal organs and the retractor and adductor muscles. From the suprabranchial water compartment, the water flows posteriorly and then dorsally around the posterior side of the adductor muscle (Figs 19, 20, 40), and then anteriorly to enter the main excurrent water chamber (Figs 19, 20).

The excurrent water chamber is separated from the incurrent water chamber by a thin translucent membrane, the inter-water-chamber membrane (Fig. 22). This membrane stretches between the junction of the lateral and siphonal mantles and the anterior

edge of the posterior byssal/pedal retractor muscles and the dorsolateral aspect of the kidneys. It is also attached to the dorsolateral aspect of the pericardium along the junction between the pigmented and non-pigmented areas, and the anterodorsal aspect of the digestive mass and reproductive organ. The excurrent water chamber is bounded ventrally by the digestive mass and reproductive organ, the pericardium, anal papilla, adductor muscle and the inter-water-chamber membrane. It is bounded laterally and dorsally by the ventral surface of the siphonal mantle. Water leaves the clam through the nozzle-shaped excurrent siphonal orifice situated in the mid-anterior of the siphonal mantle (Figs 15, 19).

MANTLE COMPARATIVE ANATOMY

Species	Colour/texture	Guard tentacles, incurrent orifice	Hyaline organs or 'eyes'
<i>T. gigas</i>	brown; blue-green circles around hyaline organs along lateral edge	absent	present
<i>T. derasa</i>	elongate patterns; sometimes brilliant blue, brown, green	medium length, narrow, branched	present
<i>T. squamosa</i>	mottled in mixes of green, blue, brown, orange & yellow	short, blunt, branched	present
<i>T. maxima</i>	often bright colours, variable in colour and pattern	short, blunt, branched	present
<i>T. crocea</i>	usually bright colours: green, blue, purple, brown & orange	short, blunt, branched	present
<i>T. tevoroa</i>	brown, dull grey, green, rugose with warty protruberances	long, broad, unbranched	absent
<i>H. hippopus</i>	yellow-brown, dull, with green or grey lines; translucent	absent	absent
<i>H. porcellanus</i>	yellow-brown, dull with green or grey lines; translucent	medium length and width, branched	absent

Species	Mantle overlaps shell valves	Iridophores	Postion of periostracal groove in inner surface of outer mantle fold
<i>T. gigas</i>	yes	present	lower third
<i>T. derasa</i>	yes	present	lower third
<i>T. squamosa</i>	yes	present	lower third
<i>T. maxima</i>	yes	present	middle third
<i>T. crocea</i>	yes	present	middle third
<i>T. tevoroa</i>	no	present (few only)	lower third
<i>H. hippopus</i>	no	present	lower third
<i>H. porcellanus</i>	no	present	lower third

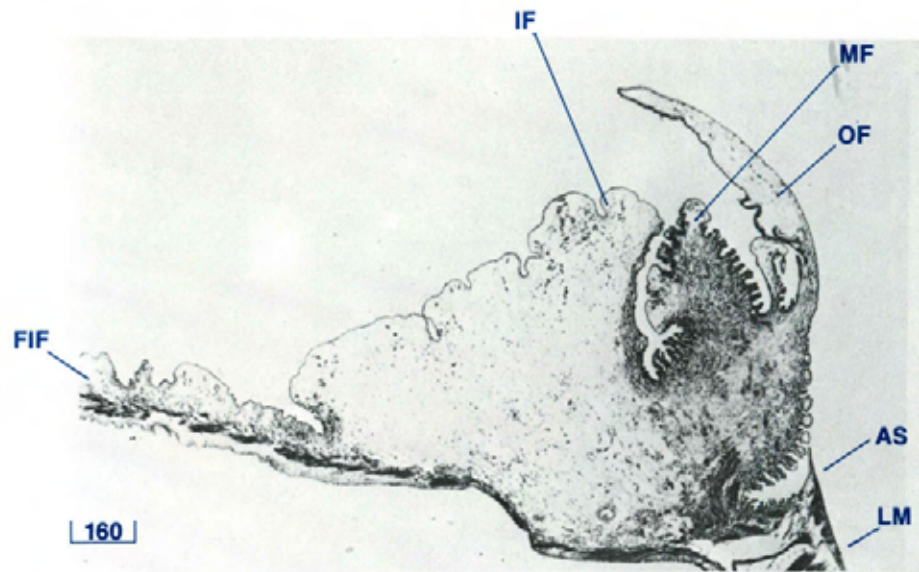


Figure 23 Siphonal mantle (TS, H & E stain, shell length 4 cm). AS attachment to pallial line on inside of shell valves, FIF fused inner fold, IF inner fold, LM lateral mantle, MF middle fold, OF outer fold.

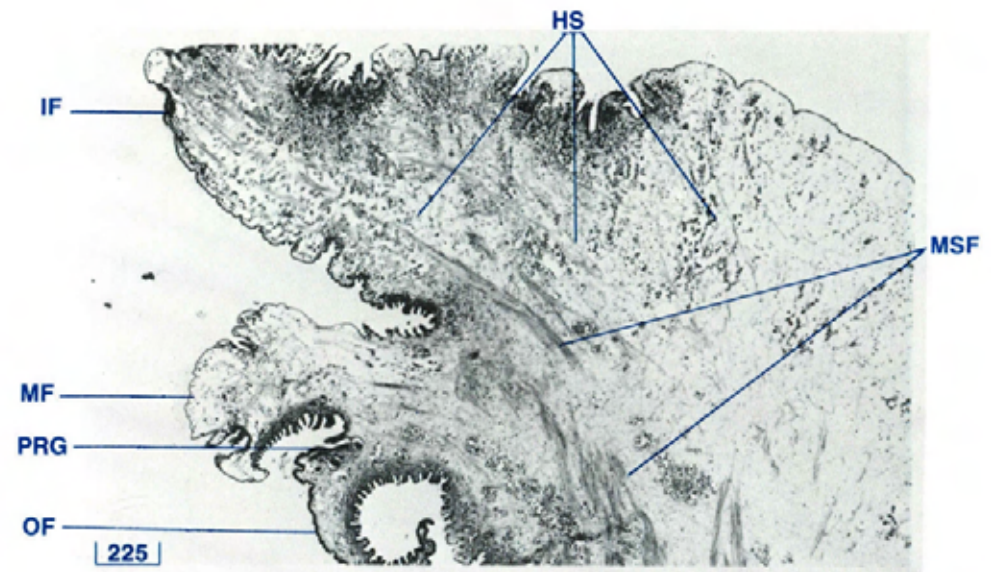


Figure 24 The folds of the siphonal mantle (TS, H & E stain, shell length 10 cm). HS haemolymph sinuses, IF inner fold, MF middle fold, MSF muscle fibres, OF outer fold, PRG periostracal gland.

Mantle — Histology

Siphonal Mantle

The mantle is composed mainly of a muscular and connective tissue network which encloses numerous haemolymph sinuses (Fig. 24). The muscle bundles are the retractor muscles of the siphonal mantle and its lobes. Zooxanthellae are present within a delicate tubular network which is arranged approximately perpendicular to the mantle's exposed outer surface. The zooxanthellae are spherical bodies, 7 to 8 μm in diameter. Each cell contains a dark granular nucleus, a round, pink pyrenoid surrounded by a clear zone, and a yellow-orange accumulation body. Numerous iridophores (Fig. 26) are adjacent to the tubular structures containing the zooxanthellae in the upper regions of

the mantle. The iridophores are globular-shaped cells with dark oval or flattened, often peripheral, nuclei and a strongly eosinophilic cytoplasm which may have an appearance of refractile parallel rods. Some granulocytes may also be seen scattered throughout. These cells have a round, dark nucleus which is often obscured by numerous, refractile, eosinophilic, globular bodies whose size and number can be variable. Both zooxanthellae and iridophores are present in the inner fold, a few iridophores only are present in the middle fold, while both these cells are usually absent from the outer fold of juvenile and adult clams. They may be present in all three folds of young clams, e.g. 3 cm shell length (Fig. 23). Columnar epithelium covers the mantle (Fig. 26). The inner fold also contains hyaline organs or 'eyes' (Fig. 135).

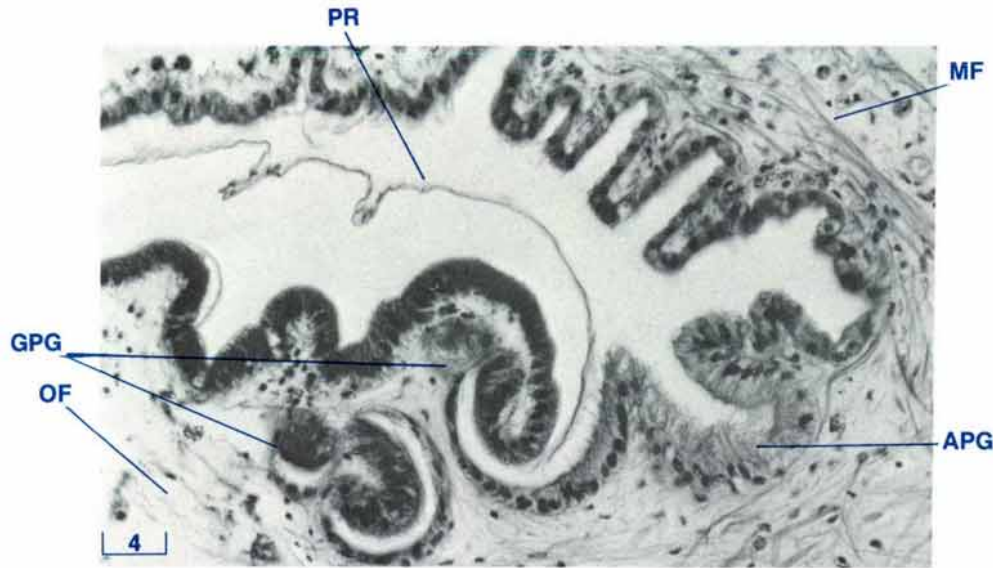


Figure 25 Periostracal gland of the siphonal mantle (TS, H & E stain, shell length 20 cm).

APG accessory periostracal gland, GPG glomerular periostracal gland, MF middle fold, OF outer fold, PR periostracum.

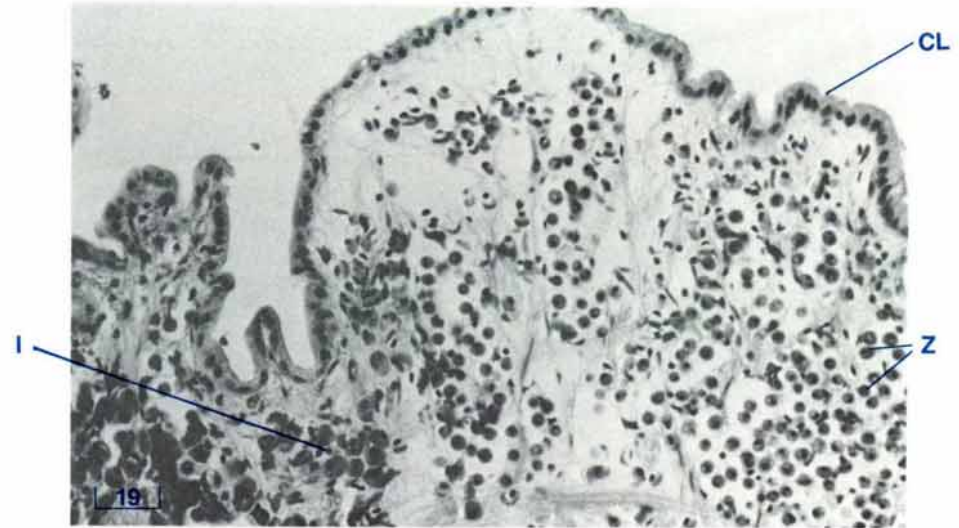


Figure 26 Inner fold of the siphonal mantle (TS, H & E stain, shell length 10 cm).

CL columnar epithelium, I iridophores, Z zooxanthellae.

The appearance and arrangement of the columnar epithelium varies with the location on the siphonal mantle. On the outer surface of the outer fold, the epithelium is highly folded (Fig. 24) and the columnar cells are loosely arranged except near the tip of this fold where they are tightly arranged. On the inner surface of this fold, the epithelium is moderately folded near the tip only. This epithelium is tightly arranged.

On the outer surface of the middle fold, the epithelium is highly folded (Fig. 24). On the inner surface of this fold, there is light folding only. The columnar cells on both surfaces are loosely arranged.

On the outer surface of the inner fold, the epithelium is highly folded, and the columnar cells are arranged moderately tightly.

On the inner or dorsal surface of the inner fold, there is a moderately heavy folding of the epithelial layer near the tip only. The columnar cells are loosely arranged (Fig. 26).

Cells containing type 2 mucins (see page 132) are present in large numbers amongst the epithelium lining the outer surfaces of the three folds. There are none on the inner surface of the outer fold and low concentrations on the inner surfaces of the middle and inner folds.

Subepithelial glands containing type 2 and type 3 mucins (see page 132) discharge through the epithelial lining and are common along the outer surfaces of the middle and inner folds. However they are less common along the inner surfaces of these folds. None of these glands is present along the inner surface of

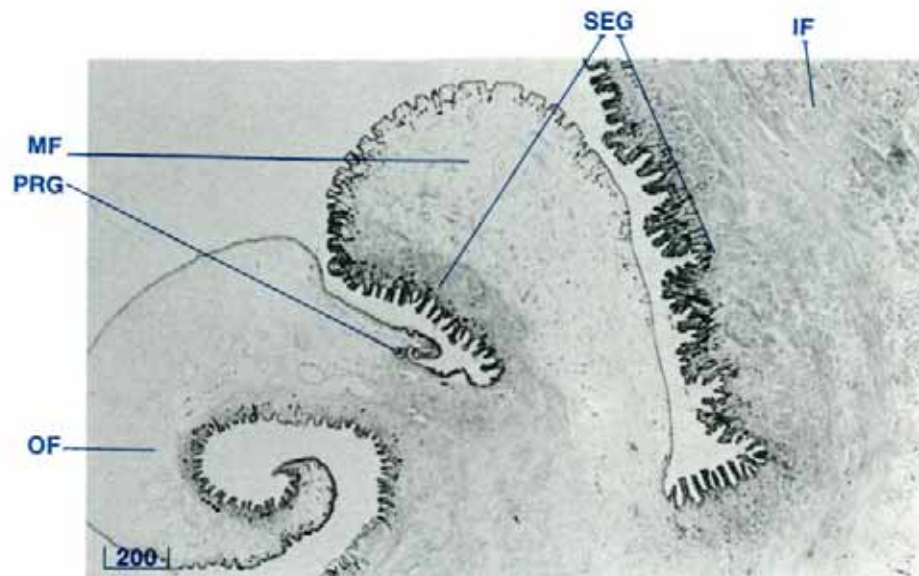


Figure 27 Type 2 mucin subepithelial glands of the three folds of the siphonal mantle (TS, PAS/diastase stain, shell length 10 cm). IF inner fold, MF middle fold, OF outer fold, PRG periostracal gland, SEG subepithelial glands.

the outer mantle fold. Only subepithelial glands containing type 2 mucins (see page 132) are present along the outer surface of the outer fold (Fig. 27).

The periostracal groove, along the base of the inner surface of the outer mantle fold (Fig. 24), contains the two periostracal glands (Fig. 25) which produce the periostracum. The glomerular periostracal gland has a compound structure of glandular glomeruli with cuboidal cells while the accessory periostracal gland, ventral or medial to the periostracal groove, is composed of a group of tall columnar cells. The inner surface of the outer fold of the siphonal mantle is covered by a sheet of periostracum.

The circumpallial artery, the circumpallial vein, the pallial nerves and the zooxanthellal tube (refer anatomy of the zooxan-



Figure 28 Lateral mantle (TS, H & E stain, shell length 20 cm). CB cuboidal epithelium (adjacent to shell valve), CCB ciliated cuboidal epithelium (adjacent to water chamber), CT connective tissue, HS haemolymph sinuses, MPC macrophage centre, MPG mantle pericardial gland, MSF muscle fibres.

thellal tube system) are seen deep in the siphonal mantle close to the attachment of the siphonal mantle muscles to the shell valves (Fig. 155). Smaller branches of these structures are seen throughout the mantle.

Lateral Mantle

The lateral mantle consists of large collagenous fibrous sheets on either side of a network of collagenous connective tissue which encloses numerous haemolymph sinuses. The fibrous sheet is thicker on the side adjacent to the water chambers (Figs 28, 29). Bundles of muscle fibres traverse the mantle from side to side. Within the connective tissue there are a variable number of focal macrophage centres. Eosinophilic granulocytes are scattered throughout. In the anterior of the lateral mantle, glan-

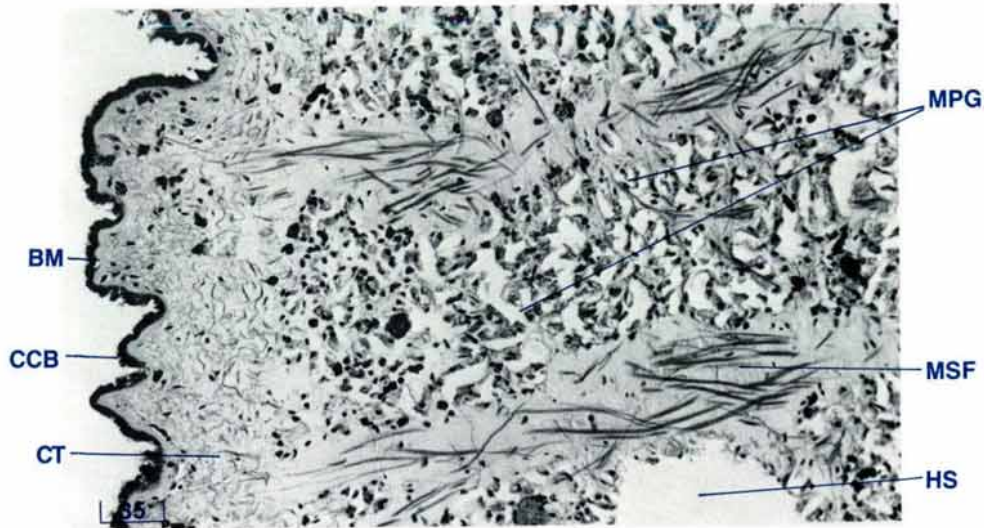


Figure 29 Lateral mantle adjacent to water chambers (TS, H & E stain, shell length 20 cm).

BM basement membrane, **CCB** ciliated cuboidal epithelium, **CT** connective tissue, **HS** haemolymph sinuses, **MPG** mantle pericardial gland, **MSF** muscle fibres.

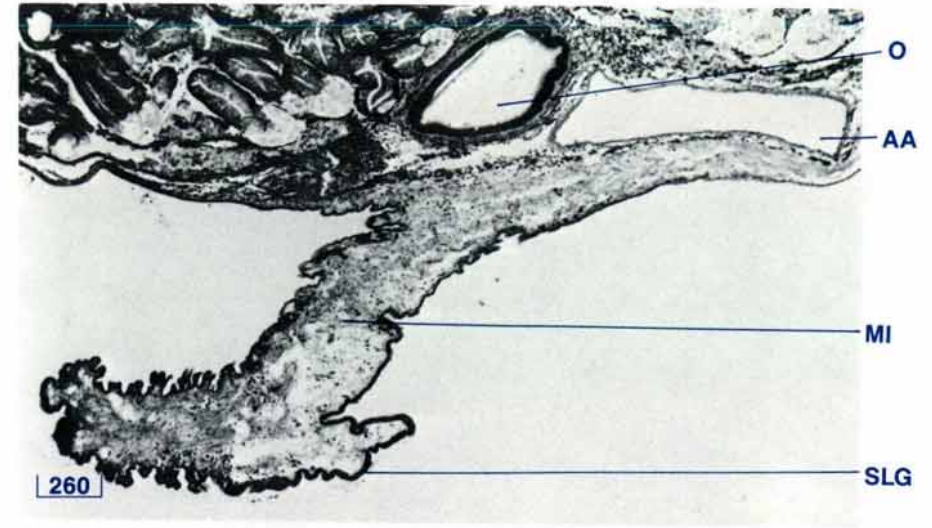


Figure 30 Supraligamental or hinge gland (TS, H & E stain, shell length 4 cm).

AA anterior aorta, **MI** mantle isthmus, **O** oesophagus, **SLG** supraligamental (hinge) gland.

dular tissue of the mantle pericardial gland is present (Fig. 29). Arteries and nerves are also present.

The lateral mantle is lined with large cuboidal epithelial cells on the side adjacent to the shell valve. On the side adjacent to the water chambers, the lateral mantle is lined with ciliated cuboidal epithelium which rests on a thick basal membrane positive for type 2 mucins (see page 132). Glandular cells containing type 2 mucins (see page 132) are present in the epithelial lining adjacent to the water cavity. Subepithelial gland cells containing type 3 mucins (see page 132) are also along this surface and discharge to the surface through the epithelium.

The lateral mantle from each side of the clam meets over the ligament or hinge to form the mantle isthmus and the

supraligamental (hinge) gland (Fig. 30). This latter gland has tall columnar cells with dark staining cytoplasm.

Byssal Gape Edge of Lateral Mantle

The three folds of the byssal gape edge have a cellular structure similar to the three folds of the siphonal mantle (Fig. 31). However, all three folds are usually devoid of zooxanthellae and iridophores, except in very young clams, and there is less muscle tissue. The periostracal gland, which is present on the inside surface of the outer fold, is similar in appearance to that gland present in the siphonal mantle.

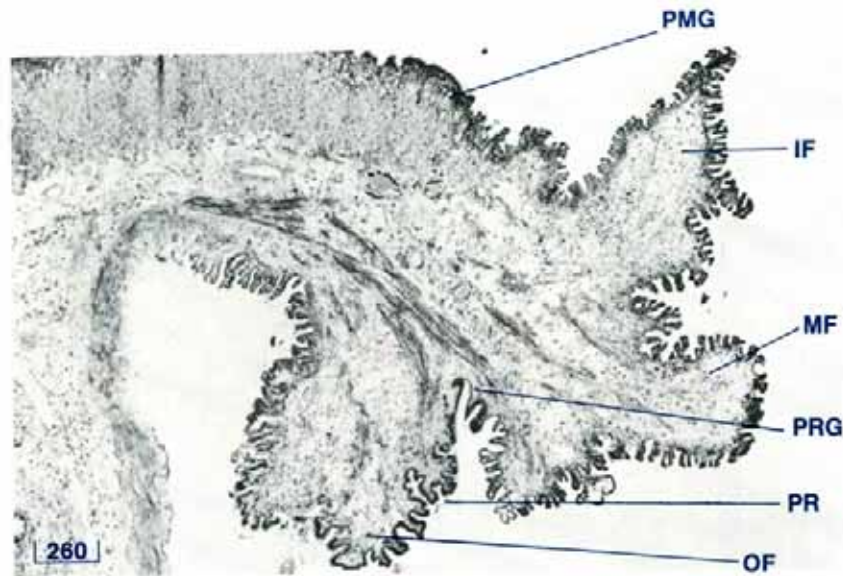


Figure 31 The three folds of the lateral mantle adjacent to the byssal gape (TS, H & E stain, shell length 3 cm).

IF inner fold, MF middle fold, OF outer fold, PMG pallial mucous gland, PR periostracum, PRG periostracal gland.

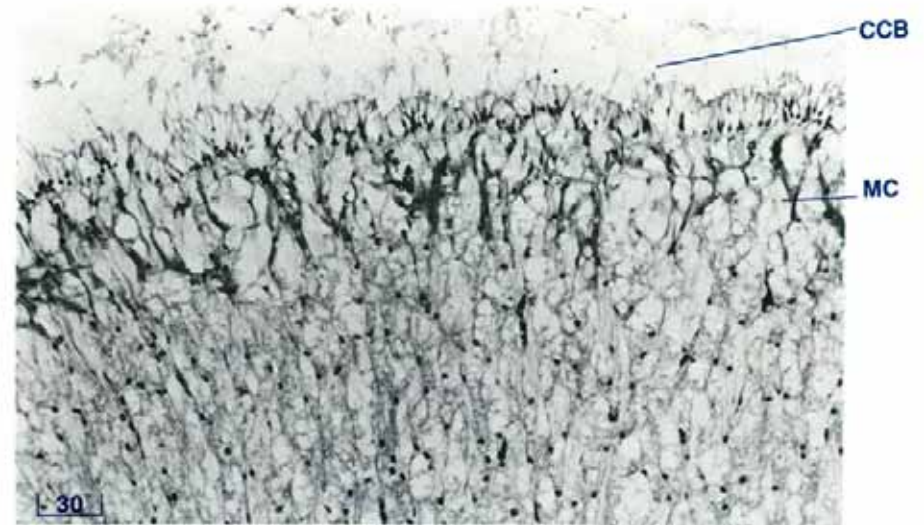


Figure 32 Pallial mucous gland (TS, H & E stain, shell length 3 cm).

CCB ciliated cuboidal epithelium, MC mucous cells.

Glandular cells containing type 2 mucins (see page 132) are present in the epithelial lining of the inner and outer surfaces of the middle fold and of the outer surface of the inner fold. Glandular cells containing type 3 mucins (see page 132) are present on the inner and outer surface of the inner and middle folds. Subepithelial cells containing type 2 mucins (see page 132) are present in the outer and inner surfaces of the outer fold.

Inside the byssal gape edge, there is the pallial mucous gland (Fig. 31). It is composed of large clear, vesicular, cells which contain type 3 mucins (see page 132). The gland is covered with a ciliated cuboidal epithelium (Fig. 32).



THE CTENIDIA AND LABIAL PALPS

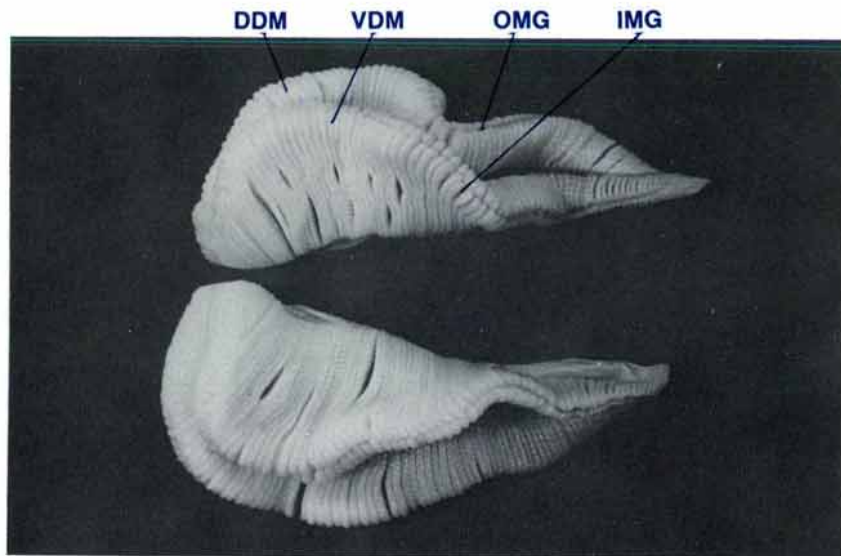


Figure 33 Ventral view of the ctenidia (shell length 35 cm, $MgCl_2$ sedated, formalin fixed).
DDM dorsal demibranch, **IMG** inner marginal food groove, **OMG** outer marginal food groove, **VDM** ventral demibranch.

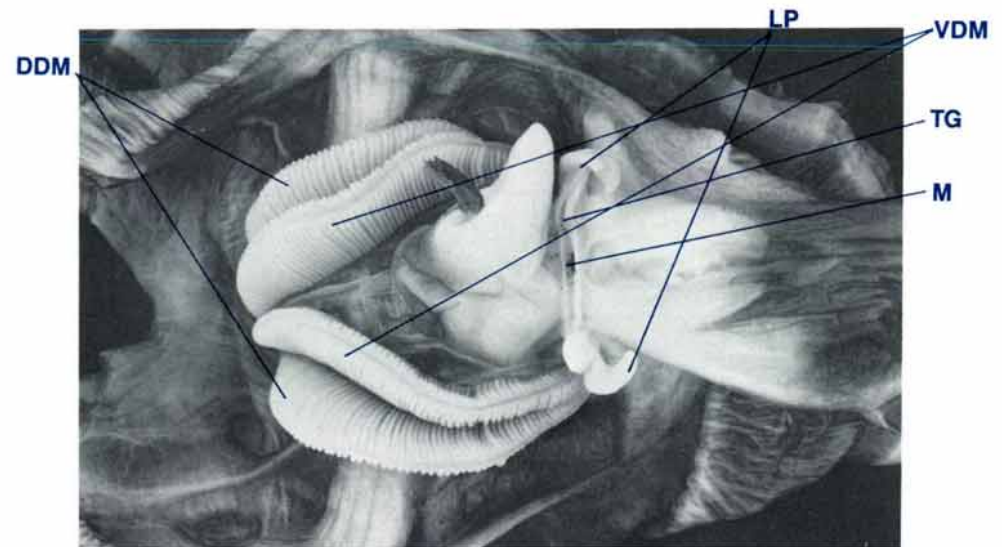


Figure 34 Ventral view of clam showing ctenidia and labial palps; shell valves and lateral mantle removed (shell length 20 cm, $MgCl_2$ sedated, formalin fixed).
DDM dorsal demibranch, **LP** labial palps, **M** mouth, **TG** transverse oral groove, **VDM** ventral demibranch.

Ctenidia — Anatomy

The ctenidia (or gills) are white in colour and consist of two pairs of demibranchs (Fig. 33) one pair on each side of the byssal, digestive mass and reproductive organ (Fig. 34). Each demibranch is a flat, white, elongated organ with a narrow anterior and a broad posterior end. On each side of the clam, there is a dorsal demibranch and a ventral demibranch (Fig. 34).

Each demibranch is composed of a descending and an ascending lamella, suspended on each side of the body from a ctenidial axis (Fig. 35). One descending lamella runs from the ctenidial axis to the outer marginal food groove of the dorsal demibranch while another descending lamella runs from the

same ctenidial axis to the inner marginal food groove of the ventral demibranch. The ascending lamella of the dorsal demibranch runs from the outer marginal food groove and attaches to the visceral mass by a cuticular union in the outer ctenidial suspensory ligament (Fig. 51). The ascending lamella of the ventral demibranch runs from the inner marginal food groove and attaches to the visceral mass by a tissue union in the inner ctenidial suspensory ligament.

At the free or ventral border of each demibranch, there is a well defined marginal food groove (Figs 36, 37). Between the two demibranchs there is another well defined food groove, the central food groove which follows the ctenidial axis (Figs 35, 37). The surface and edge of each lamella are interrupted by small transverse ridges (Fig. 36).

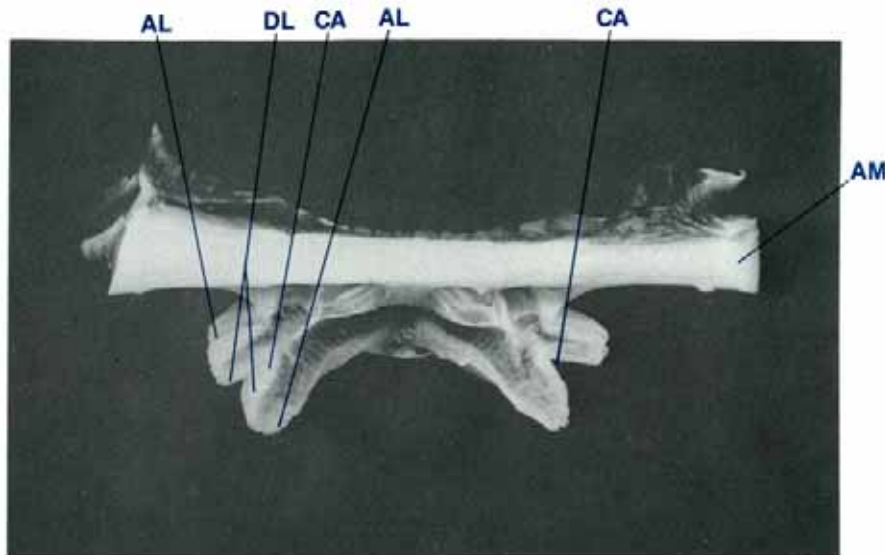


Figure 35 Transverse section of clam showing ctenidia (shell length 20 cm, MgCl₂ sedated, formalin fixed).

AM adductor muscle, **AL** ascending lamella, **CA** ctenidial axis, **DL** descending lamella.

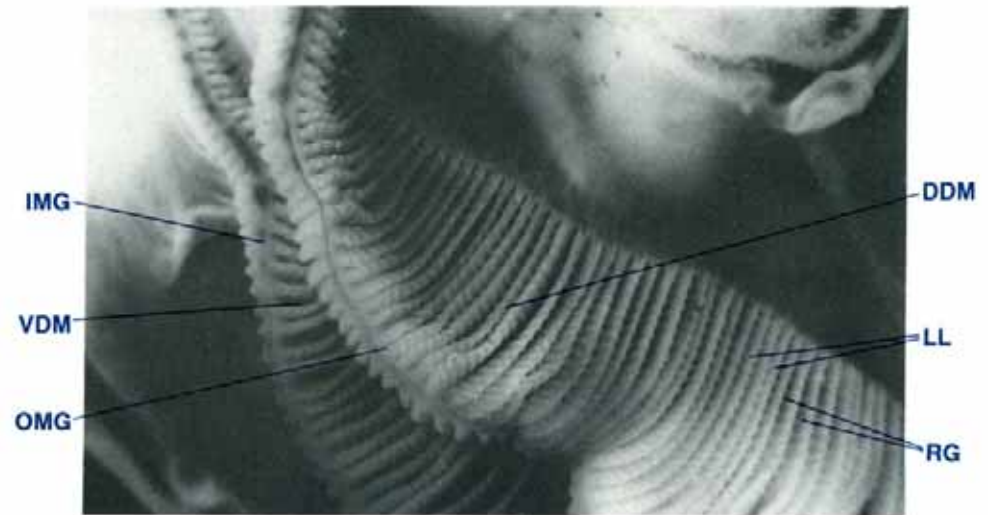


Figure 36 Ventral view of two demibranchs of the ctenidia of a clam (shell length 10 cm).

DDM dorsal demibranch, **IMG** inner marginal food groove, **LL** lamella, **OMG** outer marginal food groove, **RG** ridges, **VDM** ventral demibranch.

The ctenidia are attached to the body of the clam, to one another, and to the siphonal partition which is attached to the ventral surface of the posterior siphonal mantle (Figs 37, 38, 39, 40). The siphonal partition is that portion of the outer ctenidial suspensory ligament posterior to the adductor muscle (Fig. 38). Water from the incurrent water chamber must pass between the ctenidial filaments and through the water channels of the ctenidia before it can reach the suprabranchial compartment of the excurrent water chamber. Anteriorly, the narrow ends of the ctenidia are attached to the sides of the digestive mass and reproductive organ, dorsal to the labial palps (Fig. 37). The two demibranchs on each side of the clam are suspended by three ctenidial suspensory ligaments including the outer, the middle and the inner ctenidial suspensory ligaments (Fig. 38). The outer and middle suspensory ligaments support the dorsal

demibranch while the middle and inner suspensory ligaments support the ventral demibranch. The outer branchial suspensory ligament is attached to the lateral surface of the digestive mass and reproductive organ, the ventral surface of the kidney lobes and adductor muscle and the ventral surface of the siphonal mantle via the siphonal partition which is anterior to the incurrent orifice (Figs 38, 53, 59, 106). The middle ctenidial suspensory ligament is attached to the lateral surface of the digestive mass and reproductive organ, the ventro-medial surface of the kidney and the ventro-medial surface of the adductor muscle (Figs 38, 53, 59, 106). The inner ctenidial suspensory ligament is attached to the lateral surface of the digestive mass and reproductive organ, and to the lateral and posterior sides of the dorsal aspect of the byssal organ (Figs 38, 58, 59, 106, 137).

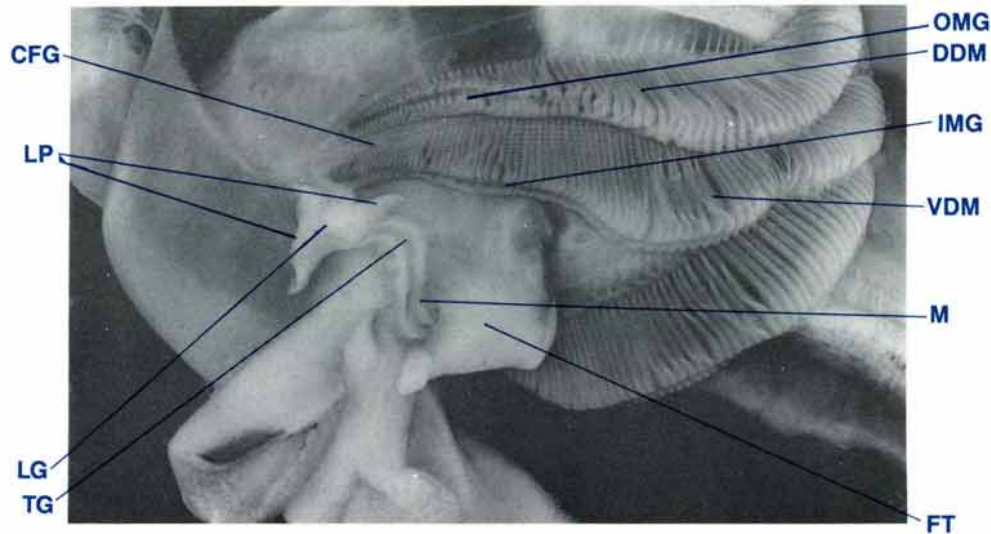


Figure 37 Lateroventral view of a clam to show the ctenidial axis, food grooves and oral groove, lateral mantle reflected (shell length 33 cm, $MgCl_2$ sedated).

CFG central food groove, DDM dorsal demibranch, FT foot, IMG inner marginal food groove, LG lateral oral groove, LP labial palps, M mouth, OMG outer marginal food groove, TG transverse oral groove, VDM ventral demibranch.

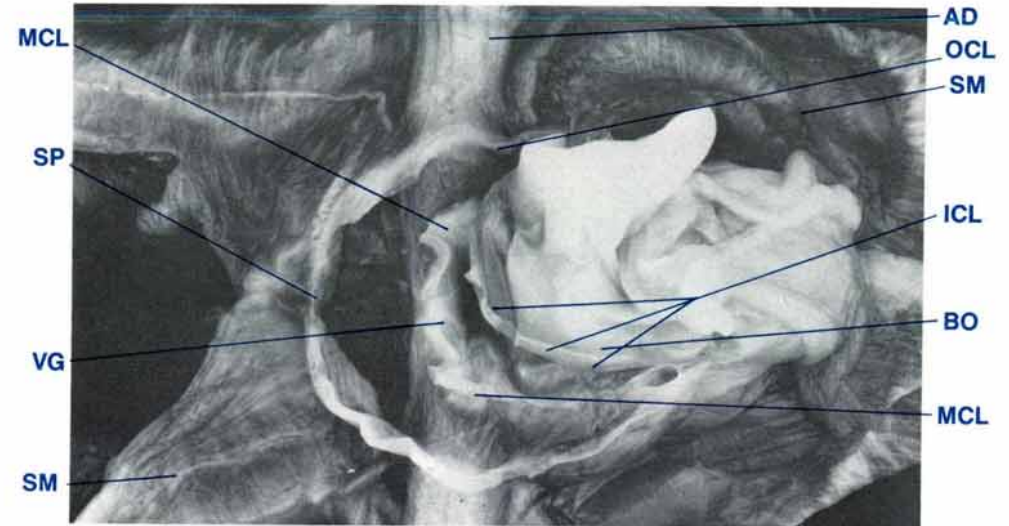


Figure 38 Ventral view of clam showing the attachments of the ctenidial suspensory ligaments, ctenidia removed (shell length 20 cm, $MgCl_2$ sedated, formalin fixed).

AD adductor muscle, BO byssal organ, ICL inner ctenidial suspensory ligament (cut edge), MCL middle ctenidial suspensory ligament (cut edge), OCL outer ctenidial suspensory ligament (cut edge), SM siphonal mantle, SP siphonal partition (cut edge), VG visceral ganglion.

The ctenidia are bounded dorsally by the suprabranchial water compartment of the excurrent water chamber, laterally and ventrally by the incurrent water chamber and medially by the foot and by the byssal, digestive mass and reproductive organ (Figs 34, 37, 38).

Labial Palps — Anatomy

At the anterior end of the ctenidia, on each side of the digestive mass and reproductive organ, are the paired labial palps (Figs 34, 37). They are lateral to the ends of the transverse oral groove. The palps are large, white, flat, elongated, triangular-shaped structures. One palp is situated on each side of the lateral segment of the oral groove. On the inner surfaces of the palps, adjacent to the oral groove, there are transverse ridges. The outer surfaces are smooth.

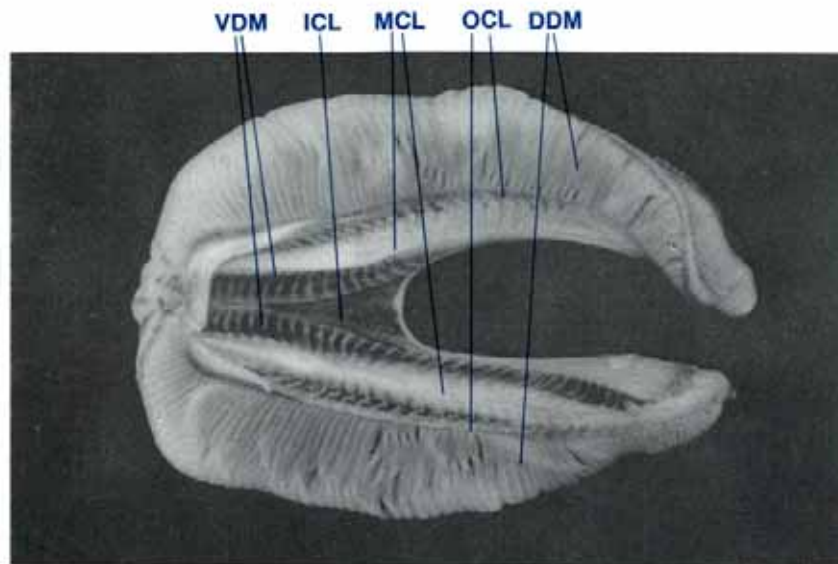


Figure 39 Dorsal view of ctenidia (shell length 20 cm, MgCl₂ sedated). DDM dorsal demibranch, ICL inner ctenidial suspensory ligament, MCL middle ctenidial suspensory ligament, OCL outer ctenidial suspensory ligament, VDM ventral demibranch.

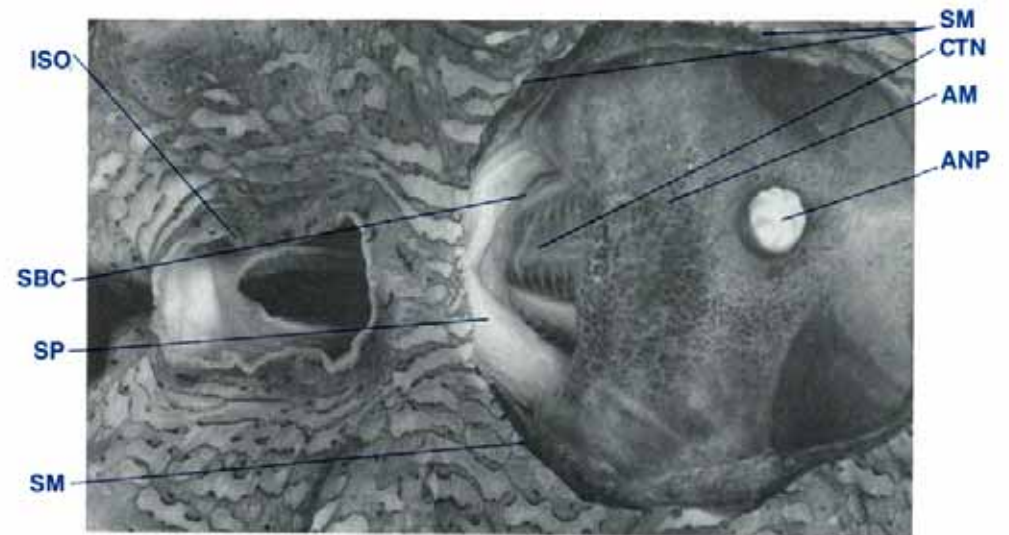


Figure 40 Dorsal view of clam showing the posterior section of ctenidia and the exit from the suprabranchial water compartment with section of siphonal mantle removed (shell length 20 cm, MgCl₂ sedated).

ANP anal papilla, AM adductor muscle, CTN ctenidia, ISO incurrent siphonal orifice, SBC suprabranchial water compartment, SM siphonal mantle (cut edge), SP siphonal partition.

CTENIDIA — COMPARATIVE ANATOMY

Species	<i>T. gigas</i>	<i>T. derasa</i>	<i>T. squamosa</i>	<i>T. maxima</i>	<i>T. crocea</i>	<i>T. tevoroa</i>	<i>H. hippopus</i>	<i>H. porcellanus</i>
Ratio of depth of dorsal demibranch to depth of ventral demibranch	1:1	5:10	6:10	6:10	6:10	8-10:10	6:10	5:10
Dorsal demibranch food groove	present	absent	absent	absent	absent	absent	absent	absent
Ventral demibranch food groove	present	present	present	present	present	present	present	present
Ratio of length of anterior extension of ctenidia beyond the transverse oral groove to full length of ctenidia	1:10	3:10	2:10	1.5:10	0	>2:10	0	0

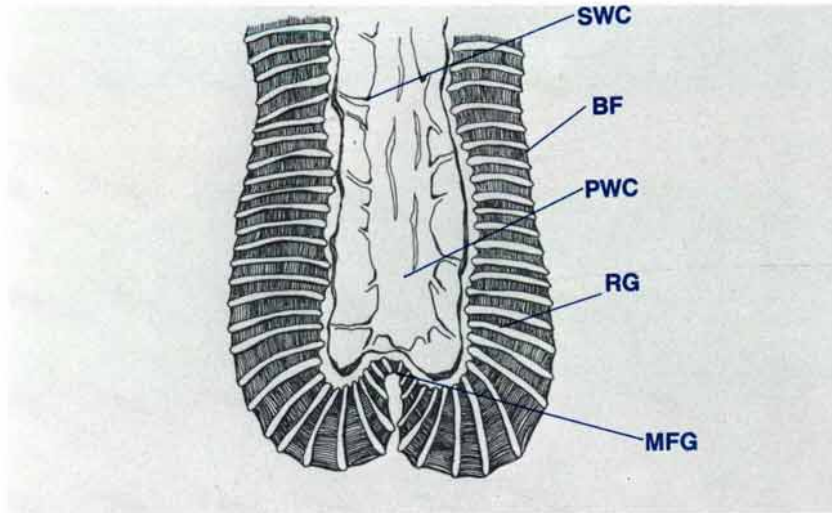


Figure 41 A diagrammatic view of a pair of lamellae which form the demibranchs of the ctenidia.
BF branchial filaments, **MFG** marginal food groove, **PWC** primary water channel, **RG** ridges, **SWC** secondary water channels.

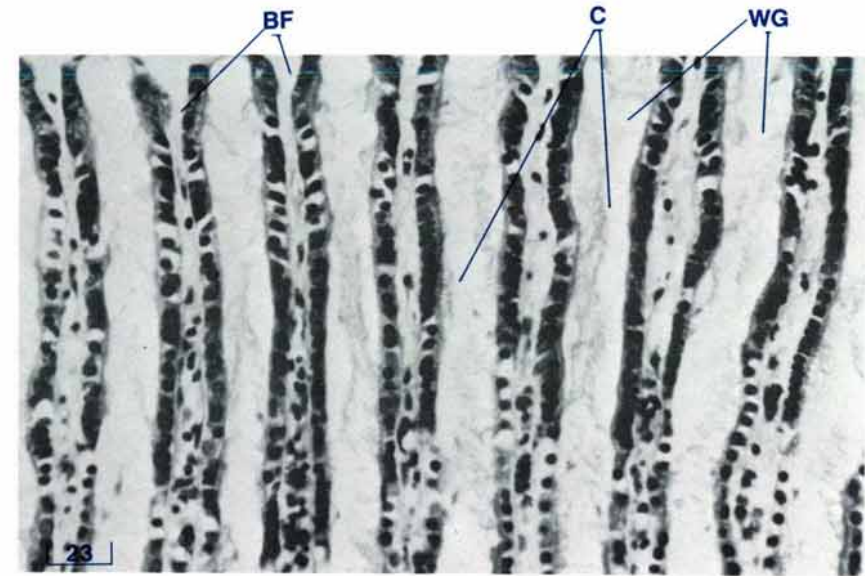


Figure 42 A section at the surface level of a lamella (lamella TS, H & E stain, shell length 20 cm).
BF branchial filaments, **C** cilia, **WG** water grooves.

Ctenidia — Histology

To help our understanding of the cellular structure of a lamella, the basic unit of the ctenidia, transverse sections of a lamella (Figs 4, 41) will be examined commencing with the surface level and then progressing to the deeper subsurface and central levels.

Surface level of a lamella (Fig. 42)

Rows of ciliated, cuboidal cells run parallel to the longitudinal axis of the lamella to form the branchial filaments. These cells are closely packed and have dark, granular, oval-shaped nuclei

with a small amount of cytoplasm. Between adjacent rows of filaments, there are grooves through which water passes into the tertiary water channels. At intervals along the length of the lamella, there are transverse ridges containing type 2 mucin cells (see page 132) (Fig. 46). These ridges interrupt the rows of filaments and grooves at this surface level (Fig. 48).

Subsurface level of a lamella (Fig. 43)

A lattice formation of collagenous connective tissue contains tertiary water channels lined with epithelia with flattened cytoplasm and dark, prominent nuclei. Muscle fibres run throughout the connective tissue. The tertiary water channels empty into the larger secondary water channels.

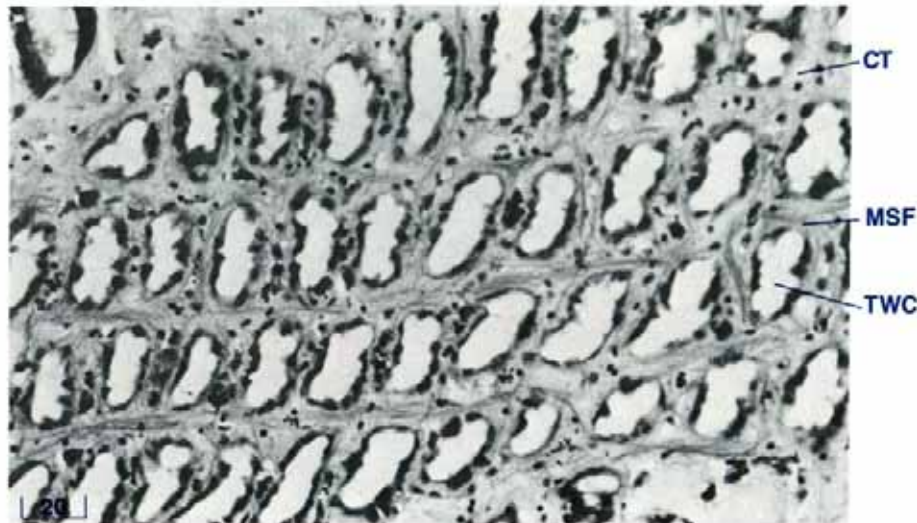


Figure 43 A section at the subsurface level of a lamella (lamella TS, H & E stain, shell length 20 cm).

CT connective tissue, MSF muscle fibers, TWC tertiary water channels.

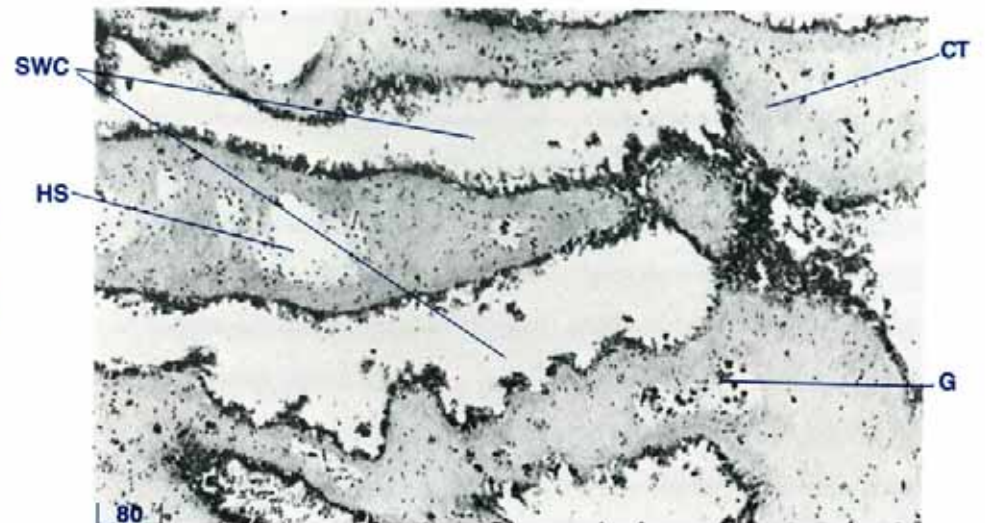


Figure 44 A section at the central level of a lamella (lamella TS, H & E stain, shell length 20 cm).

CT connective tissue, G granulocytes, HS haemolymph sinus, SWC secondary water channels.

Central level of a lamella (Fig. 44)

Large collagenous connective tissue ridges with haemolymph sinuses, and secondary water channels run across each lamella. These water channels enter the larger primary water channels from which water flows dorsally to enter the suprabranchial compartment of the excurrent water chamber. These channels are lined with ciliated cuboidal epithelium. A transverse section of a demibranch (Fig. 5) (= a transverse section of a lamella, Fig. 4) will show portions of all three levels of the lamellae (Fig. 45).

A horizontal section of a demibranch (Fig. 5) gives a different perspective of the structure of this organ (Figs 46, 47). The

ciliated branchial filaments and the primary, secondary and tertiary water channels are visible. In a longitudinal section of a demibranch (Fig. 5), the ridges along each lamella are demonstrated (Fig. 48). Ciliated columnar epithelium line each marginal food groove (Fig. 45) and each central food groove (Fig. 49).

Type 2 mucin gland cells (see page 132) are distributed throughout the epithelial cells lining the water cavities, the ctenidial axis, the marginal food grooves and the lining of the ctenidial suspensory ligaments. Type 3 mucin type gland cells (see page 132) are scattered beneath the epithelial lining of the above structures and have ducts discharging through these epithelial surfaces.

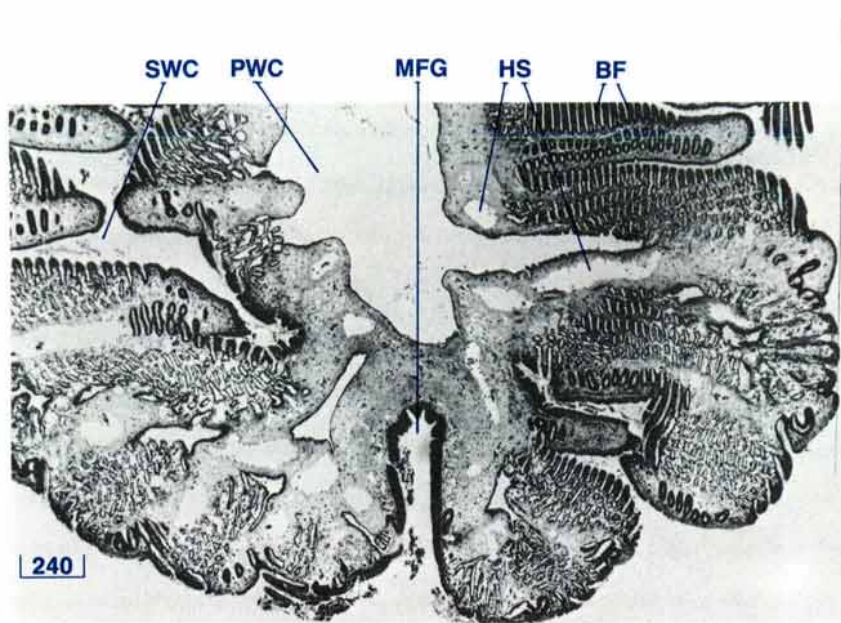


Figure 45 Demibranch section showing different levels of the lamellae (demibranch TS, H & E stain, shell length 20 cm).

BF branchial filaments, HS haemolymph sinus, MFG marginal food groove, PWC primary water channel, SWC secondary water channel.

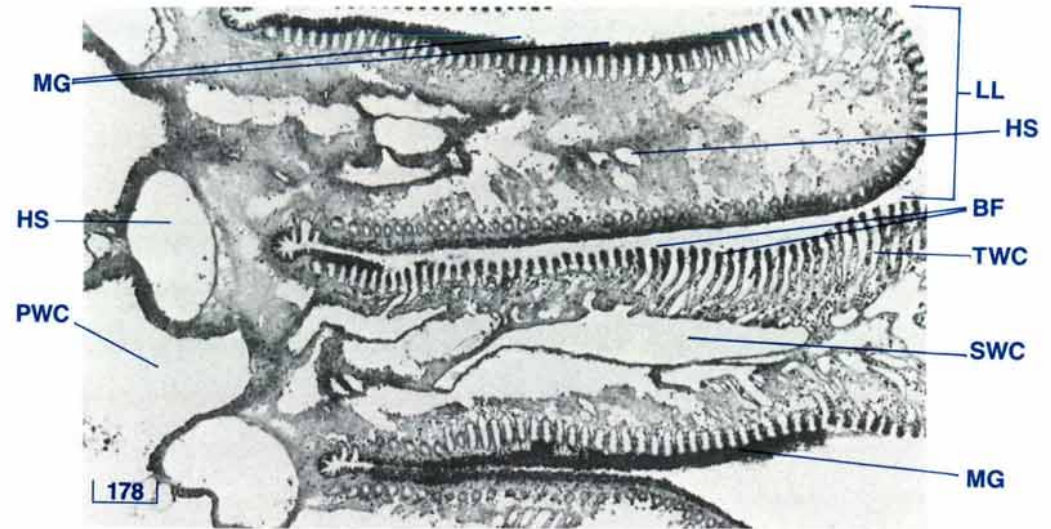


Figure 46 Demibranch showing the mucous glands (demibranch HS, PAS/diastase stain, shell length 20 cm).

BF branchial filaments, HS haemolymph sinus, LL lamella, MG mucous glands (type 2), PWC primary water channel, SWC secondary water channel, TWC tertiary water channel.

Muscle fibres, arteries, haemolymph sinuses, nerves, zooxanthellal tubes, zooxanthellae and granulocytes are found within the connective tissue framework of the ctenidia. Large numbers of granulocytes are common along the epithelial surfaces of the water cavities. These cells may be present both internally and externally to the epithelial cells. The ctenidia contain both longitudinally and transversely orientated muscle fibres. The siphonal partition, a posterior extension of the outer ctenidial suspensory ligament, is a membranous structure which contains large bundles of muscle fibres (Fig. 50). The parallel row of cells which transverse the upper region of the outer ctenidial suspensory ligament forms a zone of cuticular fusion (Fig. 51).

Labial Palps — Histology

The palps (Figs 52, 123) are composed of a collagenous connective tissue network, within which there are scattered bundles of muscle fibres and numerous haemolymph sinuses. On the inner, ridged side, the palps are covered with tall ciliated, columnar epithelium. On the outer side, the palps are covered with cuboidal to low columnar epithelium which is also ciliated. Both epithelial layers rest on a thick type 2 mucin basement membrane (see page 132). Type 3 mucin glands (see page 132) are present below the basement membrane and have ducts discharging between the surface epithelia. Scattered eosinophilic granulocytes are present throughout the palp tissue.

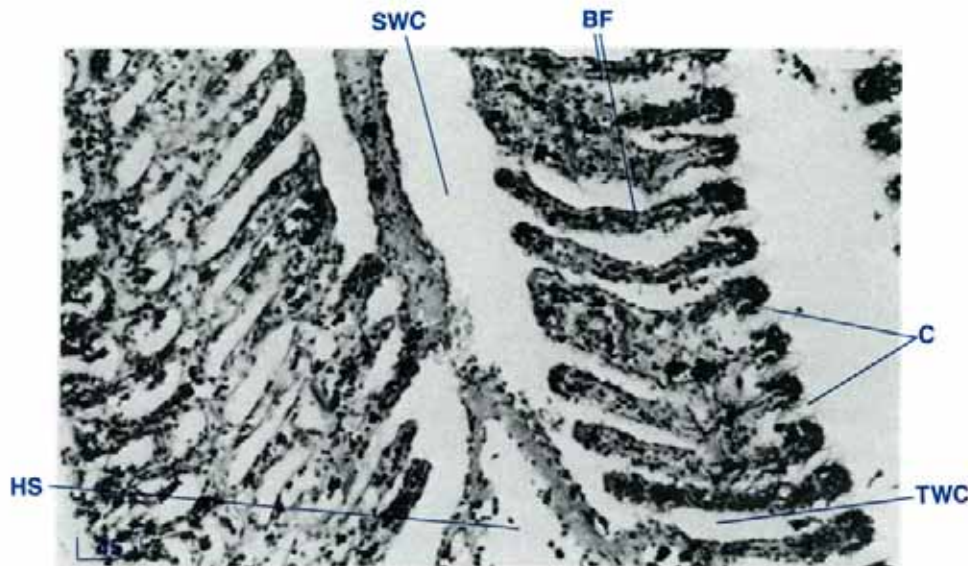


Figure 47 A close up view of the demibranch in Fig. 46 (demibranch HS, H & E stain, shell length 20 cm).

BF branchial filaments, C cilia, HS haemolymph sinus, SWC secondary water channel, TWC tertiary water channel.

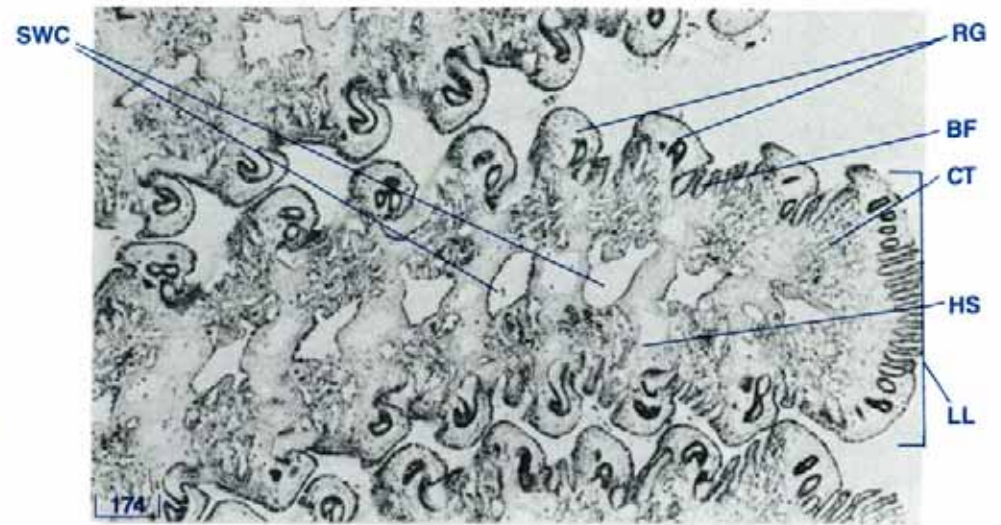


Figure 48 Demibranch (demibranch LS, H & E stain, shell length 20 cm).

BF branchial filaments, CT connective tissue, HS haemolymph sinus, LL lamella, RG ridges, SWC secondary water channel.

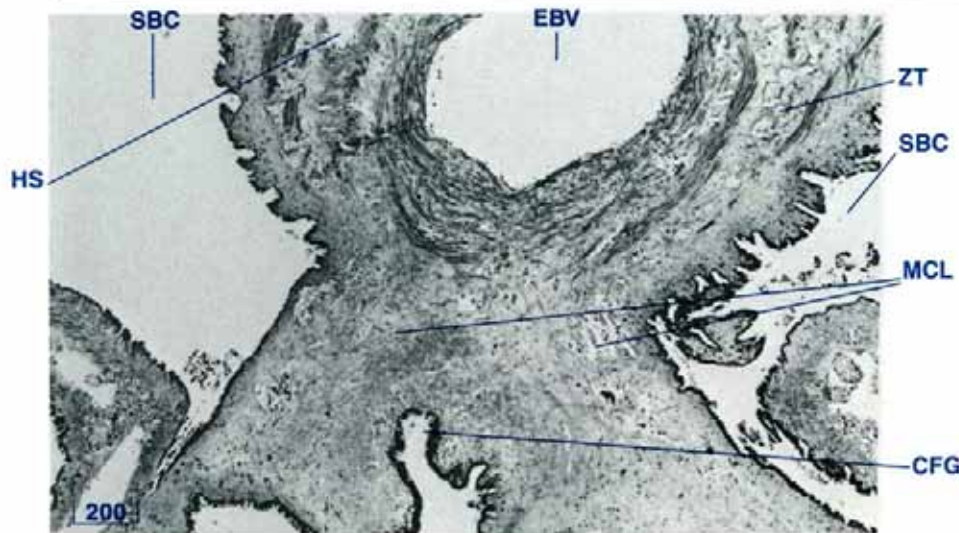


Figure 49 Ctenidial axis in the middle ctenidial suspensory ligament (demibranch TS, H & E stain, shell length 20 cm).

CFG central food groove, EBV efferent branchial vein, HS haemolymph sinus, MCL middle ctenidial suspensory ligament, SBC suprabranchial water compartment, ZT zooxanthellal tube.

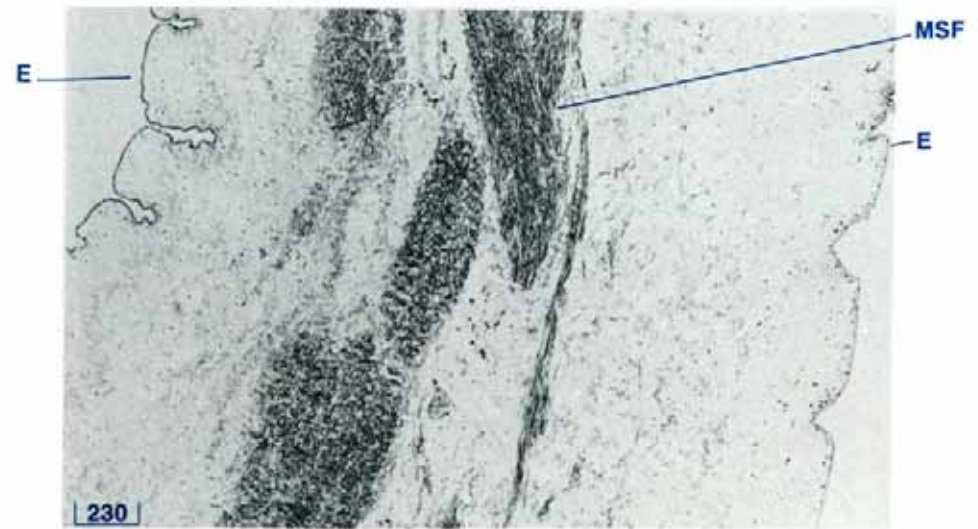


Figure 50 Siphonal partition (siphonal partition TS, H & E stain, shell length 10 cm).

E epithelium, MSF muscle fibres.

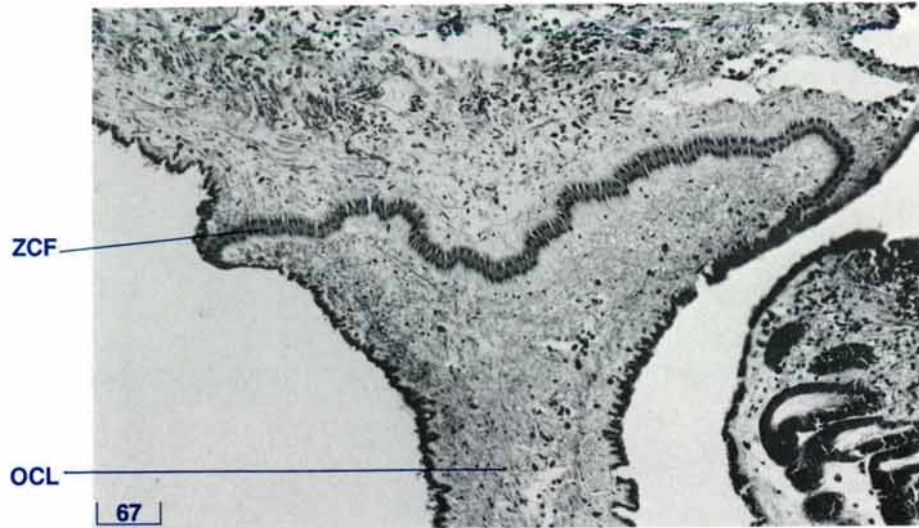


Figure 51 Zone of cuticular fusion in the upper region of the outer ctenidial suspensory ligament (TS, H & E stain, shell length 10 cm). OCL outer ctenidial suspensory ligament, ZCF zone of cuticular fusion.

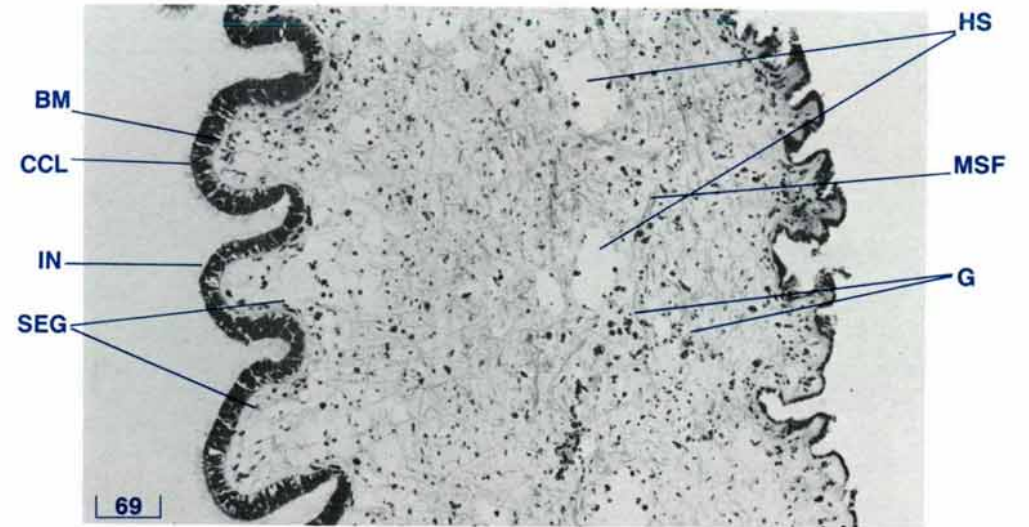




Figure 52 Labial palp (palp LS, Alcian blue stain, shell length 20 cm). BM basement membrane, CCL ciliated columnar epithelium, G granulocytes, HS haemolymph sinus, IN inner surface, MSF muscle fibres, SEG subepithelial glands.





THE ADDUCTOR MUSCLE

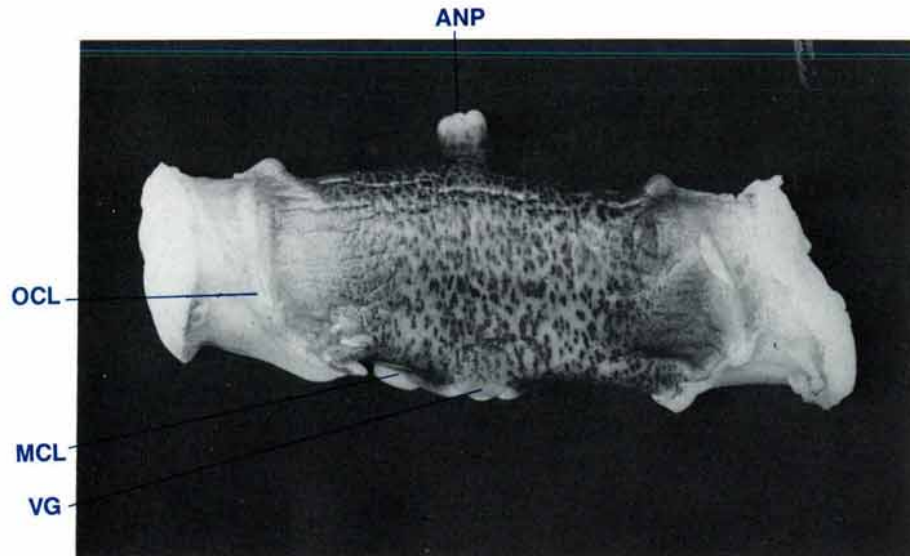


Figure 53 Posterior view of the adductor muscle (shell length 20 cm, $MgCl_2$ sedated).

ANP anal papilla, MCL middle ctenidial suspensory ligament, OCL outer ctenidial suspensory ligament, VG visceral ganglion.

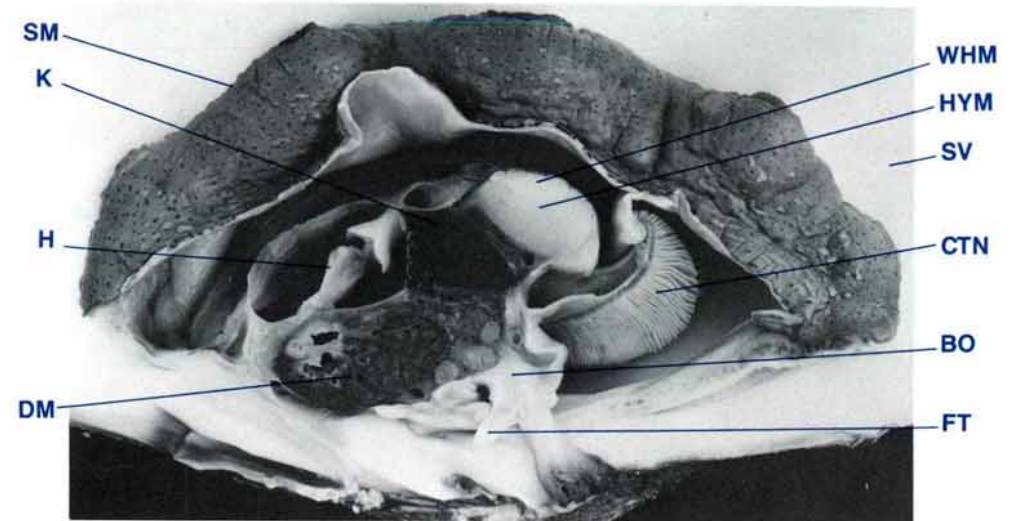


Figure 54 A mid-longitudinal view of a clam showing the two types of adductor muscle (shell length 20 cm, $MgCl_2$ sedated, formalin fixed).

BO byssal organ, CTN ctenidia, DM digestive mass, FT foot, H heart, HYM hyaline muscle, K kidney, SM siphonal mantle, SV shell valve, WHM white muscle.

Adductor Muscle — Anatomy

The adductor muscle is a firm, white and translucent, cylindrical organ (Fig. 53). It stretches between the inner surfaces of the shell valves. The attachment area on the inner surface of each valve is marked by a large scar (Fig. 11). Two types of muscle can be distinguished when the adductor muscle is cut transversely (Figs 6, 54). The smaller, dorsal, pearly-white, crescent-shaped muscle is the slow-reacting part of the adductor muscle and tends to be the tougher of the two muscle types. The larger ventral hyaline, or translucent, oval-shaped muscle is the quick-reacting part of the adductor muscle and tends to be softer and more friable. This latter muscle type constitutes the bulk of the adductor muscle. The dorsal and posterior surfaces of the

entire adductor muscle are brown (Fig. 53). A large nerve complex, the visceral ganglion, is situated medially on the ventral surface (Figs 38, 53). The adductor muscle of the giant clam is the posterior adductor muscle of other bivalves which have both anterior and posterior adductor muscles.

The outer ctenidial suspensory ligaments are attached to the posterior and ventral surfaces of the adductor muscle just medial to the ends of the adductor muscle (Figs 38, 53). The attachments of the middle ctenidial suspensory ligaments are ventral to the adductor muscle, on either side of the visceral ganglion (Figs 38, 53). Branches of the pallial arteries are located dorsally and medially to the ends of the adductor muscle (Fig. 91).

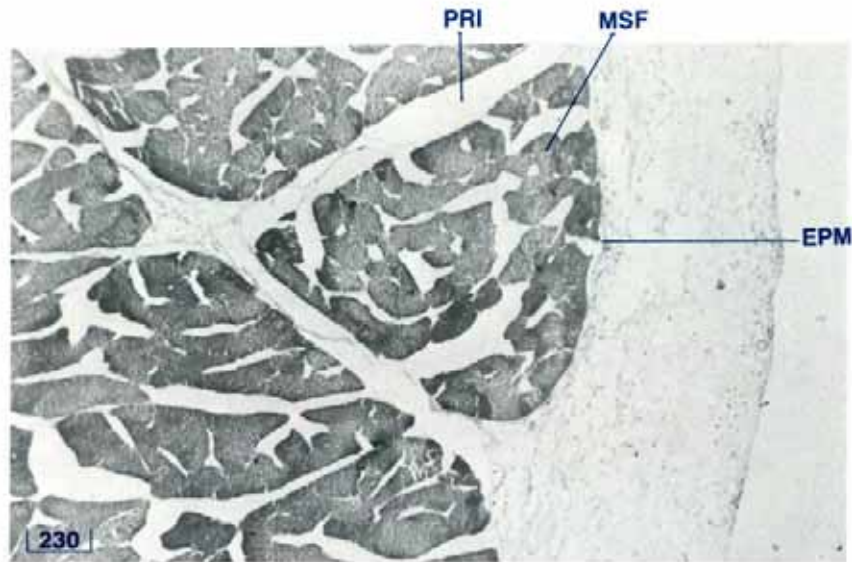


Figure 55 Adductor muscle showing the fibrous sheaths (adductor muscle TS, H & E stain, shell length 20 cm).
EPM epimysium, MSF muscle fibres, PRI perimysium.

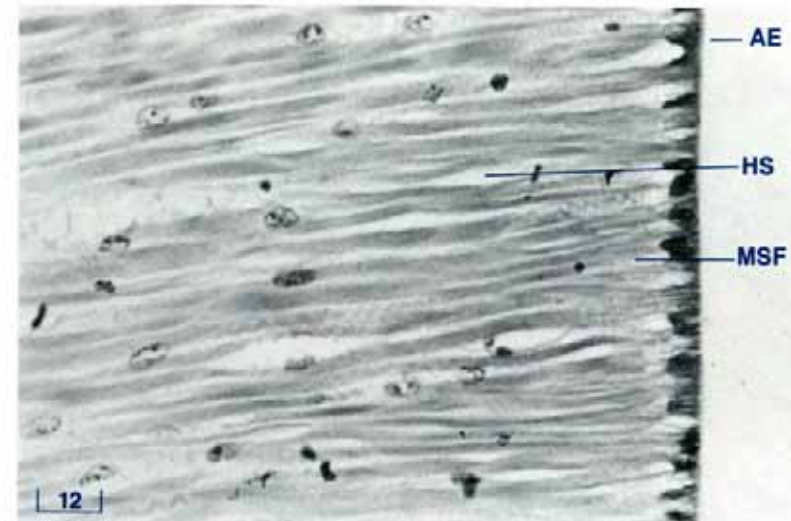


Figure 56 Adhesive epithelium which attaches the adductor muscle to the shell valve (adductor muscle LS, H & E stain, shell length 3 cm).
AE adhesive epithelium, HS haemolymph sinuses, MSF muscle fibres.

The adductor muscle is bounded anteriorly by the upper ends of the retractor muscles of the byssus-foot and by the kidney (Fig. 60), and dorsally by the anus and the excurrent water chamber (Fig. 54). Posteriorly and ventrally, the medial portion of the adductor muscle is bounded by the suprabranchial compartment of the excurrent water chamber. The posterior and ventral aspects of the lateral portions of the adductor muscle are bounded by the incurrent water chamber.

Adductor Muscle — Histology

Fibrous sheath

The adductor muscle fibres are enclosed by several fascial sheaths or layers of fibrous tissue (Fig. 55). Externally, the adductor muscle is surrounded by an external fascial sheath, the epimysium. Fibrous tissue radiates from this sheath into the adductor muscle to become the perimysium which encloses bundles of muscle fibres. Finally, each muscle fibre is enclosed by a thin layer of fibrous tissue, the endomysium. The fibrous tissue is collagenous. Throughout the epimysium and the perimysium, tiny undulating muscle fibres are also seen.

DOS



Figure 57 Striated muscle fibres of the translucent portion of the adductor muscle (adductor muscle LS, PTAH stain, shell length 20 cm). DOS double-oblique striations.

Haemolymph sinuses and zooxanthellal tubes containing zooxanthellae are common in the epimysium. Haemolymph sinuses and nerves are also present in the perimysium. Where the surface of the adductor muscle is adjacent to a water compartment, the epimysium is covered with a layer of ciliated cuboidal cells. Beneath this epithelium, and discharging through it, is a layer of type 3 mucin (see page 132) glandular cells.

Muscle fibres

The muscle fibres appear as straight to undulating bands of eosin-staining material containing scattered nuclei which appear as dark-staining elongated bodies, often with blunt ends. It is difficult to identify individual fibres (Fig. 56). Double-oblique striations are present in the translucent or quick-reacting portion of

the adductor muscle (Fig. 57) but not in the white or slow-reacting portion of the adductor muscle.

Adhesive epithelium

The adductor muscle fibres are attached to the inner surface of the shell valves by a specialised layer of cells called adhesive or holding epithelium (Fig. 56). The individual cells have indistinct boundaries and large round nuclei. These cells are modified cuboidal epithelium of the lateral surface of the lateral mantle.





THE BYSSAL ORGAN AND FOOT

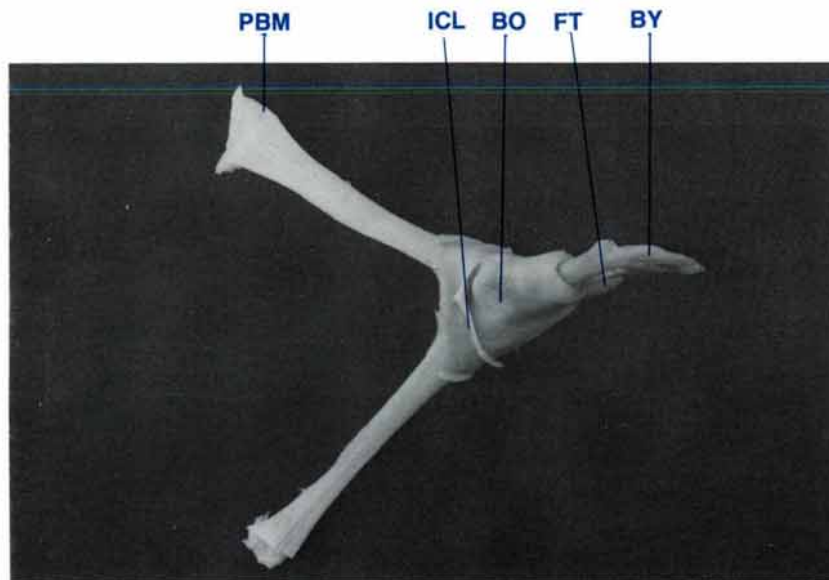


Figure 58 Posterior view of the byssal organ, byssus, foot and paired retractor muscles, (shell length 20 cm, $MgCl_2$ sedated, formalin fixed).
BO byssal organ, **BY** byssus, **FT** foot, **ICL** inner ctenidial suspensory ligament, **PBM** posterior byssal/pedal retractor muscles.

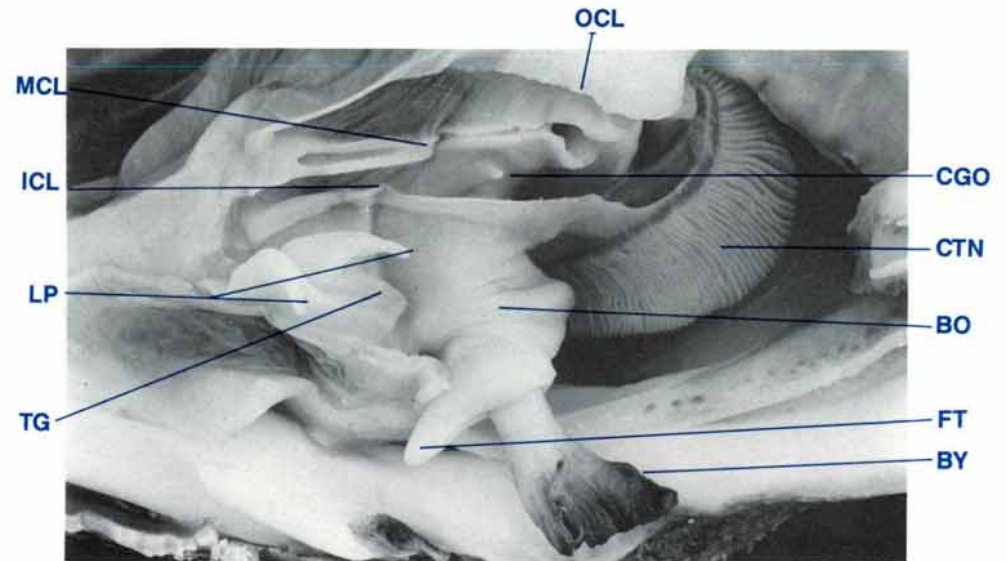


Figure 59 Lateral view of the byssal organ and foot; shell valve, lateral mantle and ctenidia removed (shell length 20 cm, $MgCl_2$ sedated, formalin fixed).
BO byssal organ, **BY** byssus, **CGO** common genital orifice, **CTN** ctenidia, **FT** foot, **ICL** inner ctenidial suspensory ligament, **LP** labial palps, **MCL** middle ctenidial suspensory ligament, **OCL** outer ctenidial suspensory ligament, **TG** transverse oral groove.

Byssal Organ and Foot — Anatomy

The byssal organ and foot (Figs 58, 59) form a 'boot-shaped' structure with the byssal threads protruding from the 'heel' of the organ through a byssal canal. Glands within the organ secrete an anchoring mass of fine byssal threads known collectively as the byssus. The 'toe' is the atrophied foot of the young clam and points towards the anterior end of the clam. It contains a ventral groove, the byssal groove. The root of the byssus is located in numerous dorso-ventrally orientated byssal crypts surrounded by the byssal glands in the ventral ends of the posterior byssal/pedal retractor muscles. The byssal secretions or threads coalesce to form a common byssal trunk or byssus. The byssus passes down the byssal canal which is also sur-

rounded by the byssal gland and reaches the clam's substrate through the byssal gape between the ventral edges of the shell valves. The crystalline style and its sac border the byssal organ on its left, posterior and right sides (Fig. 64).

The paired pedal ganglia which innervate the foot are located beneath the muscular wall just medial to the junction between the anterior of the byssal organ and foot, and the ventral wall of the digestive mass and reproductive organ (Figs 126, 132).

The byssal organ is attached to the inner surface of the shell valves by two pairs of muscles, the posterior and the anterior byssal/pedal retractor muscles. The posterior byssal/pedal retractor muscles are cylindrical to strap-shaped (Figs 58, 60).

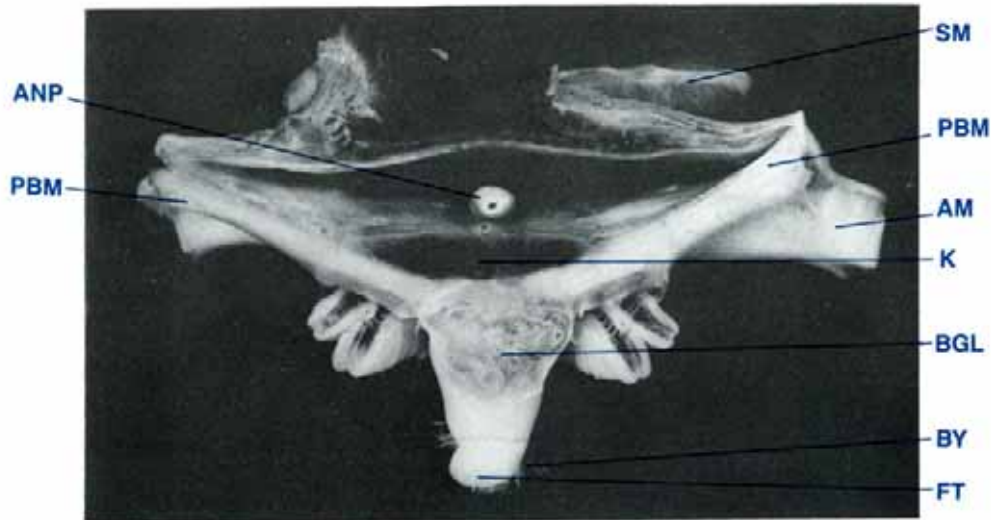


Figure 60 Transverse section of clam showing byssal organ, foot and posterior byssal/pedal retractor muscles (shell length 35 cm, MgCl₂ sedated, formalin fixed).

AM adductor muscle, ANP anal papilla, BGL byssal gland, BY byssus, FT foot, K kidney, PBM posterior byssal/pedal retractor muscles, SM siphonal mantle.

BYSSAL ORGAN AND FOOT — COMPARATIVE ANATOMY

Species	Size of byssus (adult clam)
<i>T. gigas</i>	small
<i>T. derasa</i>	small
<i>T. squamosa</i>	small to large
<i>T. maxima</i>	large
<i>T. crocea</i>	large
<i>T. tevoroa</i>	absent
<i>H. hippopus</i>	absent
<i>H. porcellanus</i>	absent

They attach the postero-dorsal area of the byssal organ to the shell valves just anterior to the attachments of the adductor muscle (Fig. 11). The small anterior byssal/pedal retractor muscles (Fig. 17) attach the dorsal anterior area of the byssal organ to the shell valves between the cardinal teeth and the umbonal cavity. This attachment is posteriomedial to the visceral pallial attachment lines.

The top of the byssal organ and foot joins the posterior end of the digestive mass and reproductive organ (Figs 69, 138). The muscular outer layers of these organs are continuous.

The antero-dorsal surface of the byssal organ is covered by the rear of the digestive mass and reproductive organ (Fig. 138). Laterally the upper portion of the byssal organ is surrounded by

the suprabranchial compartment of the excurrent water chamber (Fig. 59). Also, the inner ctenidial suspensory ligament is attached to the lateral and posterior walls of the byssal organ just ventral to the attachment areas of the posterior byssal/pedal retractor muscles (Fig. 59). The lower portion of the byssal organ and foot is surrounded by the incurrent water chamber (Figs 34, 59).

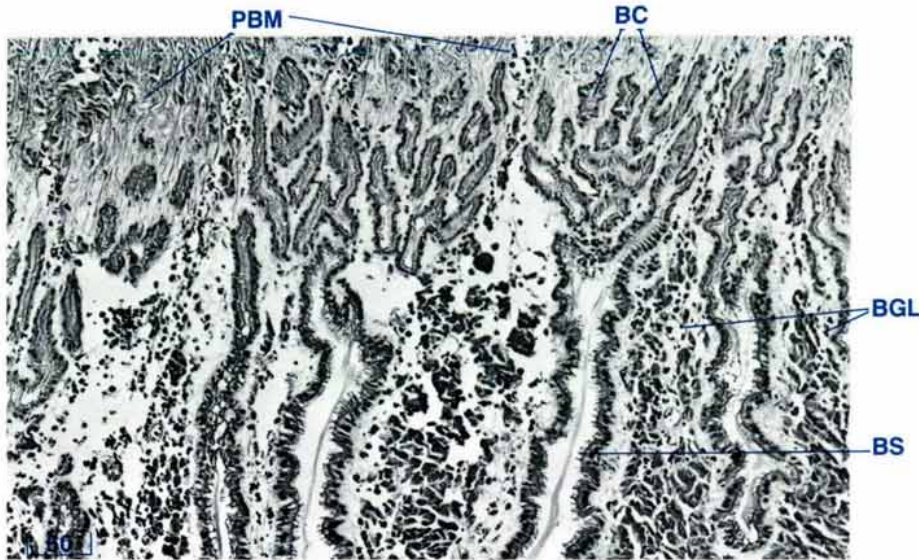


Figure 61 Byssal glands and crypts at the ventral end of the posterior byssal/pedal retractor muscles (TS, H & E stain, shell length 3 cm).
BC byssal crypts, **BGL** byssal glands, **BS** byssal secretion, **PBM** posterior byssal/pedal retractor muscle.

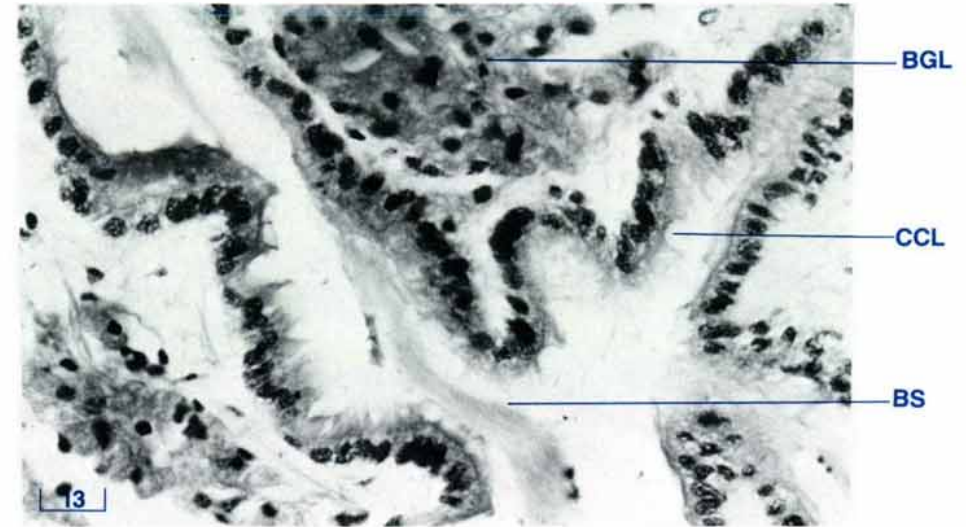


Figure 62 Byssal glands and crypts, a close up view of Fig. 61 (TS, H & E stain, shell length 10 cm).
BGL byssal gland, **BS** byssal secretion, **CCL** ciliated columnar epithelium.

Byssal Organ and Foot — Histology

In the byssal organ, a collection of byssal glands surround the byssal crypts in the ventral ends of the posterior byssal/pedal retractor muscles (Figs 61, 64,). Byssal glands are also adjacent to the byssal canal (Fig. 65), and the byssal groove (Fig. 66). Ducts from these glands empty into the lumen of the crypts (Fig. 63) and the canal. The cells of the byssal gland are large and globular-shaped with an eosinophilic cytoplasm and an indistinct border, and they have dark, speckled nuclei (Fig. 62). The cytoplasm of these byssal gland cells contain type 3 and type 4 mucins (see page 132).

The cavities within the byssal system are lined with a ciliated columnar epithelium which changes to a cuboidal cell type in

the upper crypts. Generally all the spaces are filled with byssal secretion consisting of fine fibrillae aggregated into a more or less closely packed mass of strands. The byssal threads contain type 4 mucins (see page 132). The cement-like material joining the fibres together contains type 3 mucins (see page 132).

The plantar gland is a zone of glandular cells located in the subepithelial space of the terminal part of the exterior of the foot (Figs 66, 67). The plantar cells have a pale, grey, foamy, cytoplasm with indistinct cell boundaries and dark nuclei of variable shape. These cells contain both type 3 and type 4 mucins (see page 132). Ducts pass from this gland to the external surface of the foot.

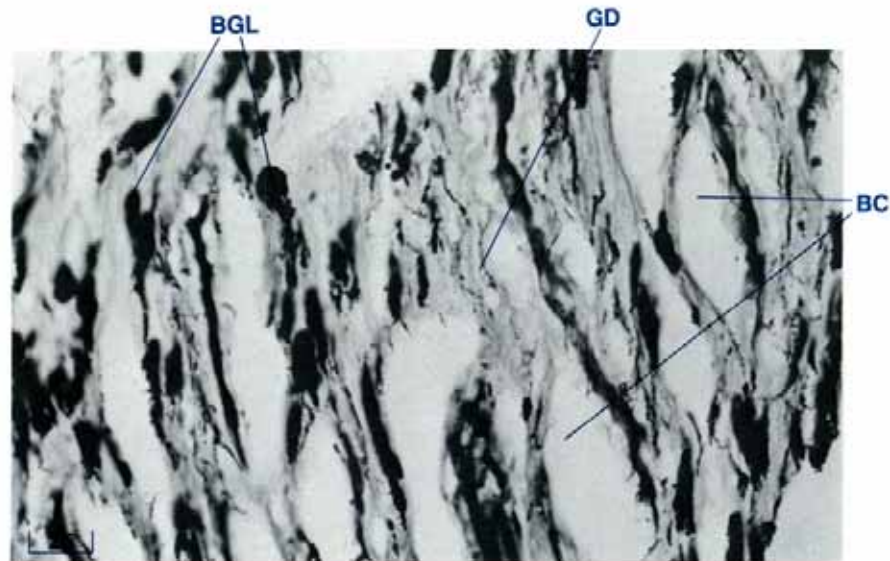


Figure 63 Byssal glands, showing ducts draining into the byssal crypts (TS, Toluidine Blue stain, shell length 12 cm).
BGL byssal gland, BC byssal crypts, GD glandular ducts.

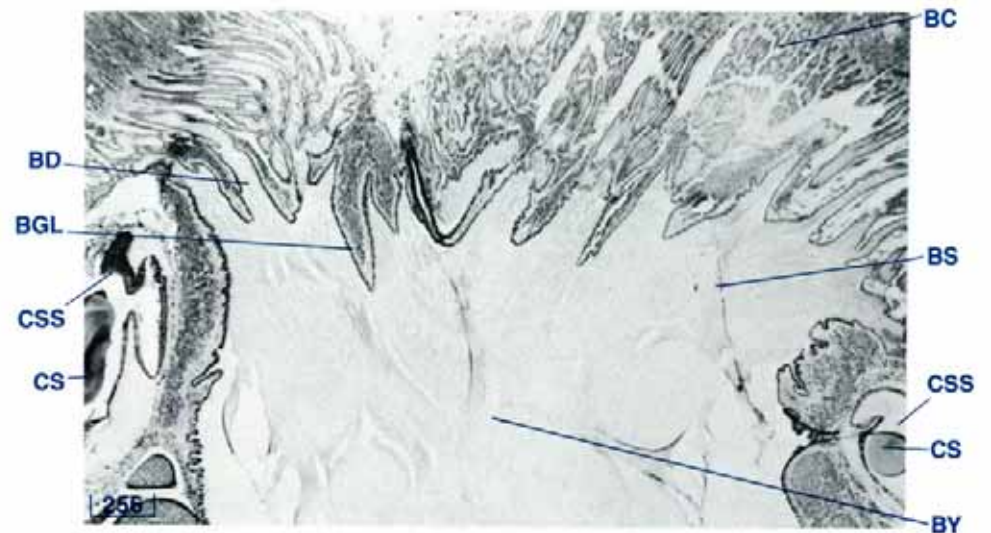


Figure 64 The byssal organ showing the formation of the byssus (TS, H & E stain, shell length 6 cm).
BC byssal crypts, BD byssal ducts, BGL byssal glands, BS byssal secretion, BY byssus, CS crystalline style, CSS crystalline style sac.

A third gland, the accessory byssal gland, is located each side of the byssal groove between the byssal gland internally and the plantar gland externally (Figs 65, 66). The accessory byssal gland contains type 3 mucins (see page 132).

The posterior byssal/pedal retractor muscles are surrounded by sheaths of collagenous connective tissue containing haemolymph vessels.

A network of collagenous connective tissue and muscle bundles containing large numbers of haemolymph sinuses surround the byssal groove, byssal and accessory byssal glands. A large artery, the pedal artery, is situated in the anterior of the foot (Fig. 65). Branches of the pedal nerve are also present

nearby. The byssal organ and foot are enclosed by a thin longitudinal muscular layer, a thick circular muscular layer, and finally the epithelium. This epithelium is ciliated columnar on the lower byssal organ and foot but is simple cuboidal on the upper areas of the byssal organ.

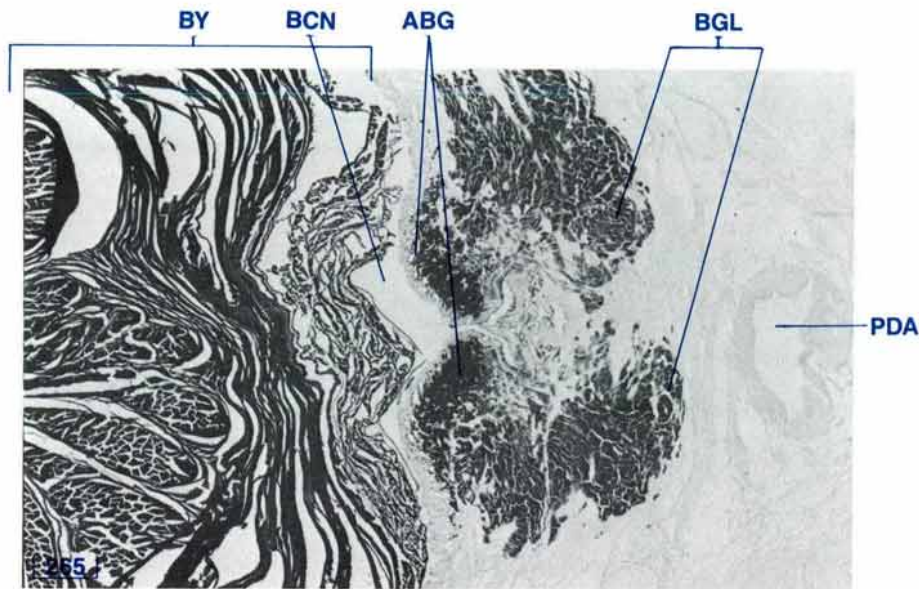


Figure 65 Section through the anterior part of the byssal canal (byssal canal TS, Toluidine Blue stain, shell length 12 cm).

ABG accessory byssal gland, BCN byssal canal, BGL byssal gland, BY byssus, PDA pedal artery.

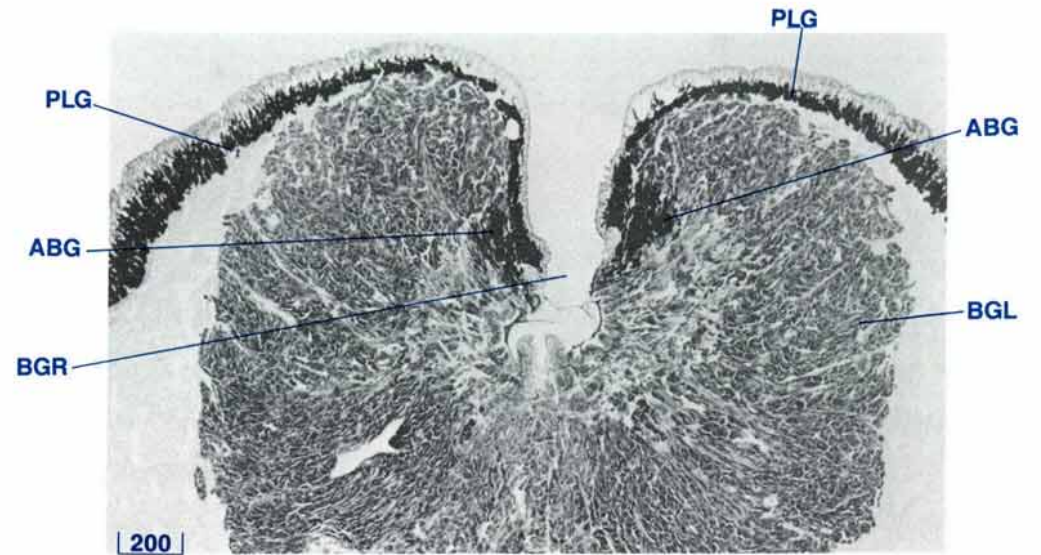

Figure 66 A section of the upper byssal groove (foot TS, Toluidine Blue stain, shell length 12 cm).

ABG accessory byssal gland, BGL byssal gland, BGR byssal groove, PLG plantar gland.

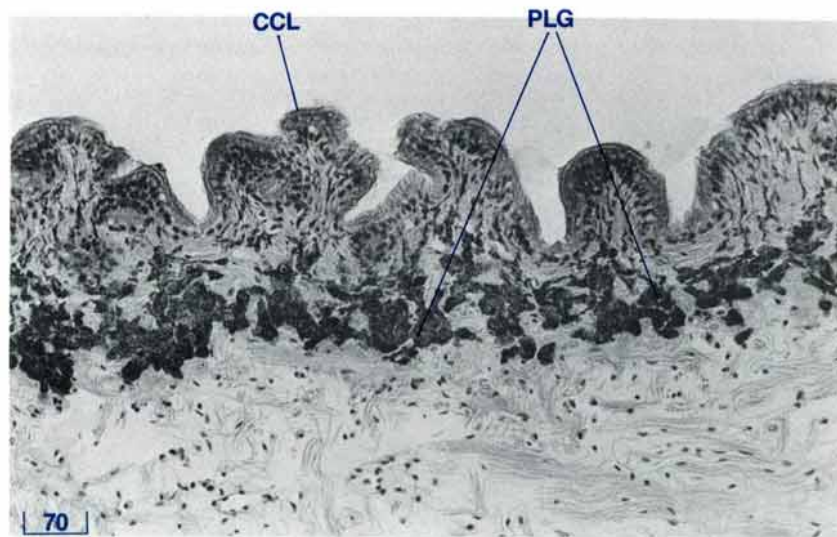


Figure 67 Subepithelial glands of the foot (TS, Alcian Blue stain, shell length 20 cm).

CCL ciliated columnar epithelium, PLG plantar gland.

The first part of the document discusses the importance of maintaining accurate records of all transactions. It emphasizes that every entry, no matter how small, should be recorded to ensure the integrity of the financial statements. The second part of the document provides a detailed breakdown of the company's revenue streams, including sales from various product lines and services. It also outlines the major expenses, such as salaries, rent, and utilities, and explains how these costs are allocated across different departments. The final section of the document summarizes the overall financial performance for the period, highlighting key trends and areas for improvement. It concludes with a statement of the company's commitment to transparency and accountability in its financial reporting.



THE DIGESTIVE SYSTEM

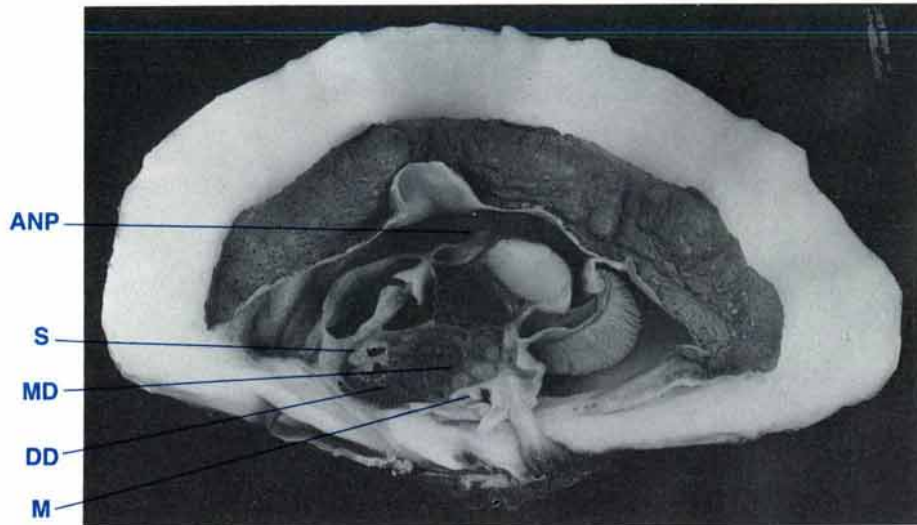


Figure 68 A mid-longitudinal section of a clam to show the digestive system (shell length 20 cm $MgCl_2$ sedation, formalin fixed).
ANP anal papilla, DD digestive diverticula, M mouth, MD midgut, S stomach.

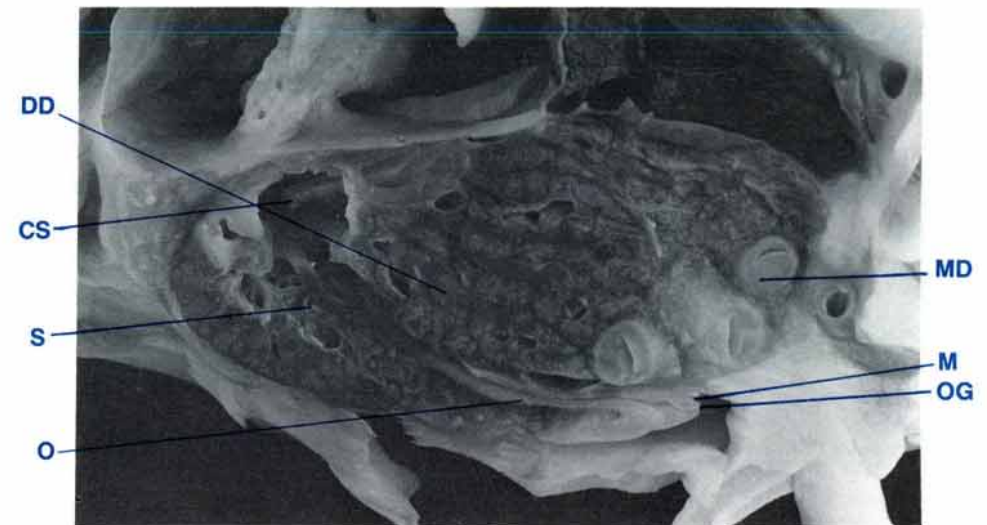


Figure 69 Mid-longitudinal section of the digestive mass (shell length 20 cm, $MgCl_2$ sedation, formalin fixed).
CS crystalline style, DD digestive diverticula, M mouth, MD midgut, O oesophagus, OG oral groove, S stomach.

Digestive System — Anatomy

The digestive system consists of the digestive mass in the anterior of the clam (Fig. 68) and the rectum and anus located posteriodorsal to the digestive mass (Figs 89, 101). The organs included in the digestive mass are the labia (lips), oral groove, mouth, oesophagus, stomach, digestive gland, crystalline style sac and style, the intestinal groove, and midgut (or small intestine) (Fig. 69). The organs of the digestive mass are enclosed by a muscular wall which is continuous with that of the byssal organ and foot. The stomach and digestive gland are situated in the anterior of the digestive mass while the coils of the midgut are situated in the posterior of the digestive mass.

The oral groove is the continuation of the central food groove. It has two segments, the paired lateral (distal) segments (Fig. 37) and a single transverse (proximal) segment (Figs 34, 37). The lateral segments connect the anterior ends of the central food grooves and the outer and inner marginal food grooves to the ends of the transverse segment. Part of each lateral segment of the oral groove is bounded on each side by a labial palp (Fig. 37). The remainder of each lateral segment and the whole of the transverse segment are bounded by labia. The oral groove is situated adjacent to the hinge surface of the shell valve. In the middle of the transverse oral groove there is a small round orifice, the mouth, which leads into the oesophagus (Fig. 34).

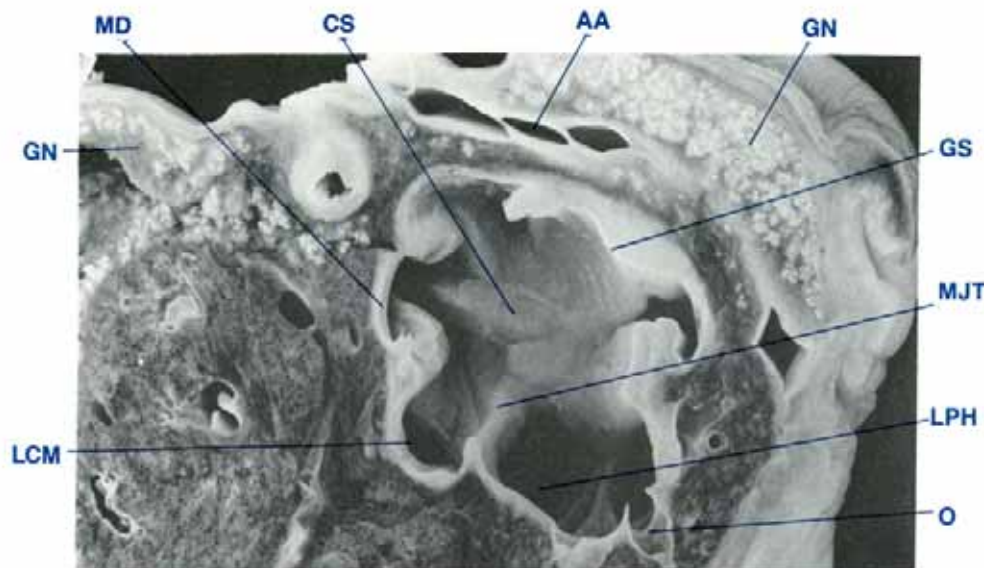


Figure 70 A mid-longitudinal section of the digestive mass to show the left internal surface of the stomach (shell length 35 cm, MgCl₂ sedation, formalin fixed).

AA anterior aorta, CS crystalline style, GN gonad, GS gastric shield, LCM left caecum, LPH left pouch, H left pouch, MD midgut, MJT major typhlosole, O oesophagus.

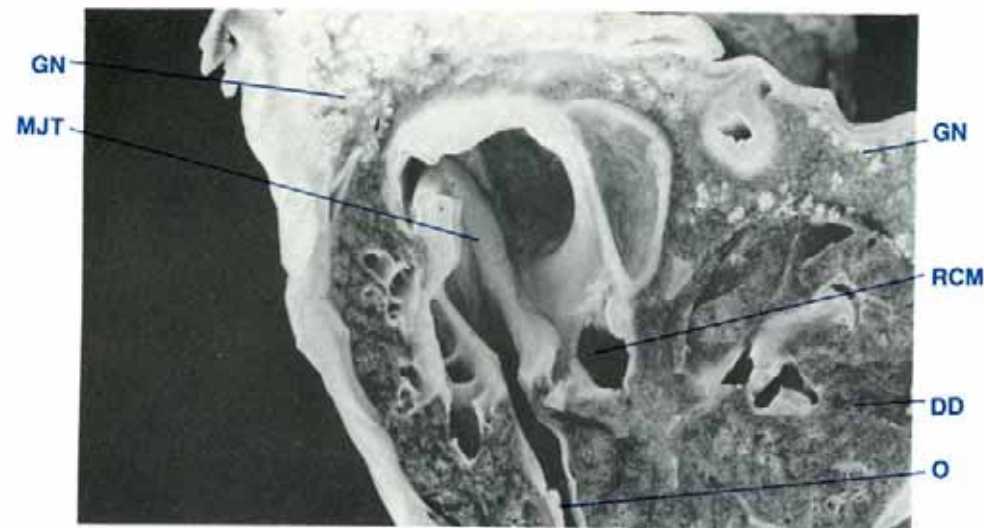


Figure 71 A mid-longitudinal section of the digestive mass to show the right internal surface of the stomach (shell length 35 cm, MgCl₂ sedated, formalin fixed).

DD digestive diverticula, GN gonad, MJT major typhlosole, O oesophagus, RCM right caecum.

The oesophagus travels antero-dorsally for a short distance to enter the stomach (Fig. 69). The stomach contains several features peculiar to molluscs (Figs 70, 71). These include a crystalline style and entrances to the tubular style sac, the midgut, left and right caeca and a left pouch. The stomach also has a gastric shield and a major typhlosole.

The caeca and pouch lead to primary and secondary branching ducts which terminate in the glandular tissue of the digestive diverticula (Figs 70, 71, 72). These diverticula form a dark brown mass which surrounds the stomach. The midgut and style sac leave the stomach together and run parallel to each other for a short distance on the left side of the clam before the midgut branches off at right angles to form the coils of the midgut in the posterior region of the digestive mass (Fig. 72). The midgut

becomes the rectum as it passes through the ventricle and bulbous arteriosus of the heart to end in the anal papilla in the middle of the dorsal side of the adductor muscle (Figs 101, 88).

The crystalline style and its associated tapered tubular sac continue on past the junction where the midgut branches off, along the left side of the digestive mass and then along the left dorsal, the rear dorsal, and finally the right dorsal area of the byssal organ where it ends (Figs 64, 72).

The major typhlosole is located on one edge of the junction between the tubular style sac and the intestinal groove (Fig. 80). The major typhlosole runs across the stomach wall to enter the caeca (Figs 70, 71).

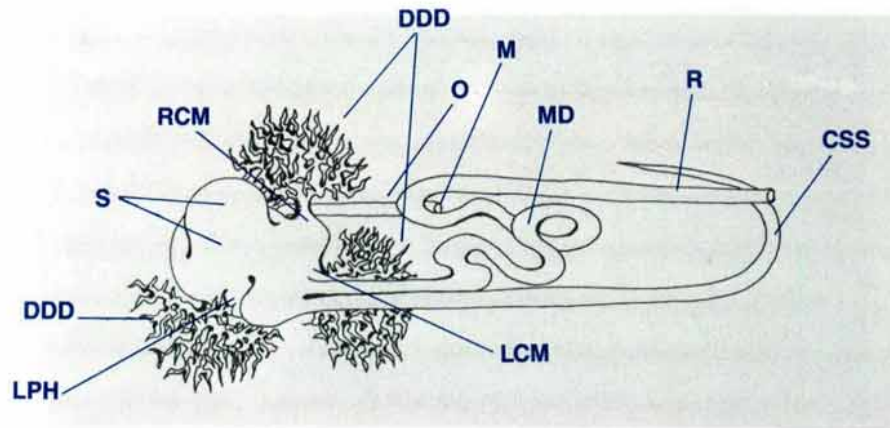


Figure 72 Diagrammatic view of the digestive system viewed from the dorsal aspect (shell length 35 cm, $MgCl_2$ sedated).

CSS crystalline style sac, **DDD** ducts to digestive diverticula, **LCM** left caecum, **LPH** left pouch, **M** mouth, **MD** midgut, **O** oesophagus, **RCM** right caecum, **R** rectum, **S** stomach.

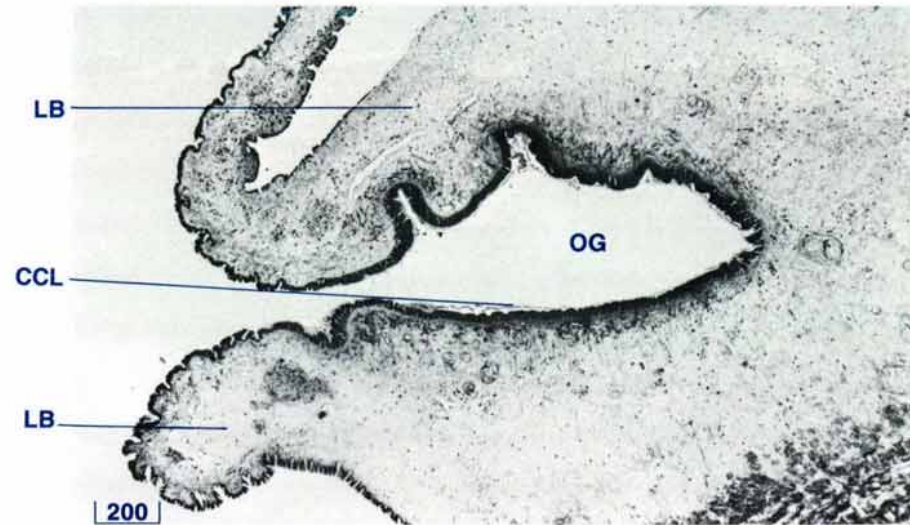


Figure 73 Oral groove (oral groove TS, H & E stain, 20 cm shell length).

CCL ciliated columnar epithelium, **LB** labia, **OG** oral groove.

The digestive mass is attached to the antero-dorsal surface of the byssal organ (Fig. 69) and to the ventral internal surface of the shell valves along the visceral-pallial attachment lines (Figs 12, 17).

The digestive mass is bounded completely by gonads in the sexually mature clam (Figs 137, 138). In the sexually immature clam, the digestive mass is bounded by the excurrent water chamber anteriorly, by the pericardium dorsally and by the kidney postero-dorsally. It is bounded by the byssal organ posteriorly, by the shell valves, ligamental hinge gland and hinge ventrally, and by the ctenidia, labial palps and the incurrent water chambers laterally (Figs 68, 69).

Digestive System — Histology

The gastrointestinal tract of the digestive system consists of a ciliated columnar epithelial-lined tube with ducts leading to the glandular digestive cells. The digestive diverticula and midgut are surrounded by a network of haemolymph sinuses containing groups of macrophages.

The labia have a collagenous tissue framework and they, like the oral groove, are lined with an even layer of ciliated columnar epithelium (Fig. 73). The oesophagus is lined with an even layer of ciliated columnar epithelium which sits on a narrow zone or basement membrane of a type 3 mucin matrix (see page 132). The appearance of the epithelium in the stomach varies. One area

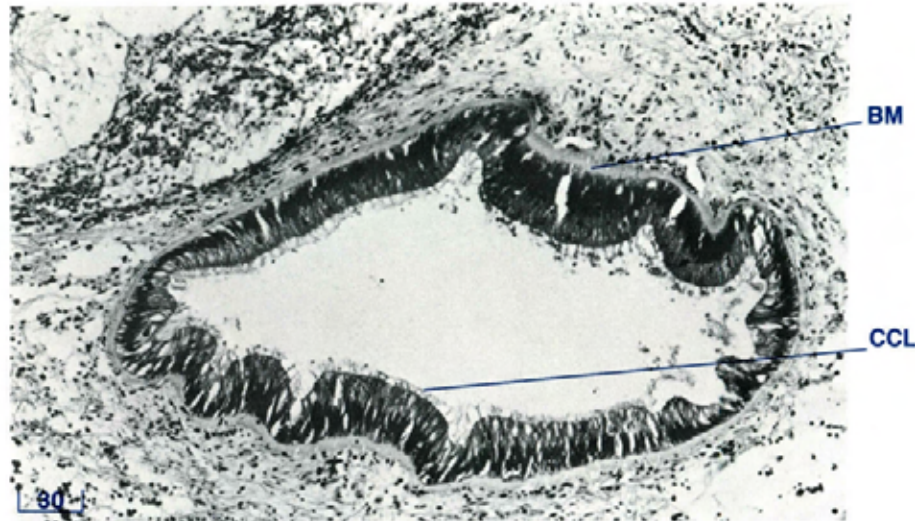


Figure 74 Oesophagus (TS, H & E stain, 20 cm shell length).
CCL ciliated columnar epithelium, BM basement membrane.

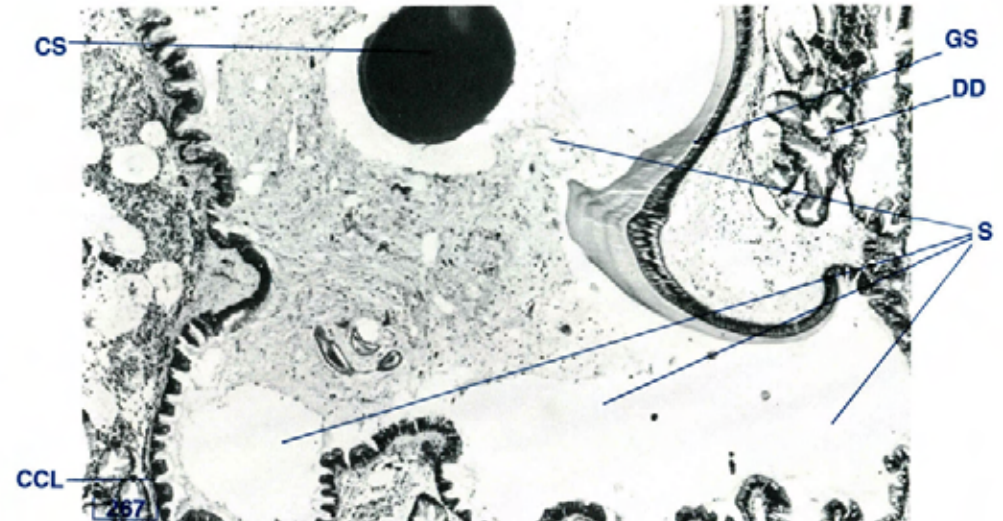


Figure 75 Digestive mass showing stomach (TS, H & E stain, 3 cm shell length).
CCL ciliated columnar epithelium, CS crystalline style, DD digestive diverticula, GS gastric shield, S stomach.

of the stomach epithelium is covered by a plaque of eosinophilic, structureless material, the gastric shield (Figs 75, 76). The epithelium beneath this plaque is exceptionally tall and the nuclei are situated midway between the cell base and the cell apex. Other areas of the stomach wall are covered with ciliated epithelium which may be thrown up into folds (Fig. 77). The stomach epithelium rests on a type 3 mucin matrix base (see page 132) of variable thickness. It contains low numbers of dark staining, spindle-shaped nuclei with sparse, elongated, eosinophilic cytoplasm. This matrix does not stain with H & E.

A round, laminated structure, the crystalline style is present within the stomach cavity (Fig. 75). The style is made of type 2 mucin (see page 132) and occupies much of the style sac (Fig. 80).

On one side of the entrance to the style sac from the midgut, the epithelium is tall with nuclei situated in the middle of the cells (Figs 80, 82). This is the major typhlosole. The style sac and associated intestinal groove sits on a thick type 3 mucin matrix (see page 132). The midgut is lined with an even layer of ciliated columnar epithelium which rests on a type 3 mucin matrix (see page 132) (Fig. 83) similar to that surrounding the stomach and the style sac (Fig. 81).

The rectum is lined with a layer of ciliated columnar epithelium and is surrounded by a zone of collagenous connective tissue with a thin layer of both longitudinal and circular muscle fibres as it passes through the heart chambers (Fig. 84). The rectum terminates in the anus within the anal papilla. The anus is surrounded by the large anal mucous gland (Fig. 85).

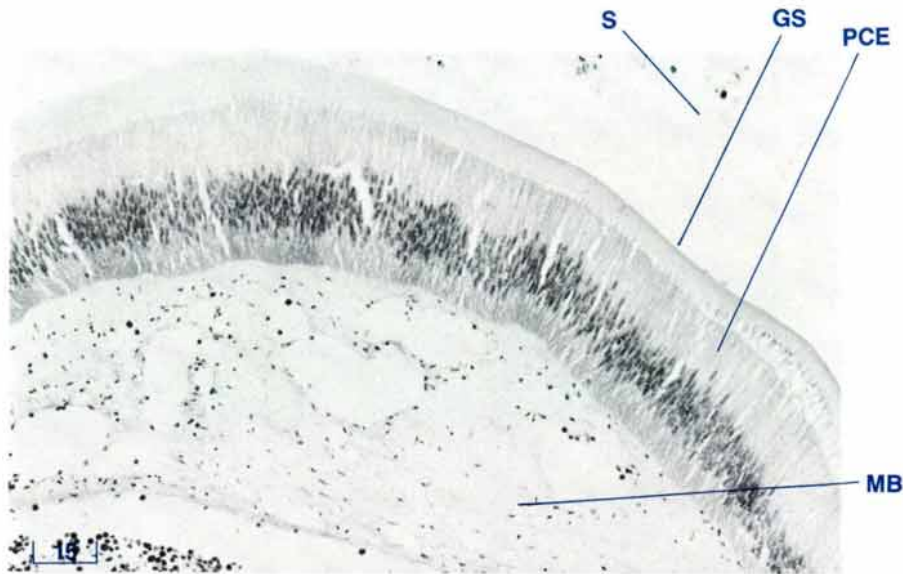


Figure 76 Stomach wall showing gastric shield (TS, H & E stain, 3 cm shell length).

GS gastric shield, **MB** mucopolysaccharide (type 3) base, **PCE** pseudostratified columnar epithelium, **S** stomach.

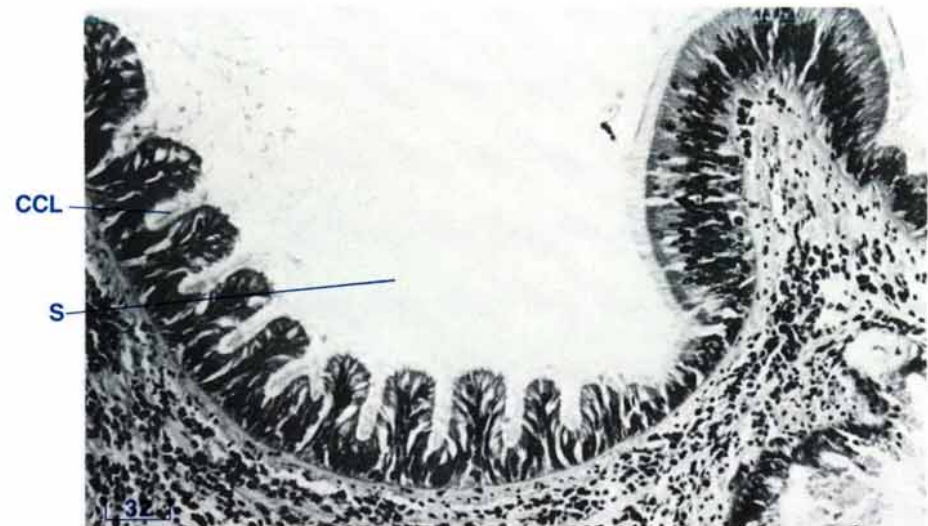

Figure 77 Lining of stomach wall not covered by gastric shield (TS, H & E stain, 10 cm shell length).

CCL ciliated columnar epithelium, **S** stomach.

Single, type 2 mucin cells (see page 132) are present in the epithelial lining of most of the gut including the labia, oral groove, oesophagus, stomach, intestinal groove, style sac, midgut, rectum and anus. Subepithelial type 3 mucin glands (see page 132) which discharge through the epithelial lining are to be found in the labia, oral groove, midgut and anus.

Branching from the stomach wall, in particular from the two caeca and the pouch, are numerous primary and secondary ducts which lead into the glandular digestive diverticula. These ducts are lined with columnar epithelium which may or may not have cilia. The finger-shaped diverticular tubules appear ovoid or circular in cross section and the tubule epithelium is commonly divided into four segments by deep-set, ciliated crypts. These cilia are difficult to see in routine histological sections.

The tubule epithelium is comprised of 3 distinct cell types:

1. minute undifferentiated stem cells,
2. deeply basiphilic flagelliform ciliated cells which form the tubule crypts (Fig. 78) and
3. larger holocrine secretory cells which comprise the inter-crypt tubule epithelium (Figs 78, 79). The basal cytoplasm of these cells is dark basiphilic and the apical cytoplasm a foamy, light eosinophilic. The nuclei are large and vesicular.

These holocrine secretory cells may be seen in various stages of secretion. The cytoplasm of these cells appears as a large, relatively clear space. The cell outline is pale with an occasional small, dark (pyknotic) nucleus located laterally between adjoining cells or even apically. These cells may contain variable amounts of an olive-green granular to amorphous material. The

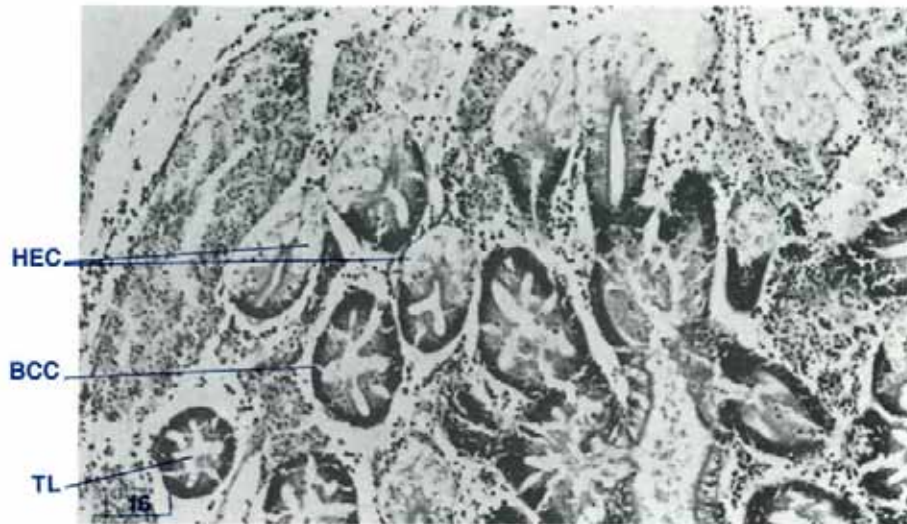

Figure 78 Digestive diverticula (TS, H & E stain, 10 cm shell length). BCC basiphilic crypt cell, HEC holocrine secretory cell, TL tubular lumen.

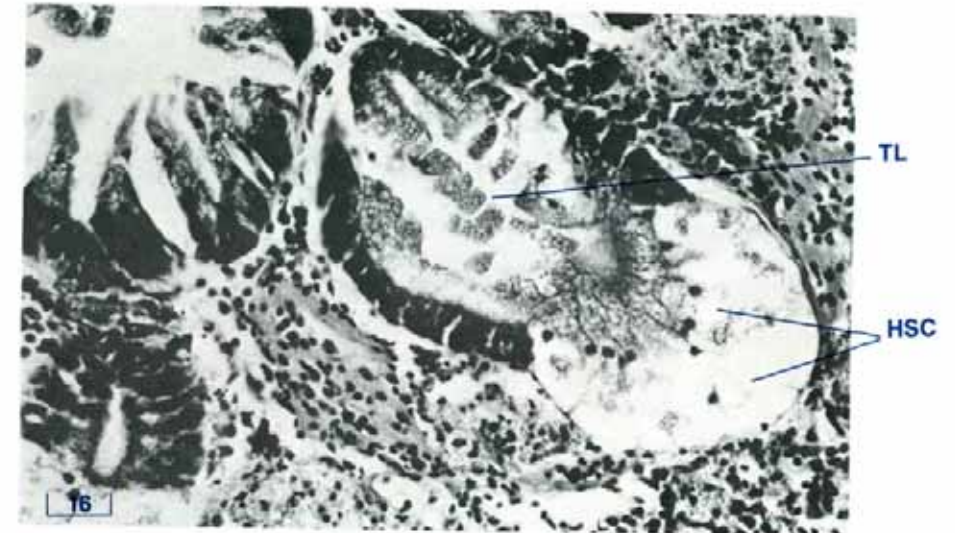


Figure 79 Digestive diverticula showing holocrine secretory cells (TS, H & E stain, shell length 10 cm). HSC holocrine secretory cell, TL tubular lumen.

presence and density of cells showing advanced stages of holocrine secretion may vary greatly.

Surrounding the stomach, digestive diverticulae and midgut is a connective tissue network which contains numerous haemolymph sinuses and macrophage centres, as well as large numbers of granulocytes and degenerating zooxanthellae (Fig. 160). Vast numbers of zooxanthellae in all stages of digestion are present in these macrophages. The macrophage centres are composed of cells with dark, irregular-shaped nuclei and pale pink cytoplasm with indistinct borders. Strands of muscle fibres may also be seen in this connective tissue. They appear to run from the muscular wall, which encloses the digestive mass, to parts of the digestive system.

The digestive mass is enclosed by a thin inner longitudinal muscular band and a thick outer circular muscular band, which are continuous with those of the byssal organ and foot.

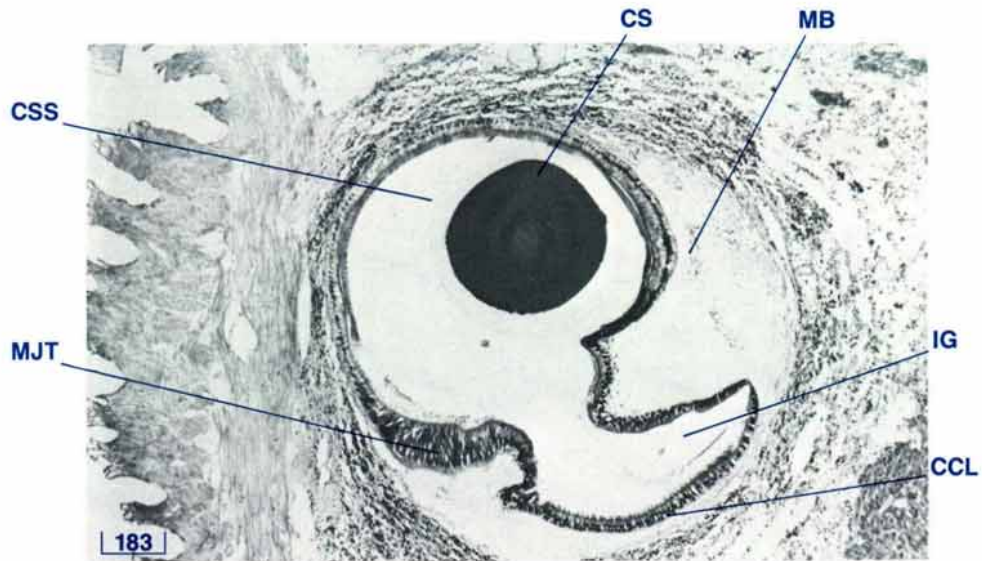


Figure 80 Crystalline style and sac (TS, H & E stain, 10 cm shell length).

CCL ciliated columnar epithelium, CSS crystalline style sac, CS crystalline style, IG intestinal groove, MB mucopolysaccharide (type 3) base, MJT major typhlosole.

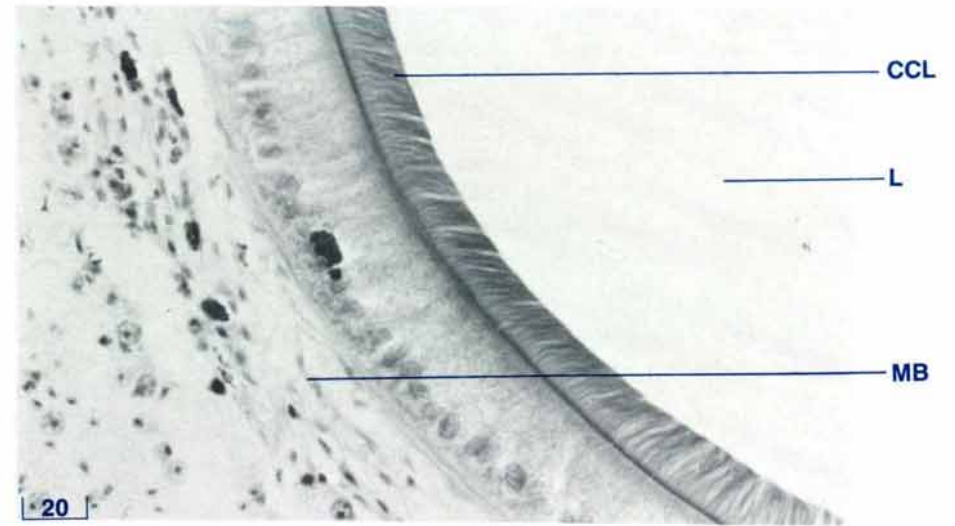


Figure 81 Crystalline style sac wall (TS, H & E stain, 3 cm shell length).

CCL ciliated columnar epithelium, L lumen, MB mucopolysaccharide (type 3) base.

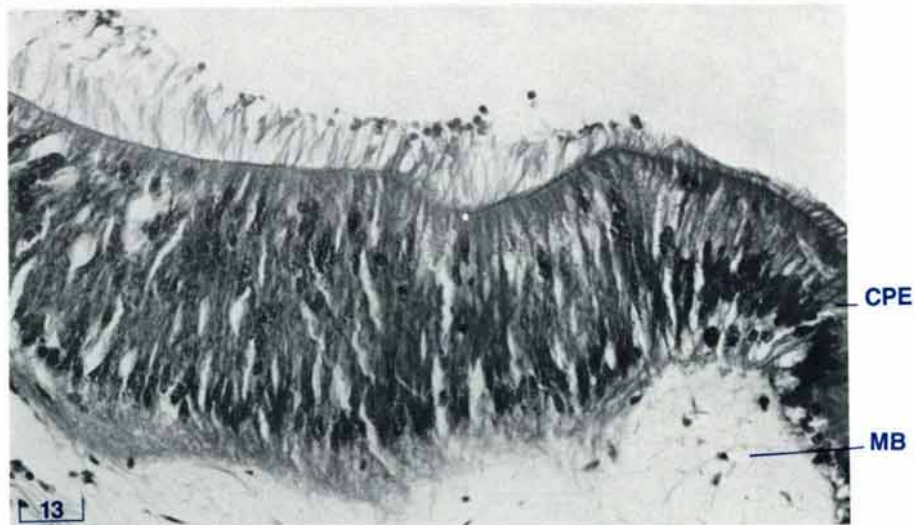


Figure 82 Major typhlosole of crystalline style sac (TS, H & E stain, shell length 10 cm).

CPE ciliated pseudostratified columnar epithelium, MB mucopolysaccharide (type 3) base.

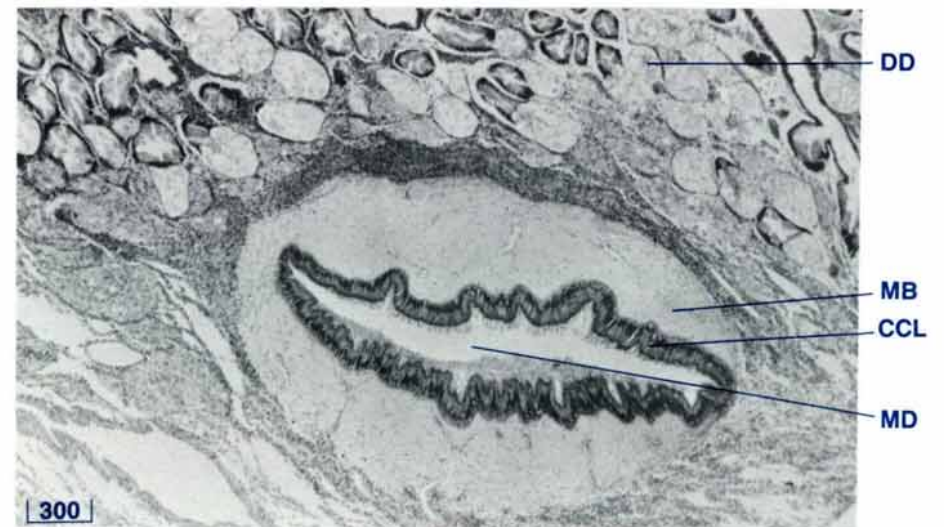


Figure 83 Midgut (TS, H & E stain, shell length 12 cm).

CCL ciliated columnar epithelium, DD digestive diverticula, MB mucopolysaccharide (type 3) base, MD midgut.

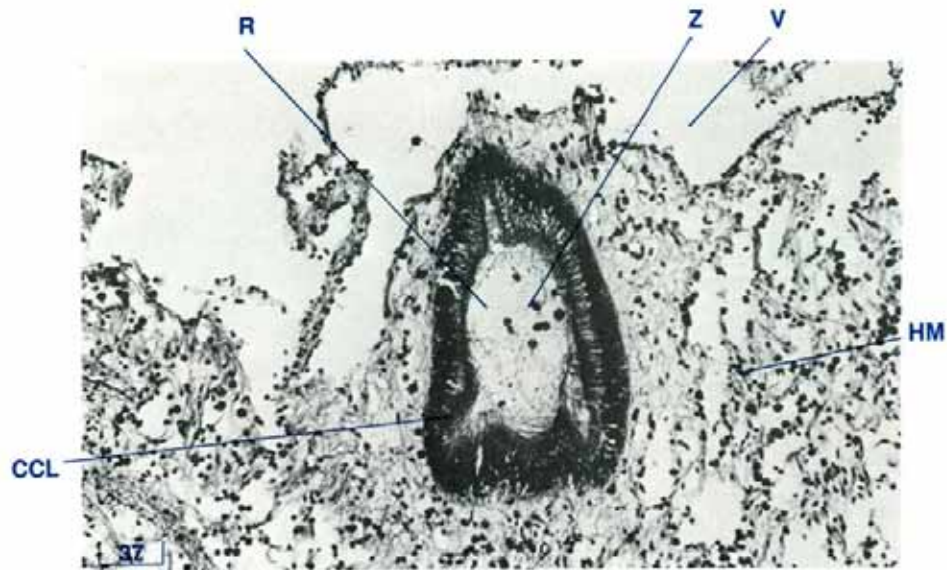


Figure 84 Rectum passing through the heart (TS, H & E stain, 3 cm shell length).

CCL ciliated columnar epithelium, HM heart muscle, R rectum, V ventricle, Z zooxanthellae.

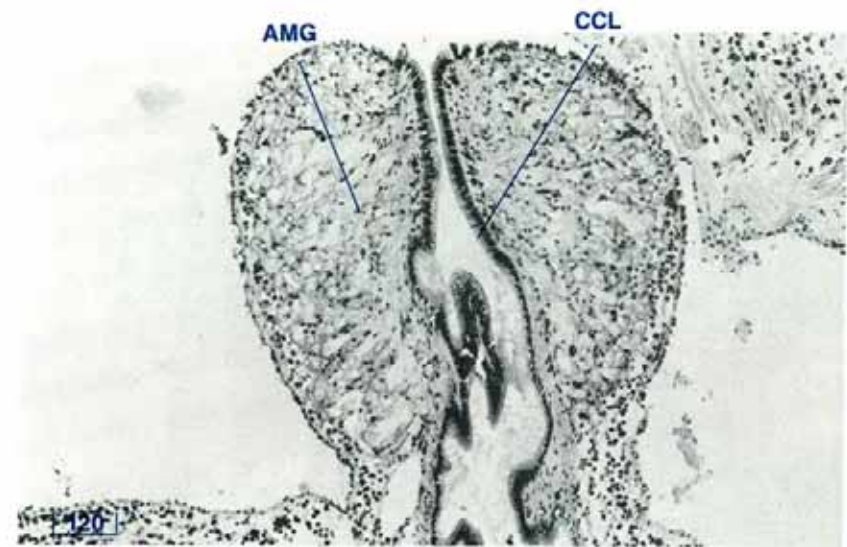



Figure 85 Anal papilla (TS, H & E stain, 3 cm shell length).

AMG anal mucous gland, CCL ciliated columnar epithelium.



THE HEART AND HAEMOLYMPH SYSTEM

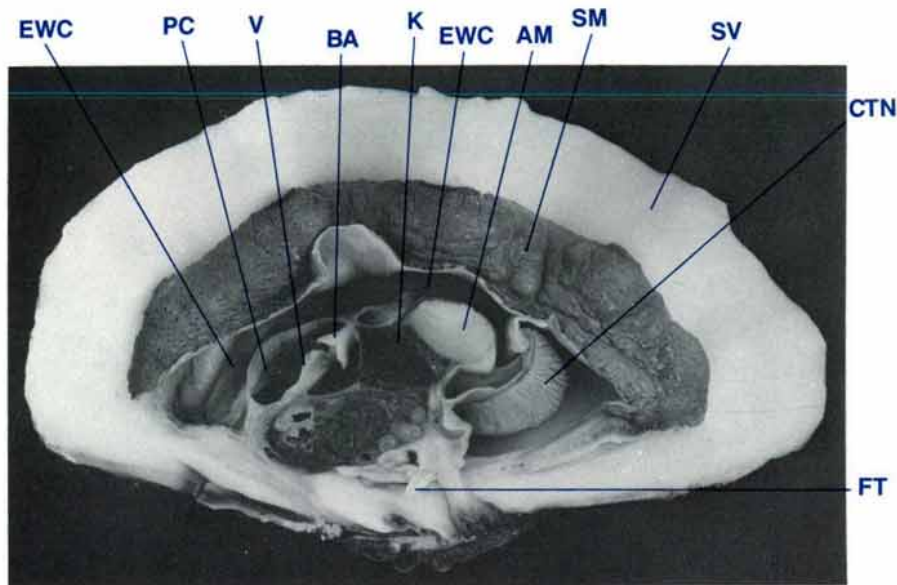


Figure 86 A mid-longitudinal section of a clam to show the pericardial chamber and heart (shell length 20 cm, $MgCl_2$ sedated, formalin fixed).

AM adductor muscle, **BA** bulbus arteriosus, **CTN** ctenidia, **EWC** excurrent water chamber, **FT** foot, **K** kidney, **PC** pericardial chamber, **SM** siphonal mantle, **SV** shell valve, **V** ventricle.

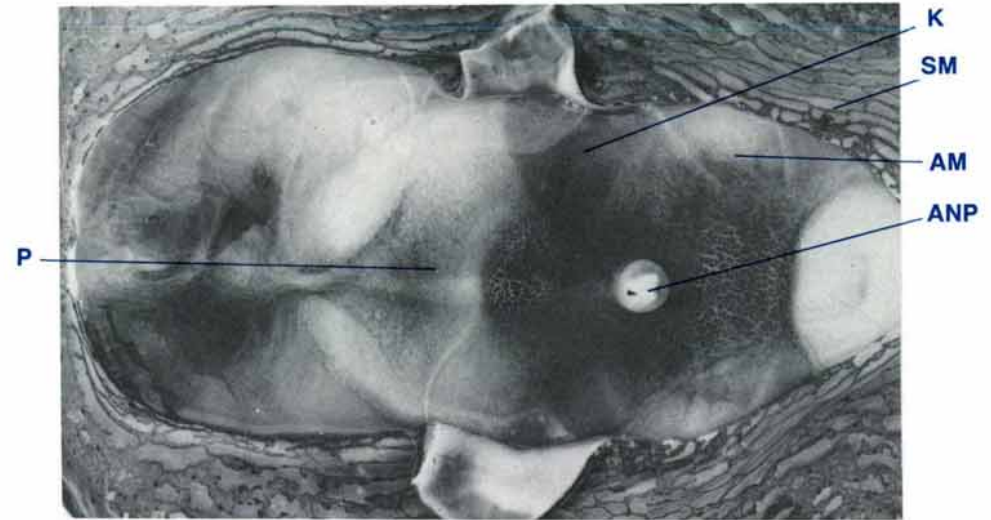


Figure 87 Dorsal view of the pericardium with the siphonal mantle cut longitudinally and reflected laterally (shell length 35 cm, $MgCl_2$ sedated).

AM adductor muscle, **ANP** anal papilla, **K** kidney, **P** pericardium, **SM** siphonal mantle.

Heart — Anatomy

The heart is enclosed by a pericardium in a pericardial chamber (Fig. 86). The pericardium is visible when the siphonal mantle is cut along the midline anterior to the excurrent siphonal orifice and the flaps of siphonal mantle are reflected laterally (Fig. 87). When the pericardium is opened by a midline incision, the heart is visible (Fig. 88).

The heart has several compartments (Fig. 88). These include two creamy-white thin-walled auricles which are situated laterally in the pericardial chamber. The centrally located ventricle is also creamy-white but has thicker walls than the auricles. Posterior to the ventricle is the brown, collar-shaped bulbus arteriosus. The heart rests on the floor of the pericardial

chamber. One-way flap valves are present between each auricle and the ventricle, between the ventricle and the anterior aorta and between the bulbus arteriosus and the posterior aorta.

Each auricle is attached to a side of the pericardial chamber (Fig. 89). The anterior ends of the efferent branchial veins drain into the auricles through orifices in the lateral pericardium. The anterior of the ventricle is attached to the floor of the pericardium via the anterior aorta and the rectum (Fig. 89). The anterior aorta is dorsal to the rectum. The bulbus arteriosus is attached to the posteriodorsal wall of the pericardium, dorsal to the kidney isthmus, via the posterior aorta and the rectum.

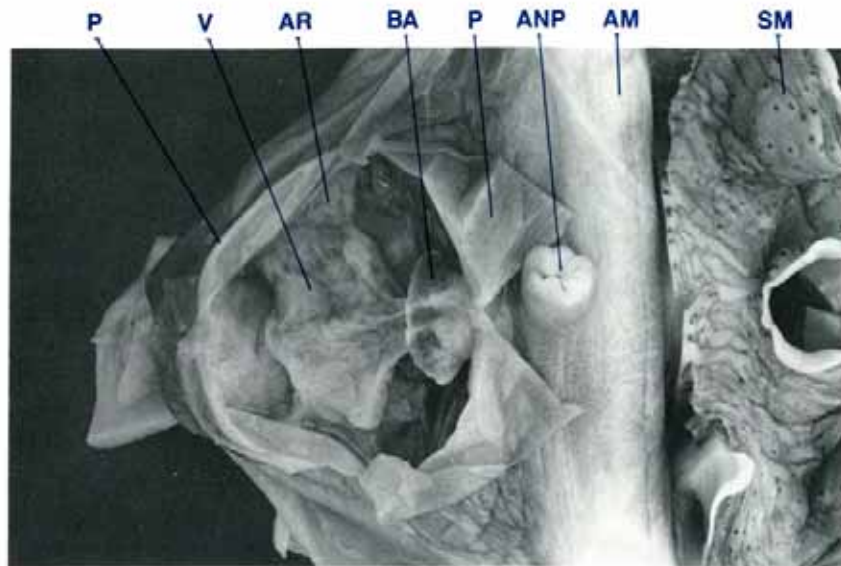


Figure 88 Dorsal view of the heart with the pericardium cut and opened (shell length 35 cm, MgCl₂ sedated, formalin fixed).

AM adductor muscle, **ANP** anal papilla, **AR** auricle, **BA** bulbus arteriosus, **P** pericardium (reflected), **SM** siphonal mantle, **V** ventricle.

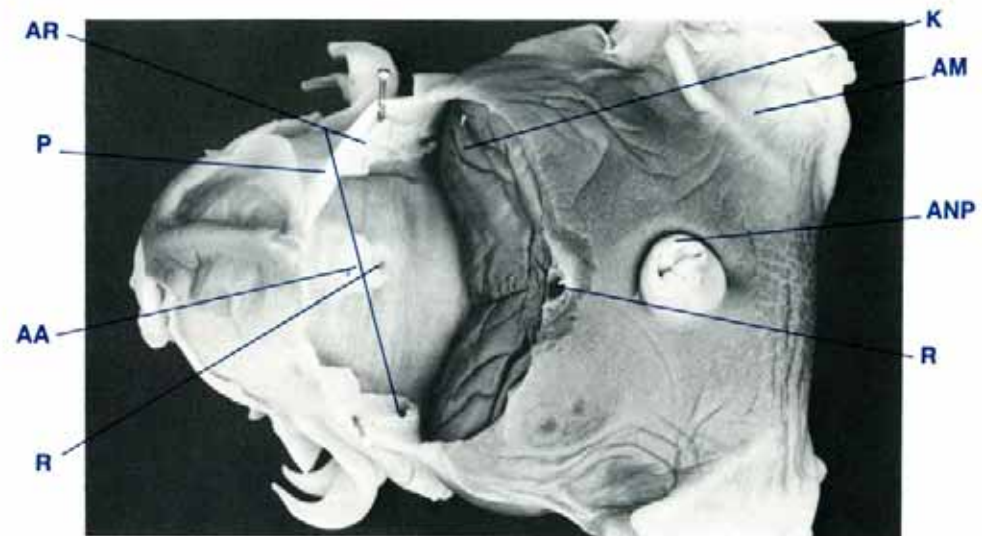


Figure 89 Dorsal view of clam with the pericardial cavity opened and the heart removed (shell length 35 cm, MgCl₂ sedated, formalin fixed).

AA anterior aorta, **AM** adductor muscle, **ANP** anal papilla, **AR** auricle, **K** kidney, **P** pericardium (edge), **R** rectum.

Pericardium — Anatomy

The pericardium is the wall which encloses the pericardial chamber on those sides of the chamber not enclosed by other organs (Figs 86, 87, 88). Anteriorly, the pericardium is attached to the dorsal aspect of the digestive mass and reproductive organ, laterally it is attached to the dorsolateral aspect of the digestive mass and reproductive organ and posteriorly, it is attached to the anterodorsal aspect of the kidney lobes.

The pericardium is surrounded by the excurrent water chamber dorsally (Fig. 86), and by the incurrent water chamber laterally.

Arterial System — Anatomy

A one-way flap valve separates the ventricle from the anterior aorta. As the anterior aorta (Fig. 90) passes through the digestive mass and reproductive organ, it branches into the visceral arteries. Anterior to the oral groove another branch turns anteriorly and travels dorsally to form the midgut arteries and the style sac artery. The byssal/pedal artery supplies the byssal and pedal organs.

The posterior aorta (Figs 90, 91) is a very short vessel which leaves the heart posterior to the bulbus arteriosus. It gives off a small dorsal vessel, the recurrent pericardial artery, before

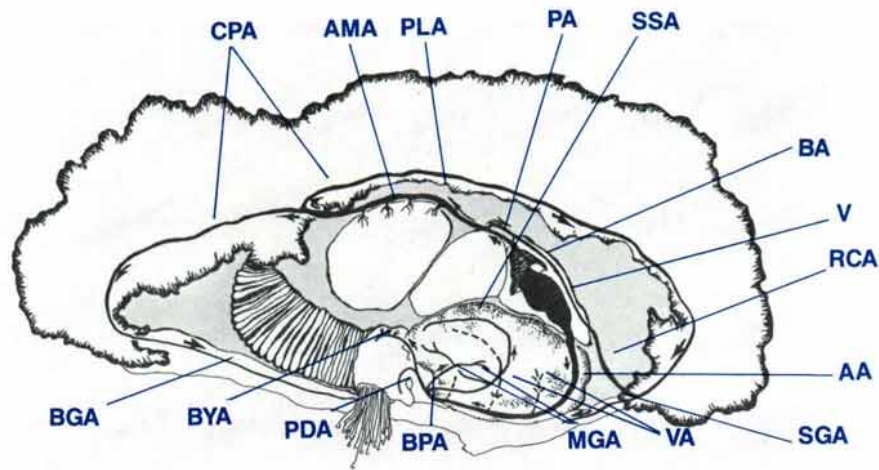


Figure 90 A diagrammatic view of a mid-longitudinal section of a clam to show the arterial system; arrows indicate direction of haemolymph flow.

AA anterior aorta, AMA adductor muscle arteries, BA bulbus arteriosus, BGA byssal gape artery, BPA byssal/pedal artery, BYA byssal gland artery, CPA circumpallial artery, MGA midgut arteries, PA posterior aorta, PDA pedal artery, PLA pallial artery, RCA recurrent pericardial artery, SGA supraligamental (hinge) gland artery, SSA style sac artery, V ventricle, VA visceral arteries.

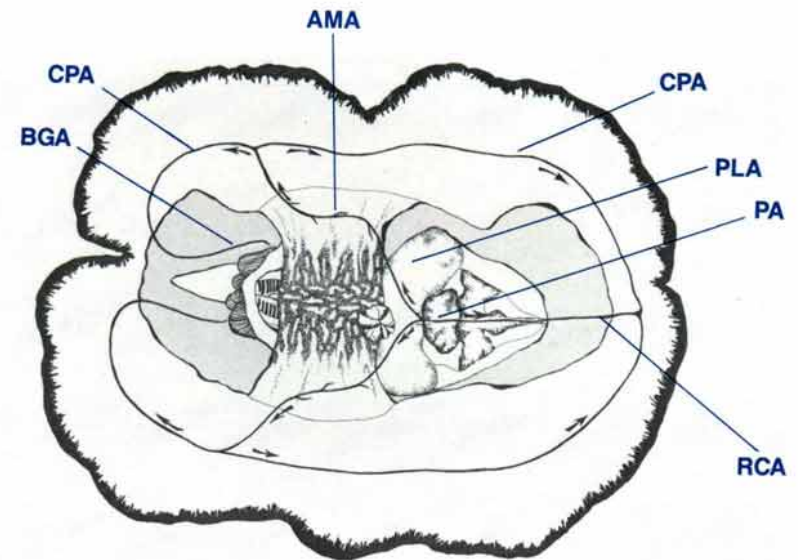


Figure 91 Dorsal diagrammatic view of a clam to show the branches of the posterior aorta; arrows indicate direction of haemolymph flow.

AMA adductor muscle arteries, BGA byssal gape artery, CPA circumpallial artery, PA posterior aorta, PLA pallial artery, RCA recurrent pericardial artery.

dividing into the two large pallial arteries, which cross the posterior dorsal surface of the kidney and then pass over the dorsal surface of the adductor muscle close to its attachment to the shell valves. As each pallial artery crosses the adductor muscle, it gives off several small adductor muscle arteries. The pallial arteries branch posterior to the ends of the adductor muscle into the circumpallial arteries. These latter arteries travel in the root of the siphonal mantle adjacent to the circumpallial vein, the pallial nerves and the zooxanthellal tube (Fig. 155). The posterior ends of the circumpallial arteries continue down around the byssal gape as the byssal gape arteries. The anterior ends of the circumpallial arteries join the anterior end of the recurrent pericardial artery prior to ending in the supraligamental (hinge) gland artery. Small radial pallial arteries leave the circumpallial arteries and travel into the siphonal mantle.

Venous System — Anatomy

The venous system consists of a number of haemolymph sinuses which occur throughout the mantle, the visceral mass, the adductor muscle and around the kidney (Fig. 92). The shape and dimensions of these sinuses may vary depending on the volume of haemolymph enclosed. These sinus systems are drained by two venous systems, namely the afferent and the efferent systems. The afferent venous system conducts haemolymph from the above organs to the ctenidia (Figs 92, 93, 94). The efferent venous system conducts haemolymph from the ctenidia to the auricles of the heart (Fig. 94).

Haemolymph from the sinuses of the siphonal mantle enters the circumpallial veins which in turn drain into the pallial veins

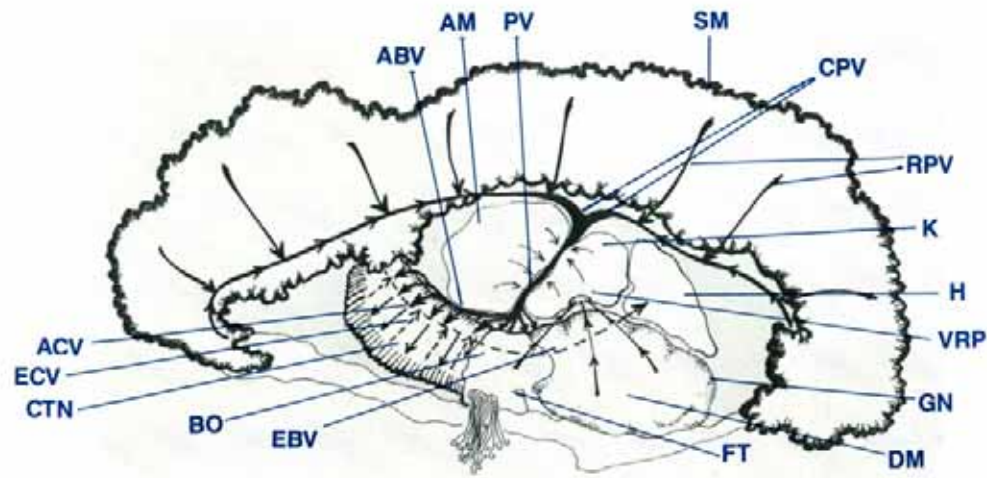


Figure 92 A diagrammatic view of a mid-longitudinal section of a clam to show the venous system; arrows indicate direction of haemolymph flow.

ABV afferent branchial vein, ACV afferent ctenidial veins, AM adductor muscle, BO byssal organ, CPV circumpallial vein, CTN ctenidia, DM digestive mass, EBV efferent branchial vein, ECV efferent ctenidial veins, FT foot, GN gonad, H heart, K kidney, PV pallial vein, RPV radial pallial veins, SM siphonal mantle, VRP visceral-renal haemolymph portal.

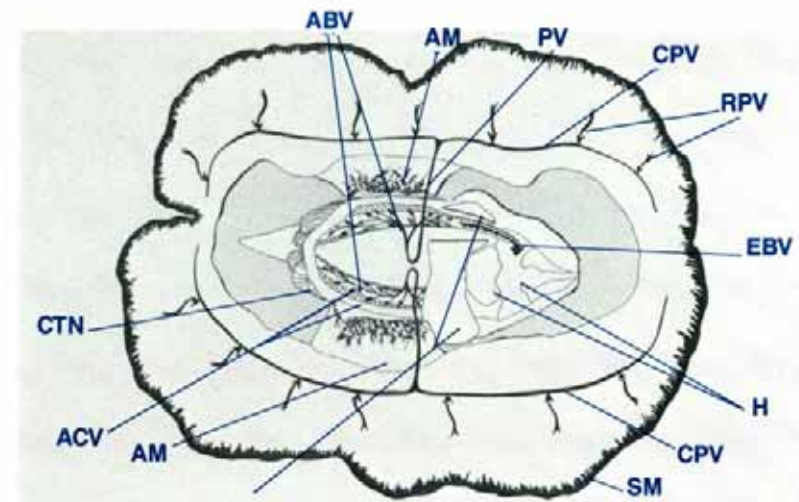


Figure 93 Dorsal diagrammatic view of the clam to show the venous system; arrows indicate direction of haemolymph flow.

ABV afferent branchial vein, ACV afferent ctenidial veins, AM adductor muscle, CPV circumpallial vein, CTN ctenidia, EBV efferent branchial vein, H heart, K kidney, PV pallial vein, RPV radial pallial veins, SM siphonal mantle.

(Fig. 92). Haemolymph from the digestive mass, the gonads, the foot and the byssal organ all appear to drain into the kidney via the paired visceral-renal haemolymph portals. Haemolymph from the kidneys and the adductor muscle also drains into the pallial veins which in turn drain into the afferent branchial veins. These large veins supply haemolymph to the numerous small afferent ctenidial veins (Figs 93, 94, 95). After diffusing across the tissues of the lamellae, the haemolymph leaves the ctenidia via the numerous small efferent ctenidial veins which drain into the large, paired efferent branchial veins. These paired veins, one on either side of the clam, drain into the auricles of the heart.

The circumpallial vein runs parallel to the pallial line in the root of the siphonal mantle, in close association with the circum-

pallial artery, the pallial nerves and branches of the zooxanthellal tube system (Fig. 155). It runs ventral to the pallial artery and crosses the end of the adductor muscle dorsally, very close to its attachment to the internal shell surface. The circumpallial veins from both sides of the clam drain into the paired pallial veins which are anterior to the adductor muscle. They lie dorsal to the posterior byssal/pedal retractor muscles and travel ventrally and medially between the kidneys and the adductor muscle, under the pallial arteries. They empty into the large, paired sets of afferent branchial veins in the middle ctenidial suspensory ligaments. Within this structure, the haemolymph is directed into numerous channels which radiate to all sections of the ctenidia. These channels direct the haemolymph into the numerous small afferent ctenidial veins of each demibranch (Fig. 94).

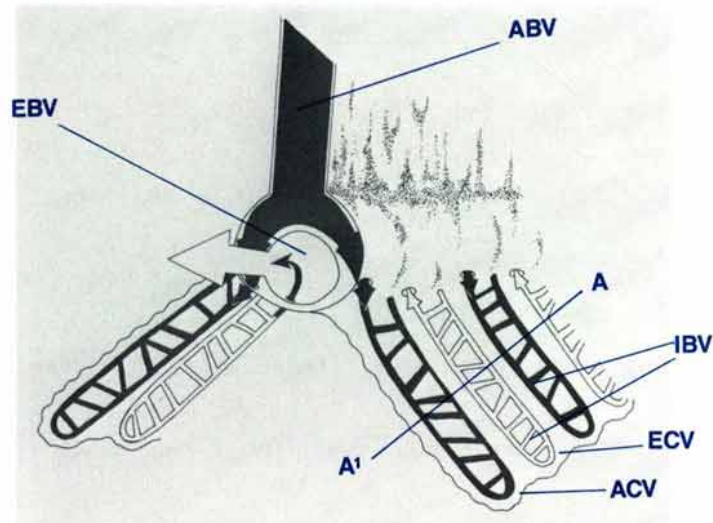


Figure 94 Three dimensional view of the vascular system of the ctenidia.

ABV afferent branchial vein, **ACV** afferent ctenidial vein, **EBV** efferent branchial vein, **ECV** efferent ctenidial vein, **IBV** interconnecting branch veins.

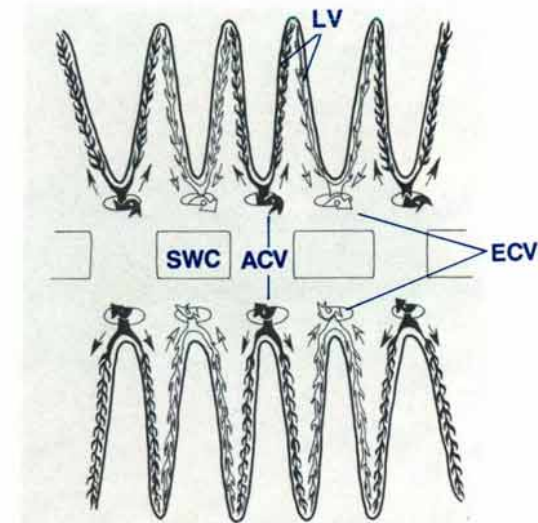


Figure 95 Diagrammatic view of a section A¹-A of a demibranch in Fig. 94 to show the vascular system (demibranch LS).

ACV afferent ctenidial veins, **ECV** efferent ctenidial veins, **LV** lamellar veins, **SWC** secondary water channel.

The channels of the afferent branchial veins cross the dorso-lateral and dorsomedial aspects of the large afferent branchial vein prior to entering the ctenidia and becoming the afferent ctenidial veins. Each small afferent ctenidial vein runs down and up the depth of each demibranch, ventrally and dorsally to the partitions which separate the secondary water channels (Fig. 95). Terminating branches from both the afferent ctenidial veins and the efferent ctenidial veins run into each lamella where there is an exchange of haemolymph. The haemolymph is removed by the small efferent ctenidial veins which run in the opposite direction. They run down and up the depth of each demibranch dorsally and ventrally to the secondary water channels. Interconnecting branch veins run between the dorsal and ventral branches of both the afferent ctenidial veins and the efferent

ctenidial veins (Fig. 94). The small efferent ctenidial veins join the large efferent branchial vein via small orifices in the latter vessel's ventro-lateral and ventro-medial surfaces (Fig. 94). The large paired efferent branchial veins empty into the auricles of the heart (Fig. 92).

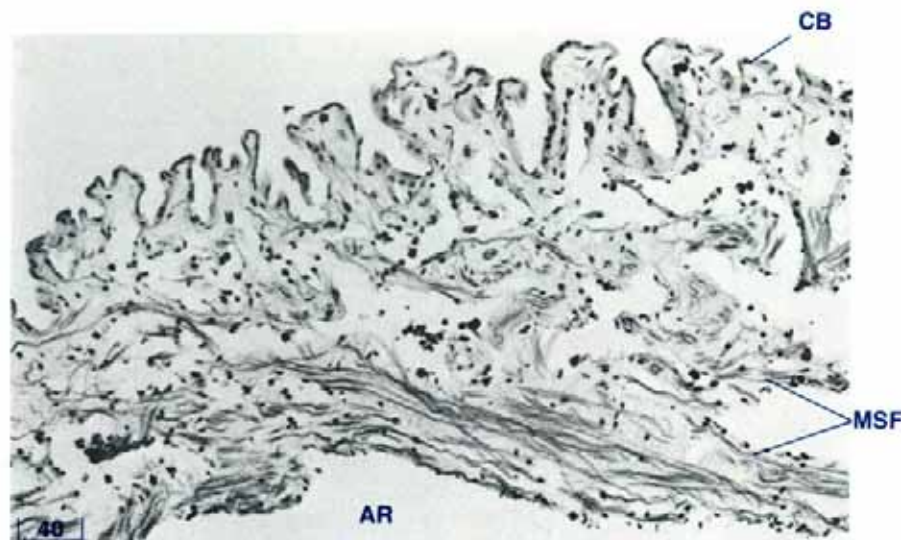


Figure 96 The wall of the auricle (TS, H & E stain, shell length 3 cm).
AR auricle, CB cuboidal epithelium, MSF muscle fibres

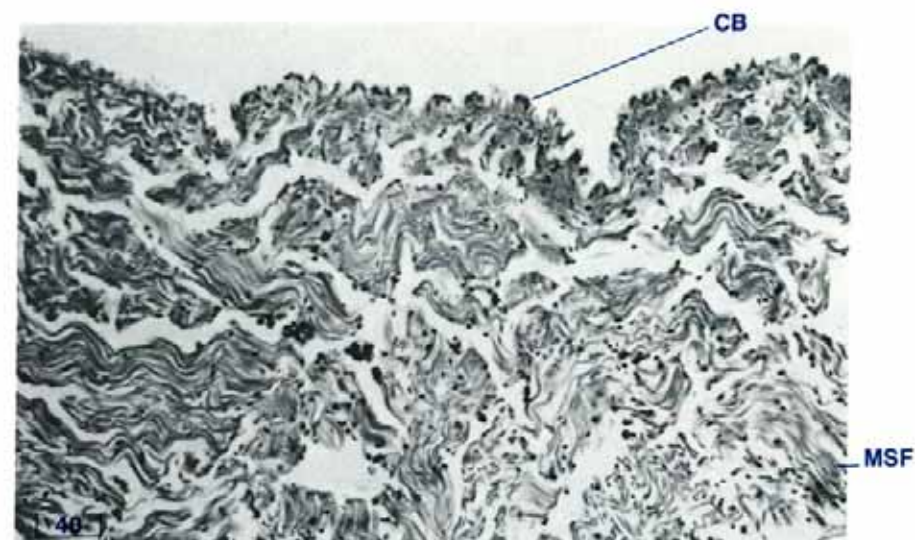


Figure 97 The wall of the ventricle (LS, H & E stain, shell length 3 cm).
CB cuboidal epithelium, MSF muscle fibres.

Heart and Haemolymph System — Histology

The auricle (Fig. 96) is composed of thin muscle fibres which run in different directions. The internal surface does not appear to have an endothelial lining. Granulocytes are scattered throughout the crevices formed by the irregular internal surface. Externally, the auricles are covered with cells which range in appearance from cuboidal-like cells with foamy cytoplasm and small dark nuclei to cells with thin cytoplasm and dark, prominent, raised nuclei.

The muscle bundles of the ventricle (Fig. 97) are much thicker than those of the auricles. Externally the ventricle is covered with cuboidal-like epithelium. Flap valves are present between the auricles and the ventricle (Fig. 98), between the ventricle and

the anterior aorta (Fig. 101), and between the bulbus arteriosus and the posterior aorta (Fig. 102). These are composed of collagen with some muscle fibres.

The bulbus arteriosus (Figs 99, 100) contains dense collagenous tissue with muscle fibres scattered randomly throughout. There are numerous haemolymph crevices throughout the organ and some of these may contain granulocytes. Groups of zooxanthellae are numerous, especially on the dorsal aspect of this organ. The bulbus arteriosus is covered with cuboidal cells with dark nuclei.

The pericardium is of collagenous connective tissue interspersed with haemolymph sinuses containing granulocytes. Zooxanthellae are also present in tubes in the connective tissue.

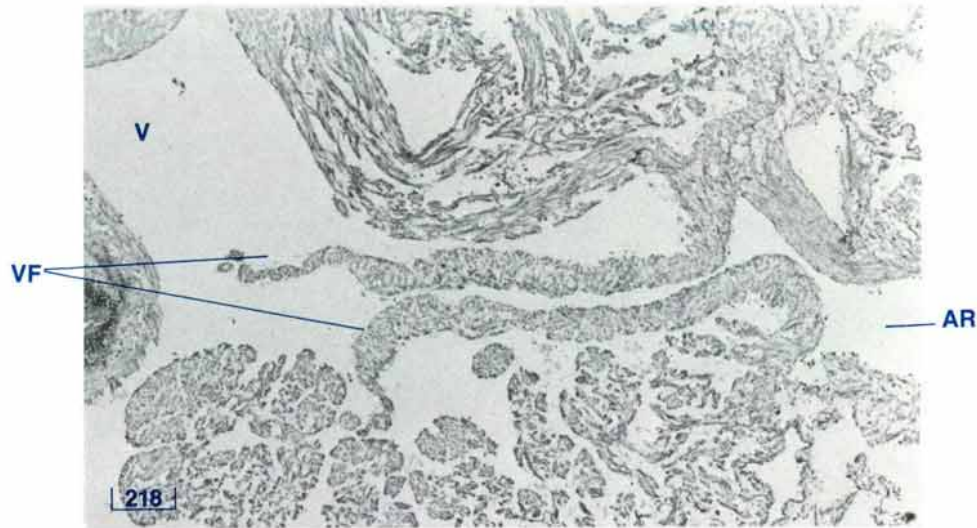


Figure 98 Auriculoventricular flap valve (TS, H & E stain, shell length 3 cm).
AR auricle, V ventricle, VF valve flaps.

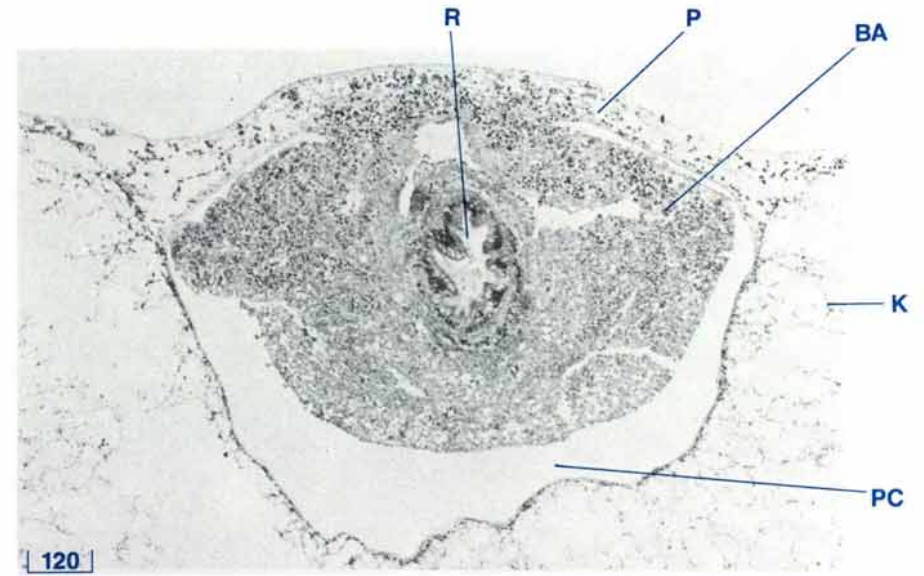


Figure 99 Bulbus arteriosus (TS, H & E stain, shell length 3 cm).
BA bulbus arteriosus, K kidney, P pericardium, PC pericardial chamber, R rectum.

The recurrent pericardial artery and nerve fibres are also present. The internal surface of the pericardium is lined with an epithelium which is either cuboidal-like or has flattened cytoplasm and prominent nuclei.

Large arteries such as the anterior aorta (Fig. 103) have an endothelial lining. The cells have flattened cytoplasm and prominent nuclei. The walls of these arteries contain collagenous connective tissue and muscle fibres. Small arteries are of similar composition. Haemolymph sinuses, which are common throughout the clam tissues, appear as open cavities of indefinite shape within a connective tissue network and do not appear to be lined with an endothelium.

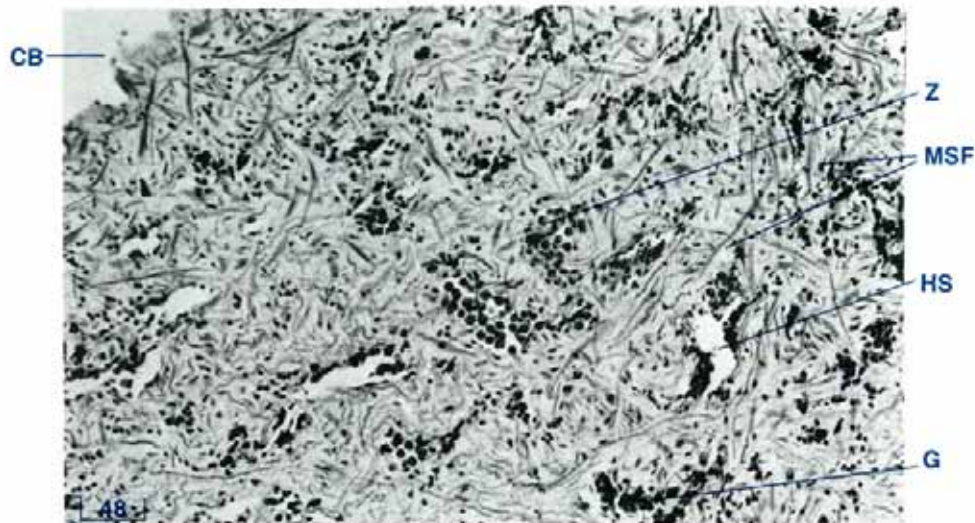


Figure 100 Bulbus arteriosus (TS, trichrome stain, shell length 3 cm).
 CB cuboidal epithelium, G granulocytes, HS haemolymph sinuses,
 MSF muscle fibres, Z zooxanthellae.

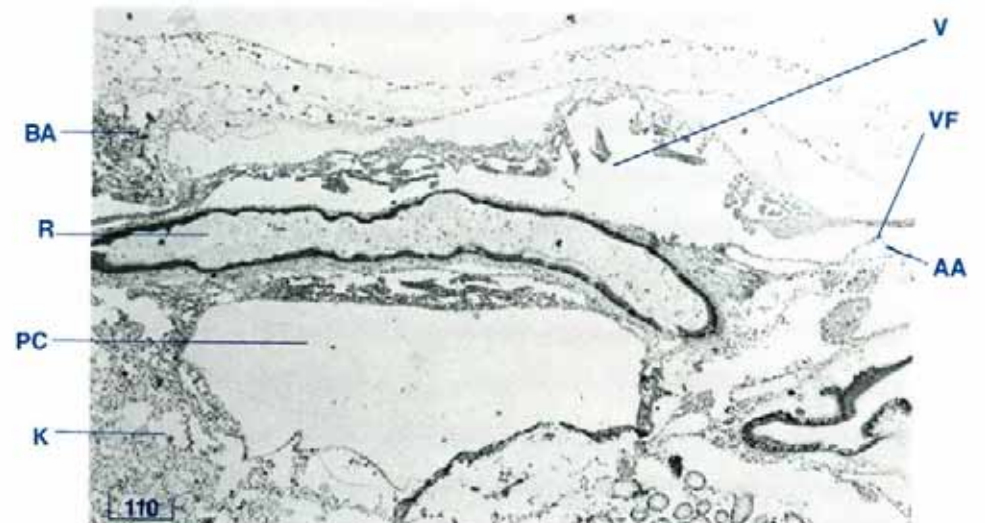


Figure 101 Heart and rectum (LS, H & E stain, shell length 3 cm).
 AA anterior aorta, BA bulbus arteriosus, K kidney, PC pericardial chamber,
 R rectum, V ventricle, VF valve flap.

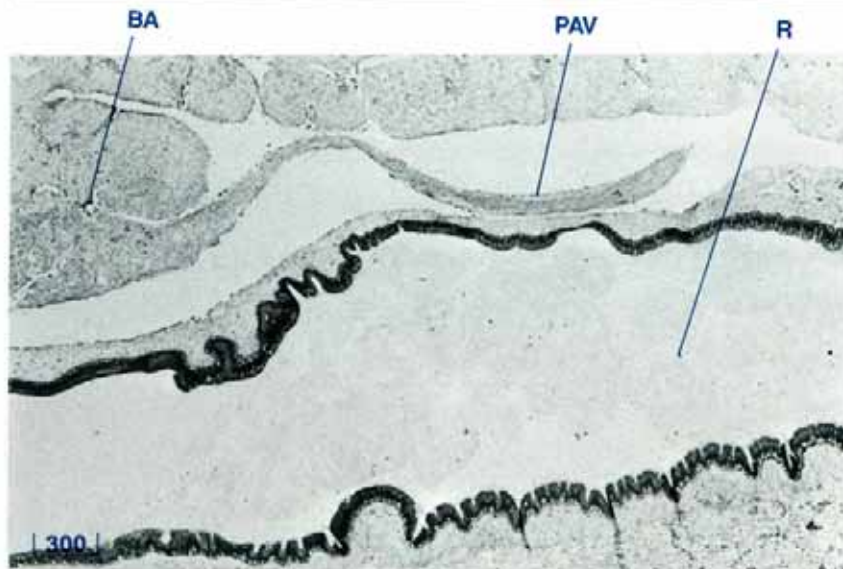


Figure 102 Mid-longitudinal section of the heart showing the bulbus arteriosus and the posterior aortic valve (LS, H & E stain, shell length 15 cm).
 BA bulbus arteriosus, PAV posterior aortic valve, R rectum.

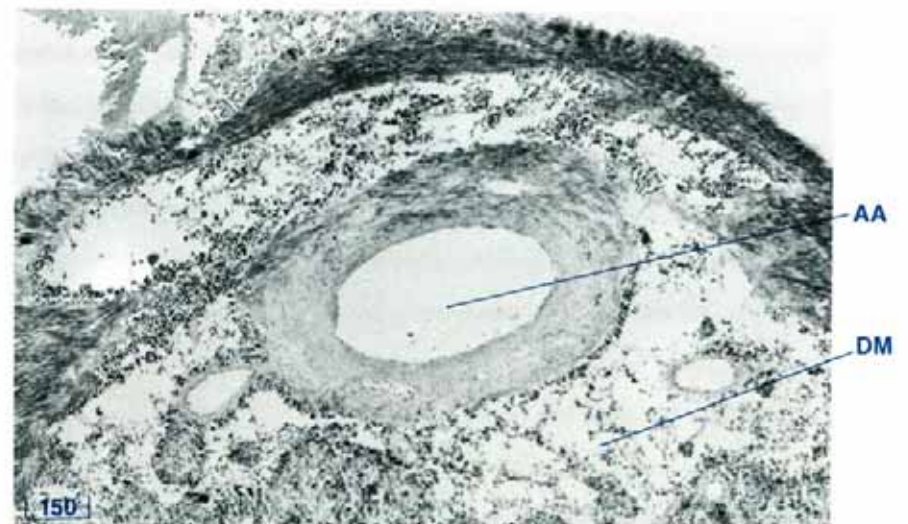


Figure 103 Anterior aorta (TS, H & E stain, shell length 10 cm).
 AA anterior aorta, DM digestive mass.



THE KIDNEY AND PERICARDIAL GLAND

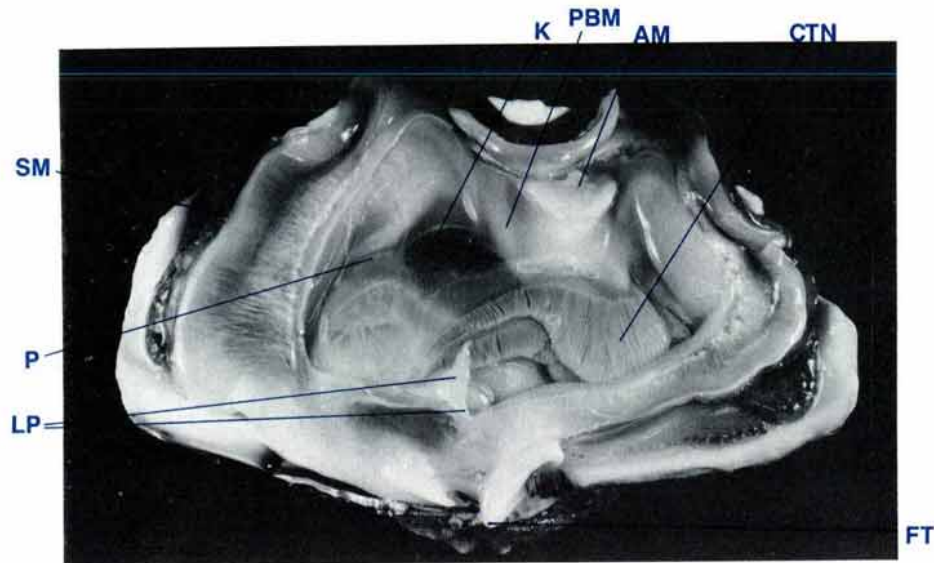


Figure 104 Lateral view of the clam with shell valve and lateral mantle removed to show the kidney (shell length 35 cm, MgCl₂ sedated).

AM adductor muscle, CTN ctenidia, FT foot, K kidney, LP labial palps, P pericardium, PBM posterior byssal/pedal retractor muscle, SM siphonal mantle.

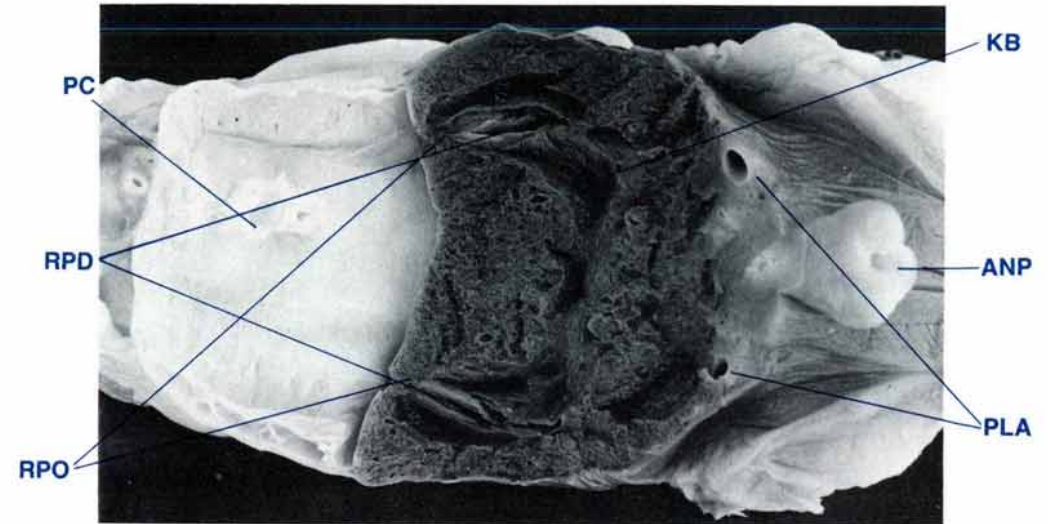


Figure 105 Dorsal view of horizontal section of kidney to show renopericardial ducts and kidney bladder (shell length 35 cm, MgCl₂ sedated, formalin fixed).

ANP anal papilla, KB kidney bladder, PC pericardial chamber, PLA pallial arteries, RPD renopericardial duct, RPO renopericardial orifice.

Kidney — Anatomy

The kidneys (nephridia or organs of Bojanus) consist of two large, soft, dark mahogany-red, spherical lobes connected by a narrow isthmus of similar tissue (Figs 104, 86, 89). Internally a single large cavity, the kidney bladder, occupies the central area of each kidney and the isthmus (Fig. 105).

Paired renopericardial orifices (or nephrostomes) (Fig. 105) are located antero-ventrally towards the sides of the kidney lobes. These orifices lead into the yellow/ochre, longitudinally folded, renopericardial ducts. In the floor of the kidneys, beneath the renal parenchyme, there are two prominent orifices, the visceral-renal haemolymph portals (Fig. 107). The paired

renal excretory ducts (nephridiopores) are situated in the antero-lateral aspect of each kidney lobe, not far from the renopericardial ducts, above the ctenidia (Fig. 106). The renal excretory orifices are very small and inconspicuous. The renal excretory ducts empty into the anterior region of the inner suprabranchial compartments of the excurrent water chamber between the middle and inner ctenidial suspensory ligaments on either side of the clam.

The kidneys are attached to the postero-dorsal surface of the digestive mass and reproductive organ, to the anterior surface of the adductor muscle, to the anterodorsal surfaces of the byssal/pedal retractor muscles and to the posterior of the heart and pericardial cavity (Fig. 138). Anteriorly, the kidneys adjoin

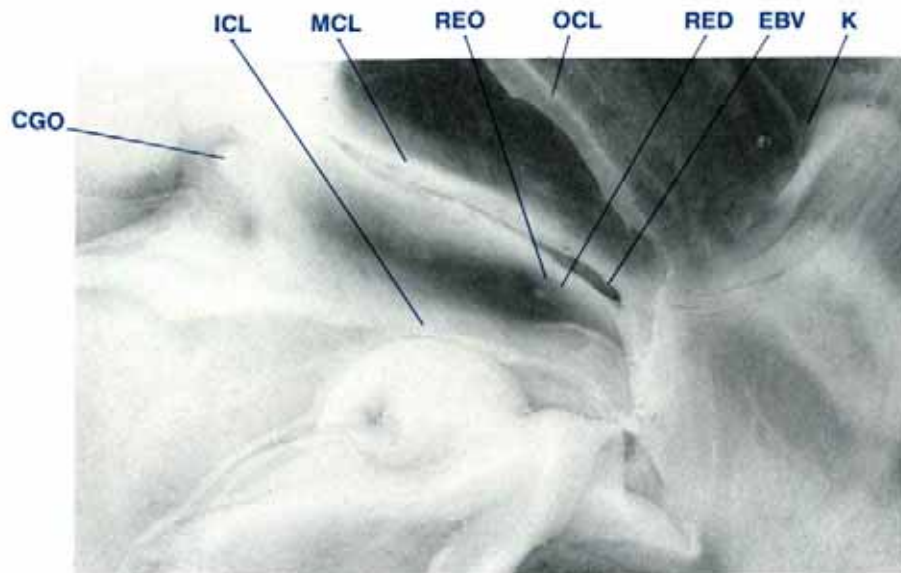


Figure 106 Lateral view of clam to show the very small renal excretory duct and orifice; ctenidia removed (shell length 35 cm, MgCl₂ sedated).

CGO common genital orifice, EBV efferent branchial vein, ICL inner ctenidial suspensory ligament, K kidney, MCL middle ctenidial suspensory ligament, OCL outer ctenidial suspensory ligament, RED renal excretory duct, REO renal excretory orifice.

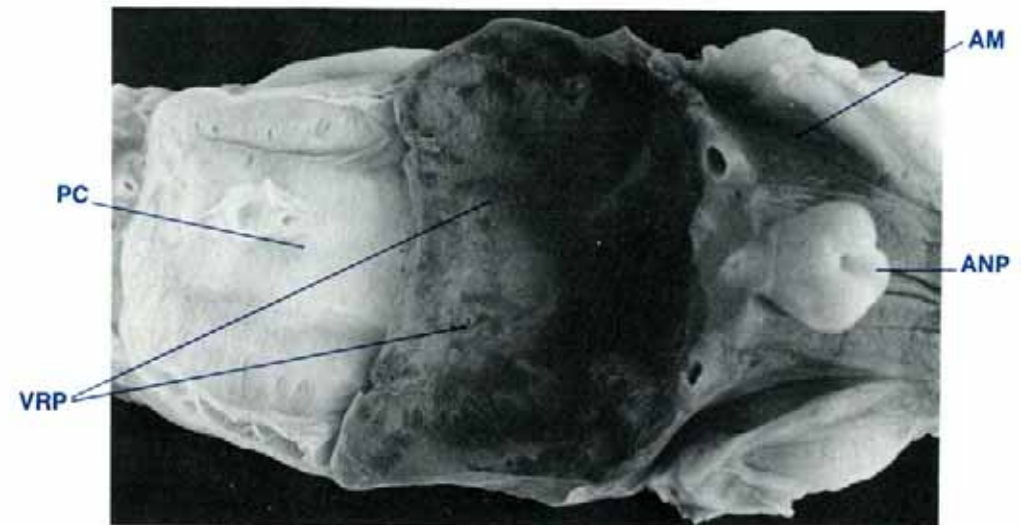


Figure 107 Dorsal view of clam with kidneys removed to show visceral-renal haemolymph portals (shell length 30 cm, MgCl₂ sedated).

AM adductor muscle, ANP anal papilla, PC pericardial chamber, VRP visceral-renal haemolymph portals.

the rear of the pericardial cavity. Laterally the kidneys are bounded by the suprabranchial compartment of the excurrent water chamber, by the upper and middle branchial suspensory membranes and by the incurrent water chamber. Dorsally, the kidneys are bounded by the excurrent water chamber. Posteriorly, the kidneys are bounded by the adductor muscle and the posterior byssal/pedal retractor muscles.

Pericardial Gland — Anatomy

The pericardial glands (Kerber's glands) occur at two locations, on the pericardium lateral to the auricles of the heart and in the antero-ventral portions of the adjoining lateral mantle. These latter glands are pale yellow to orange-brown in colour in a freshly opened clam. The two glandular areas join each other and are termed the mantle pericardial gland (Figs 108, 109) and the auricular pericardial gland (Fig. 109).

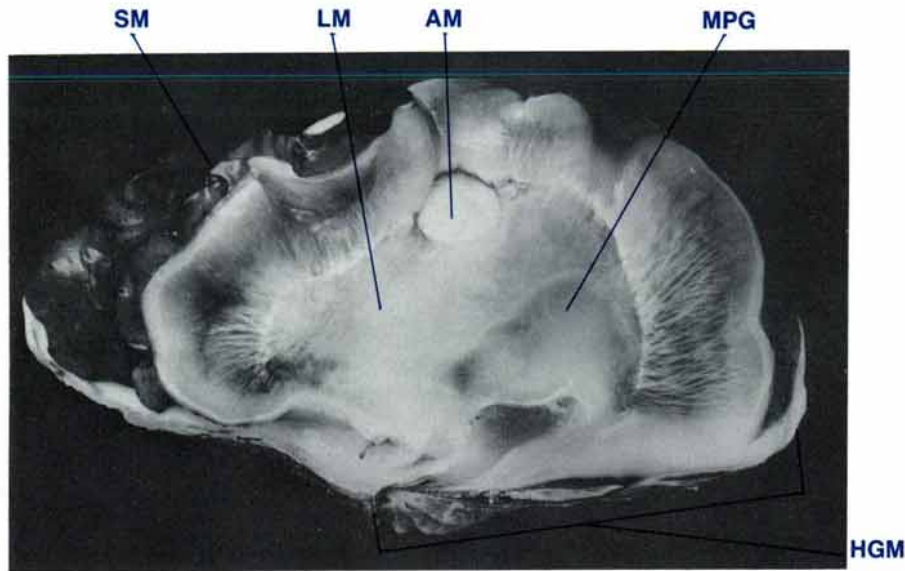


Figure 108 Lateral view of clam to show the mantle pericardial gland (shell length 35 cm, MgCl₂ sedated).

AM adductor muscle, **HGM** hinge margin, **LM** lateral mantle, **MPG** mantle pericardial gland, **SM** siphonal mantle.

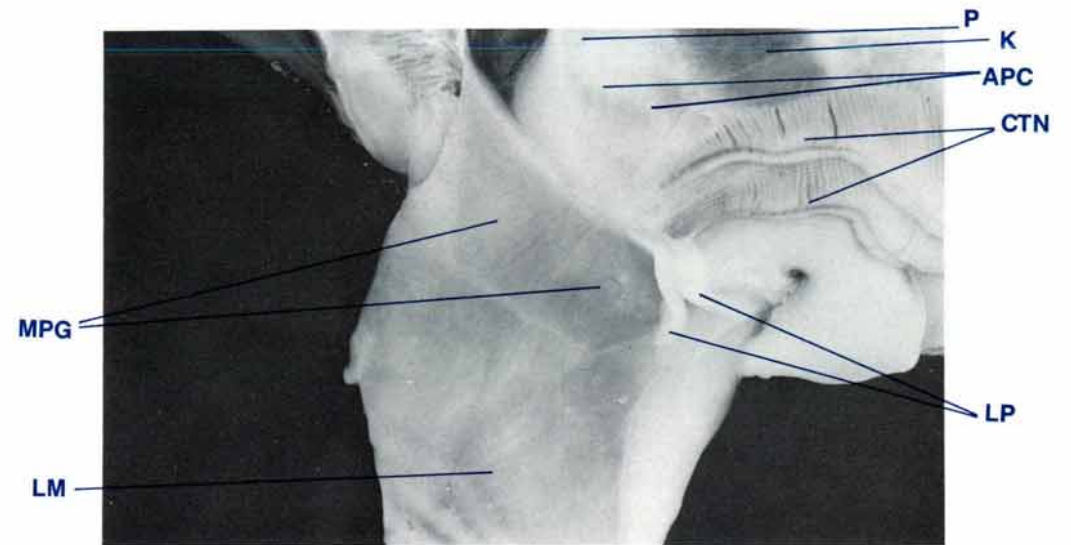

Figure 109 Lateral view of clam to show the two pericardial glands; lateral mantle cut and reflected (shell length 35 cm, MgCl₂ sedated.).

APC auricular pericardial gland, **CTN** ctenidia, **K** kidney, **LM** lateral mantle, **LP** labial palps, **MPG** mantle pericardial gland, **P** pericardium.

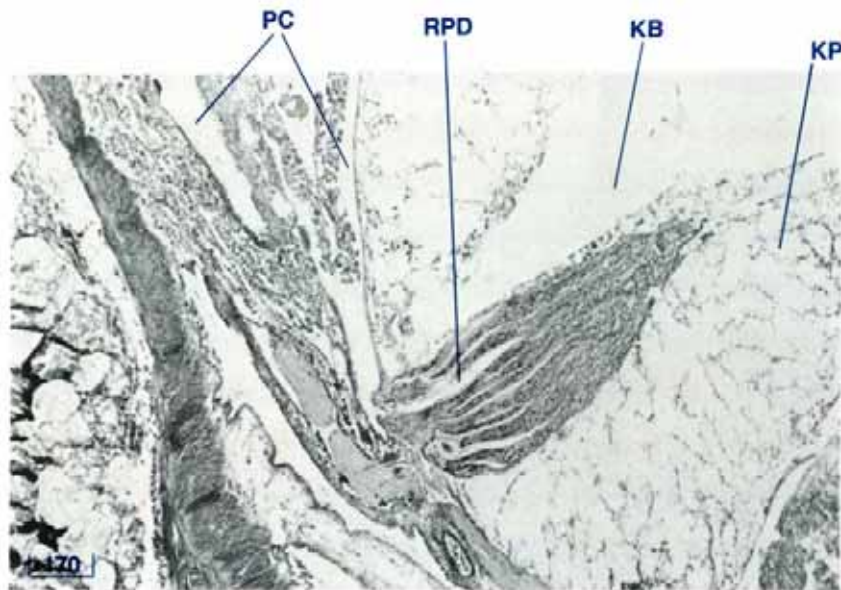


Figure 110 Kidney showing the renopericardial duct (LS, H & E stain, shell length 3cm).

KB kidney bladder, KP kidney parenchyme, PC pericardial chamber, RPD renopericardial ducts.

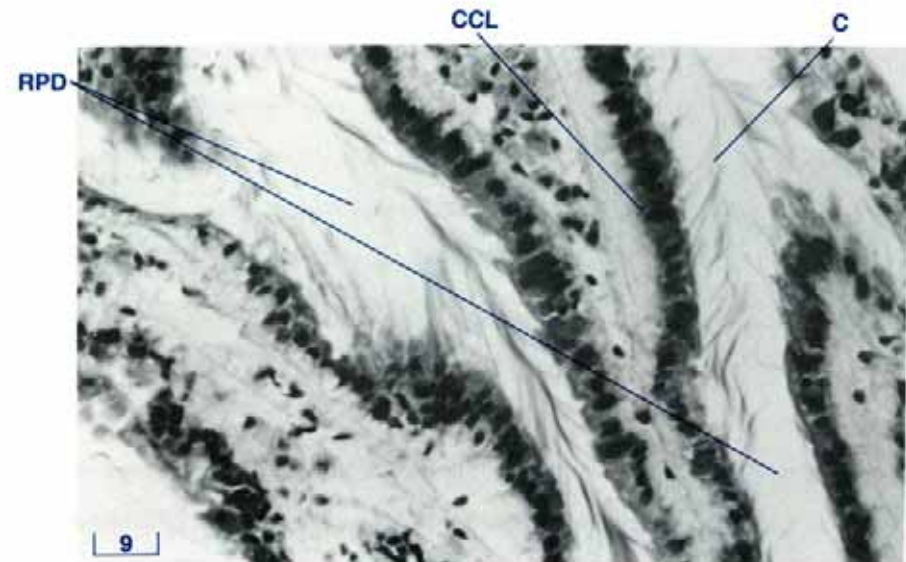

Figure 111 Renopericardial ducts (LS, H & E stain, shell length 4 cm). C cilia, CCL ciliated columnar epithelium, RPD renopericardial duct.

Kidney — Histology

The kidneys are enclosed by a sheath of collagenous connective tissue which contains small muscle fibres, haemolymph sinuses with scattered granulocytes and parts of the zooxanthellal tube system. This connective tissue is covered with a layer of ciliated cuboidal epithelium. Subepithelial type 3 mucin (see page 132) glands are also present.

The renopericardial duct (the proximal limb of the kidney), is lined with rows of columnar epithelium with long cilia (Figs 110, 111, 112). The boundary of each cell is indistinct and the nuclei are large and moderately dark in colour. The renal excretory duct is lined with ciliated cuboidal epithelium (Fig. 116).

Internally, the kidney (the distal limb of the kidney) has a tubular structure and is composed of large globular cells, the nephrocytes (Fig. 114). These cells have indistinct boundaries, and little visible cytoplasmic contents. Large spherical concretions, the nephroliths are conspicuous in these cells. They have concentric laminae and contain both type 2 and type 3 mucins (see page 132) as well as calcium. The nephrocytes are situated adjacent to haemolymph sinuses and their apical cytoplasm is adjacent to excretory ducts or tubules. The nuclei of the nephrocytes are small and dark, if they are visible at all. The nephrocytes form a mass of irregular tubules which empty into a central cavity, the kidney bladder (Figs 113, 115). This cavity and many of the large ducts entering into it are lined with ciliated cuboidal epithelium with dark nuclei and little cytoplasm (Fig. 115).

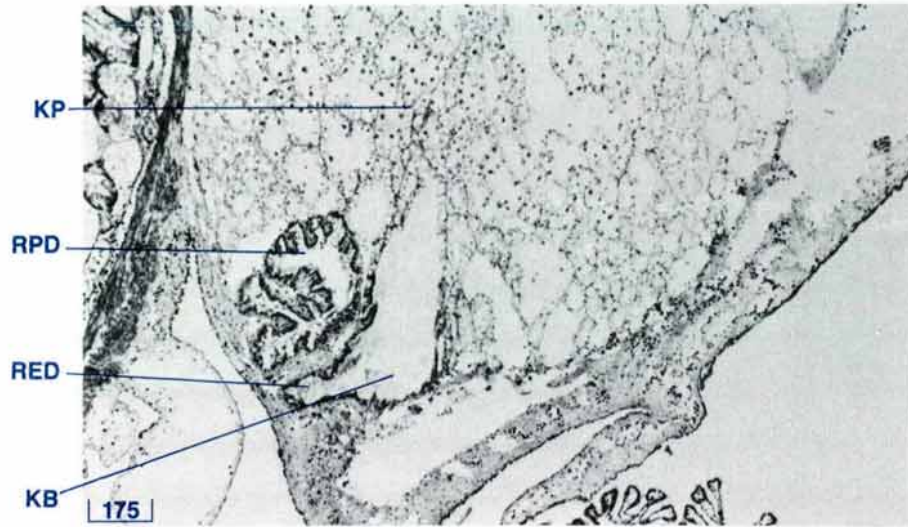


Figure 112 Kidney showing the renopericardial duct, kidney bladder and renal excretory duct (TS, H & E stain, shell length 6 cm).

KB kidney bladder, **KP** kidney parenchyme, **RED** renal excretory duct, **RPD** renopericardial duct.

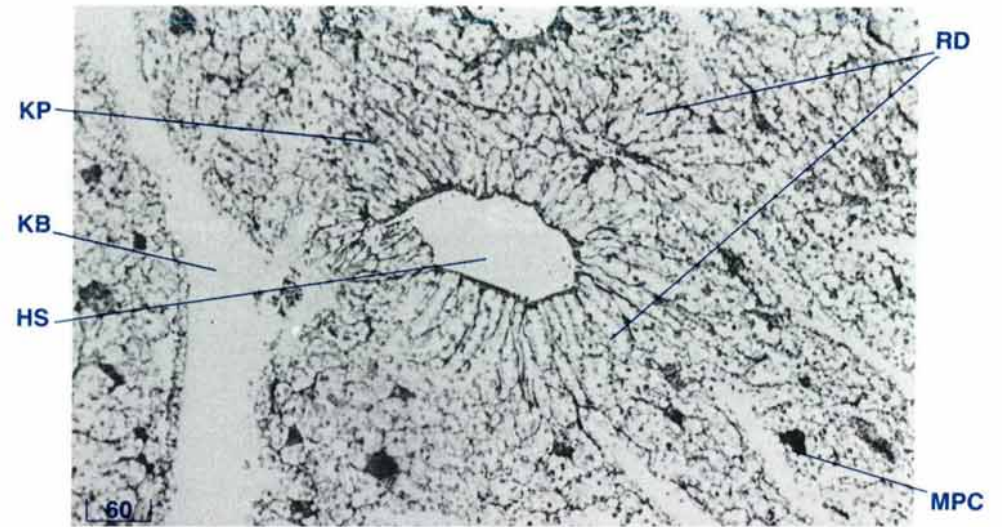


Figure 113 Kidney showing haemolymph sinus and kidney bladder (TS, H & E stain, shell length 14 cm).

HS haemolymph sinus, **KB** kidney bladder, **KP** kidney parenchyme, **MPC** macrophage centre, **RD** renal ducts.

Haemolymph vessels are present throughout the kidney tissue (Fig. 113). The visceral-renal haemolymph portals (Fig. 117) permit haemolymph to flow from the digestive, reproductive and byssal organs into the kidneys.

There are macrophage centres throughout the kidney tissue (Fig. 113) and within haemolymph spaces. The macrophages in these centres have small dark nuclei and cytoplasm with an indistinct border, and may contain amorphous debris. Granulocytes may also be present throughout the kidney.

Pericardial Gland — Histology

The pericardial gland tissue consists of large cells with irregular-shaped borders and with cytoplasm rich in granules (Figs 118, 119). These cells are rich in type 2 mucins (see page 132) and are attached to a connective tissue network to form a lobular structure.

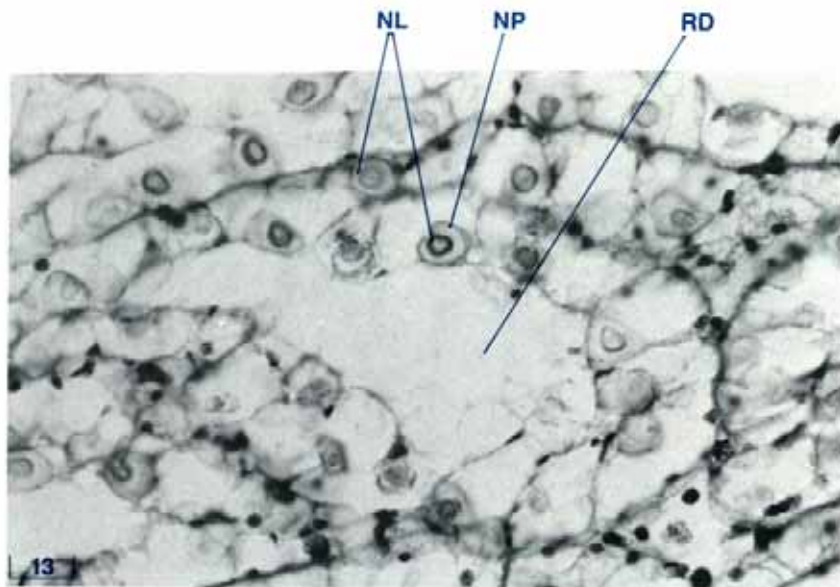


Figure 114 Kidney tubule showing the 2 zones of the nephroliths or kidney concretions (TS, H & E stain, shell length 8 cm).
 NL nephroliths, NP nephrocyte, RD renal duct.

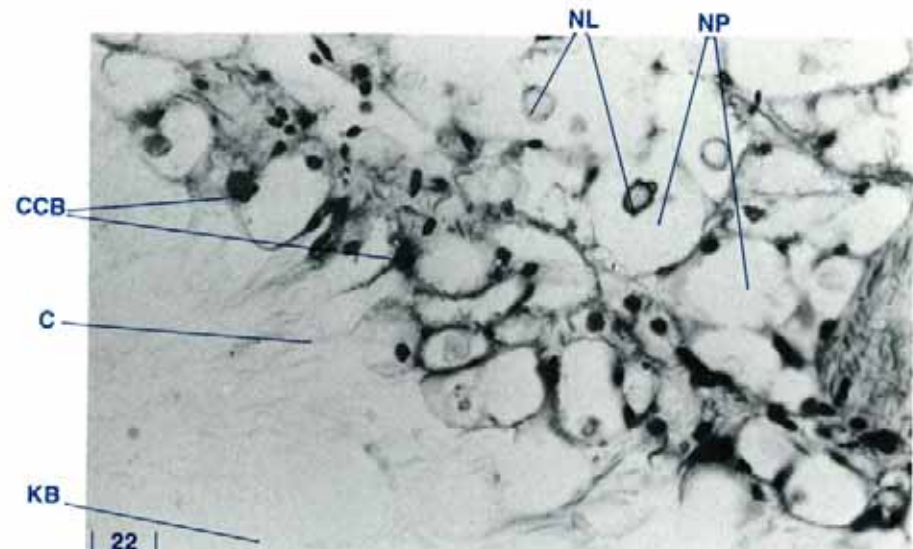


Figure 115 The ciliated cells lining the kidney bladder (TS, H & E stain, shell length 14 cm).
 C cilia, CCB ciliated cuboidal epithelium, KB kidney bladder, NL nephroliths, NP nephrocytes.

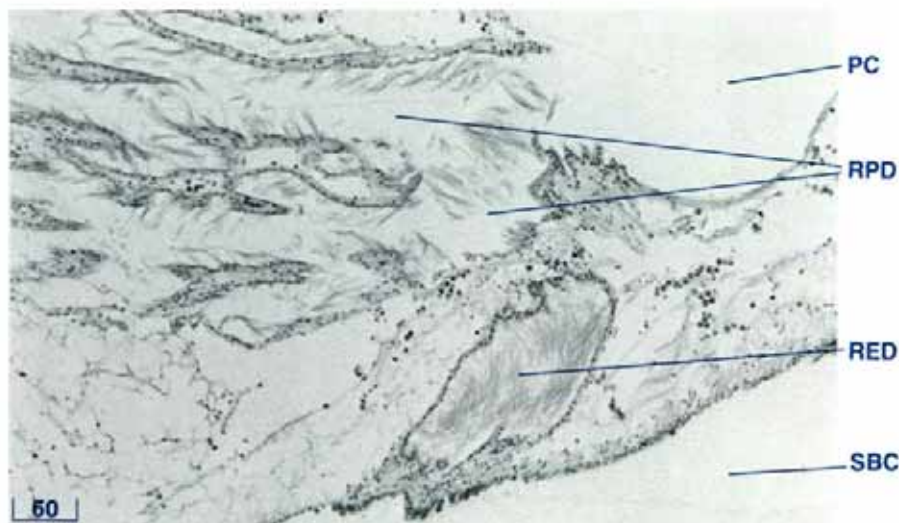


Figure 116 Renopericardial and excretory ducts (LS, H & E stain, shell length 3 cm).
 PC pericardial chamber, RED renal excretory duct, RPD renopericardial duct, SBC suprabranchial water compartment (below the kidney).

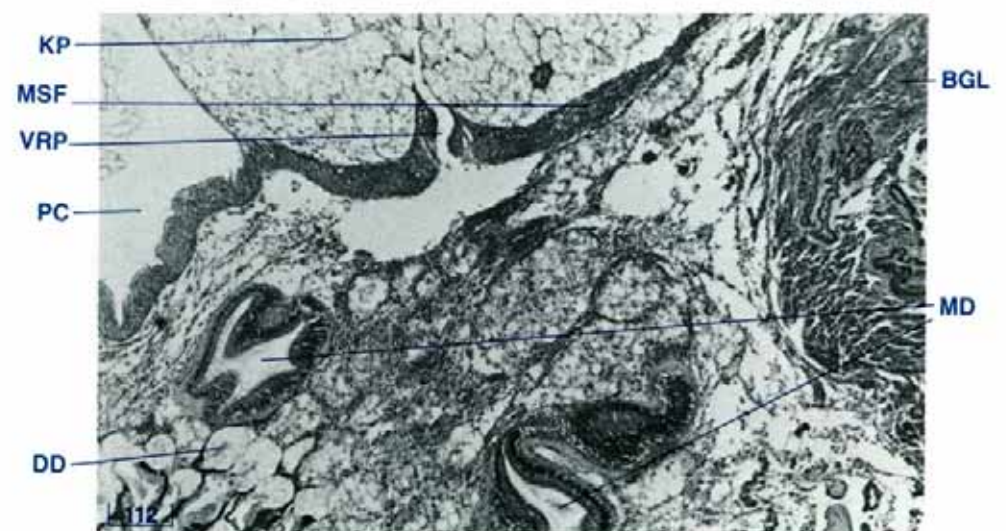


Figure 117 Visceral-renal haemolymph portal between the kidney and the digestive mass (LS, H & E stain, shell length 3 cm).
 BGL byssal gland, DD digestive diverticula, KP kidney parenchyme, MD midgut, MSF muscle fibres, PC pericardial chamber, VRP visceral-renal haemolymph portal.

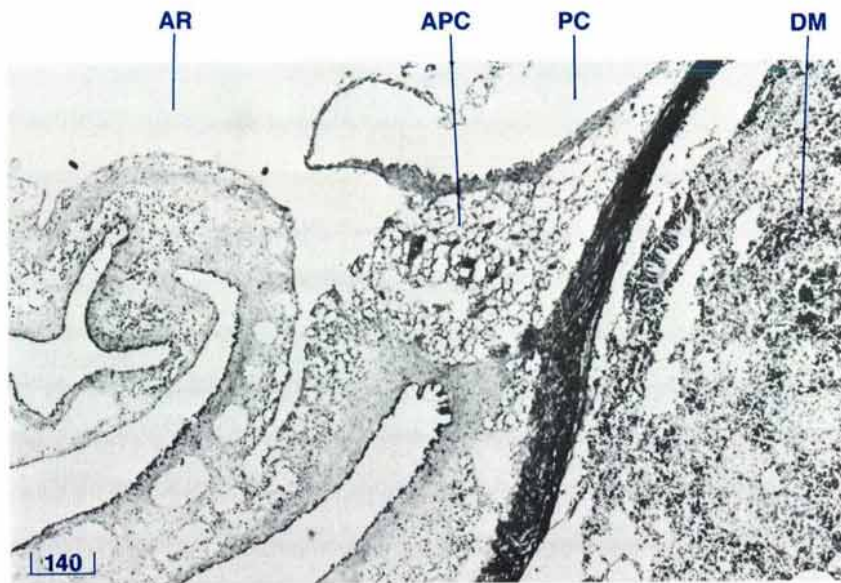


Figure 118 The auricular pericardial gland (TS, H & E stain, shell length 6 cm).
APC auricular pericardial gland, **AR** auricle, **DM** digestive mass, **PC** pericardial chamber.

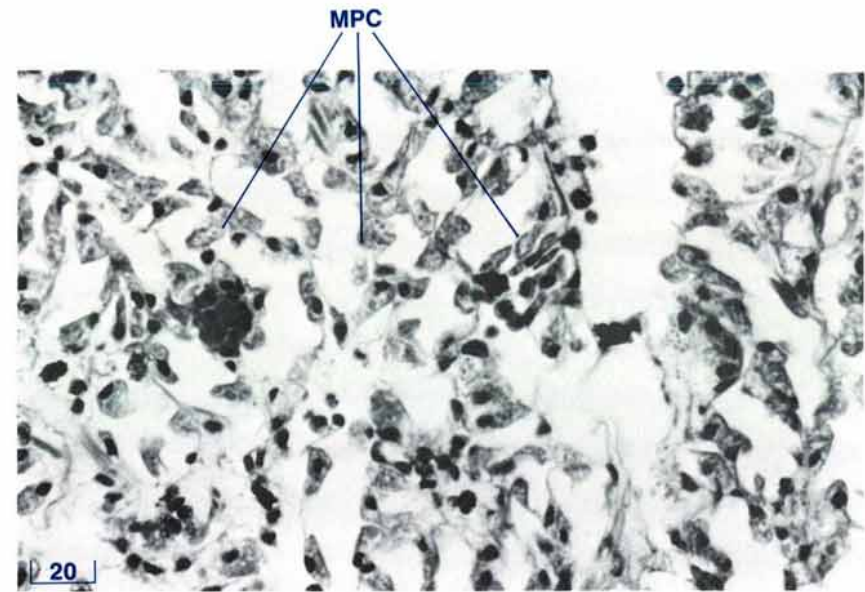



Figure 119 The mantle pericardial gland (TS, H & E stain, shell length 21 cm).
MPG mantle pericardial gland cells.





**THE NERVOUS SYSTEM,
THE HYALINE ORGANS
AND THE STATOCYSTS**

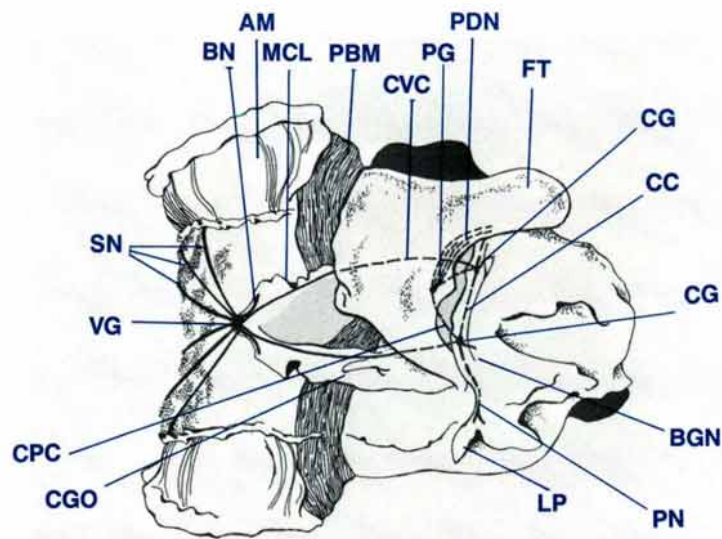


Figure 120 Ventral diagrammatic view of the visceral mass with ctenidia removed, showing the nervous system.

AM adductor muscle, **BN** branchial nerve, **BGN** byssal gape nerve, **CC** cerebral commissure, **CG** cerebral ganglia, **CGO** common genital orifice, **CPC** cerebropedal connective, **CVC** cerebrovisceral connective, **FT** foot, **LP** labial palps, **MCL** middle ctenidial suspensory ligament, **PBM** posterior byssal-pedal retractor muscle, **PDN** pedal nerves, **PG** pedal ganglia, **PN** palp nerve, **SN** siphonal nerves, **VG** visceral ganglion.

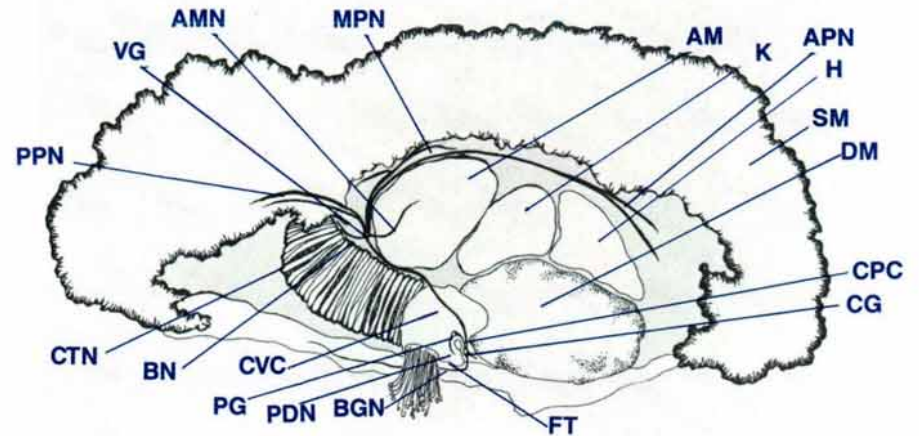


Figure 121 A diagrammatic view of a mid-longitudinal section of a clam showing the nervous system, branching nerves in siphonal mantle not shown.

AM adductor muscle, **AMN** adductor muscle nerve, **APN** anterior pallial nerve, **BGN** byssal-gape nerve, **BN** branchial nerve, **CG** cerebral ganglion, **CPC** cerebropedal connective, **CTN** ctenidia, **CVC** cerebrovisceral connective, **DM** digestive mass, **FT** foot, **H** heart, **K** kidney, **MPN** middle pallial nerve, **PG** pedal ganglion, **PDN** pedal nerves, **PPN** posterior pallial nerve, **SM** siphonal mantle, **VG** visceral ganglion.

Nervous System — Anatomy

The nervous system consists of three sets of ganglia, the cerebral, the visceral and the pedal ganglia which interconnect by a series of nerve tracts to innervate the organs of the clam (Figs 120, 121). There is no brain in any bivalved mollusc.

Each of the paired cerebral ganglia is situated anterior to the oral groove between the muscular wall of the digestive mass and the labial palps (Figs 120, 121, 123, 124). These ganglia are connected to each other by the cerebral commissure which runs ventral to the oesophagus but dorsal to the mantle isthmus and supraligamental or hinge gland (Fig. 123). Large paired nerve tracts, the cerebrovisceral connectives, join the cerebral ganglia to the single large visceral ganglion (Figs 120, 121, 124, 127).

These nerves travel inside the muscular wall of the digestive mass and reproductive organ and inside the fibrous wall of the kidney. They follow a patch medial to the common genital duct (Figs 120, 143), in the connective tissue external to the byssal/pedal retractor muscle between the middle and inner branchial suspensory ligaments (Fig. 153). Finally they travel in the connective tissue lining on the ventral surface of the adductor muscle to reach the visceral ganglion on the postero-ventral aspect of that muscle (Fig. 127). Other nerves originating from the cerebral ganglia (Figs 121, 124) include the palp nerve to the labial palps and the byssal/gape nerve which supplies tissues around the byssal gape.

The cerebral ganglia are also the origin of additional nerve tracts, the cerebropedal connectives, which run from the paired

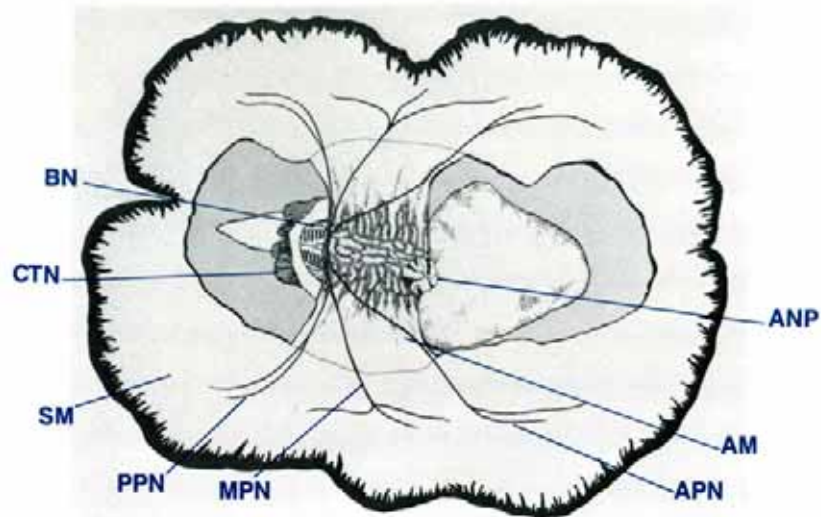


Figure 122 Dorsal view of a clam showing nerves originating from the visceral ganglion, branching nerves in siphonal mantle not shown.

AM adductor muscle, ANP anal papilla, APN anterior pallial nerve, BN branchial nerve, CTN ctenidia, MPN middle pallial nerve, PPN posterior pallial nerve, SM siphonal mantle.

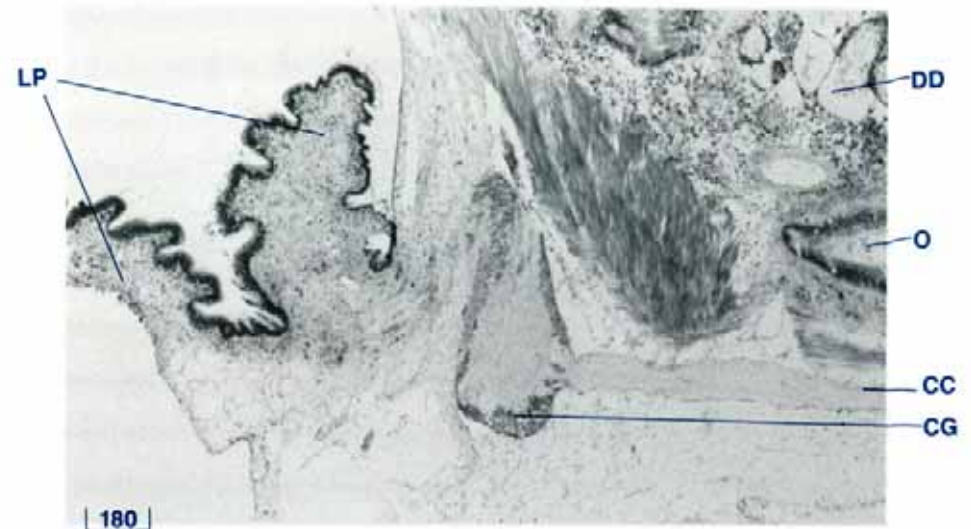


Figure 123 Cerebral ganglion and the cerebral commissure (TS, H & E stain, shell length 5 cm).

CC cerebral commissure, CG cerebral ganglion, DD digestive diverticula, LP labial palps, O oesophagus.

cerebral ganglia to the paired pedal ganglia (Figs 120, 121). From the pedal ganglia, four pedal nerves run into the foot between the byssal canal and the muscular wall in the anterior of the byssal organ and foot (Figs 120, 126).

The large single visceral ganglion which is seen as a protruberance on the postero-ventral side of the adductor muscle (Figs 38, 127) has other branches in addition to the cerebro-visceral connectives. These include the anterior, middle and posterior pallial nerves (Figs 121, 122, 155), the branchial nerves (Figs 121, 122, 128) and one or more nerves to the adductor muscle (Figs 121, 127).

The anterior pallial nerve runs around the posterior and dorsal surfaces of the adductor muscle, and forward along a fold of

tissue on the lateral wall of the excurrent water chamber to innervate the area anterior to the excurrent siphonal orifice (Figs 121, 122). The middle pallial nerve travels a similar path, just postero-lateral to the above nerve, to innervate the area posterior to the excurrent siphonal orifice. The posterior pallial nerve travels up the rear of the adductor muscle and then backward through the outer ctenidial suspensory ligament to innervate the area of the siphonal mantle around the incurrent orifice. The pallial nerves branch into the mantle folds. They are especially to be seen in the large inner fold of the siphonal mantle. Numerous ganglia are associated with these nerves (Fig. 129). The pallial nerves run along in the root of the siphonal mantle in close association with the circumpallial artery, the circumpallial vein and the main branches of the zooxanthellal tube system (Fig. 155). The branchial nerve runs along the top

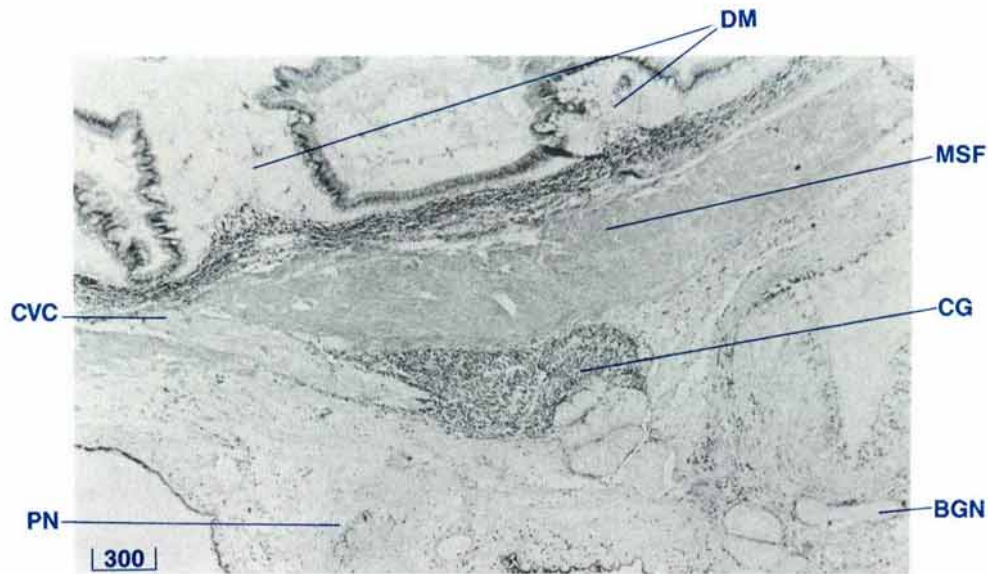


Figure 124 Cerebral ganglion, cerebrovisceral connective, palp nerve and the byssal gape nerve (LS, H & E stain, shell length 10 cm).

BGN byssal gape nerve, CVC cerebrovisceral connective, CG cerebral ganglion, DM digestive mass, MSF muscle fibres, PN palp nerve.

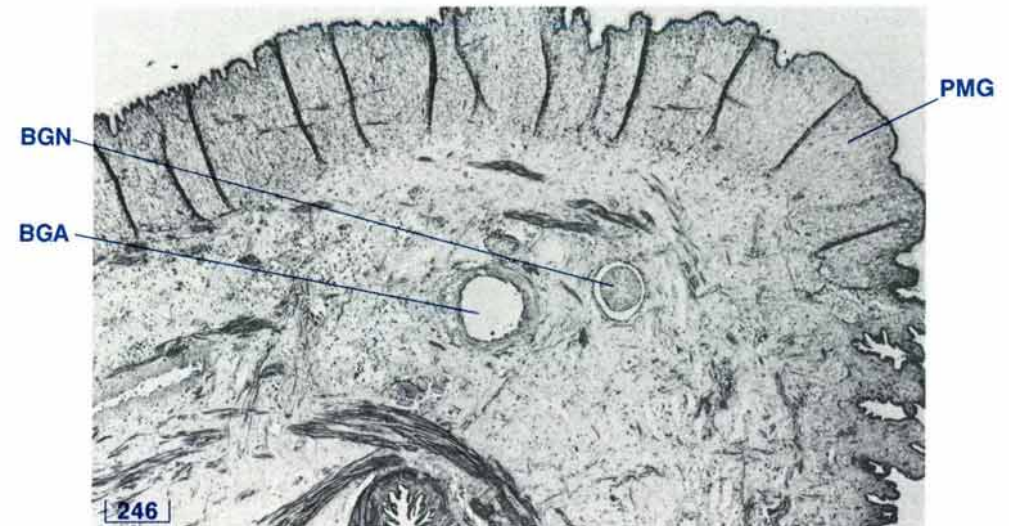

Figure 125 Section of the root of the byssal-gape edge of the lateral mantle showing the byssal-gape nerve (TS, H & E stain, shell length 20 cm).

BGA byssal-gape artery, BGN byssal-gape nerve, PMG pallial mucous gland.

of the middle ctenidial suspensory ligament to innervate the ctenidia. The nerves to the adductor muscle run from the visceral ganglion directly into that muscle.

Hyaline Organs (eyes) — Anatomy

The hyaline organs or 'eyes' of *T. gigas* are situated mainly adjacent to the margins of the siphonal mantle. In large clams they are also found scattered over non-marginal positions of the siphonal mantle and especially around the edges of the siphonal orifices. The hyaline organs are surrounded by green/blue circles (Figs 130, 131).

Statocysts — Anatomy

A pair of statocysts is located anterodorsal to the pedal ganglia and dorsal to the cerebropedal connective (Fig. 132).

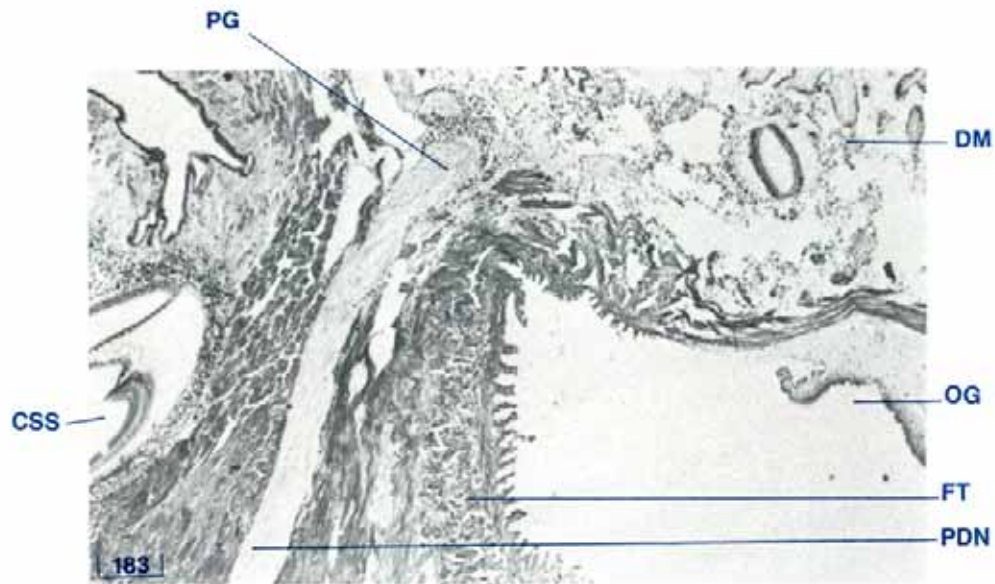


Figure 126 Pedal ganglion and pedal nerve (LS, H & E stain, shell length 5 cm).

CSS crystalline style sac, DM digestive mass, FT foot, OG oral groove, PG pedal ganglion, PDN pedal nerve.

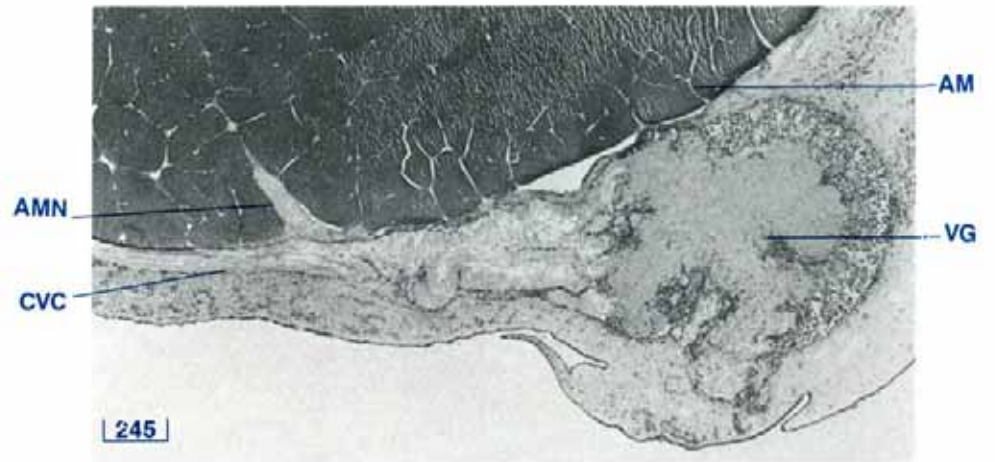


Figure 127 Visceral ganglion and adductor muscle nerve (adductor muscle TS, H & E stain, shell length 10 cm).

AM adductor muscle, AMN adductor-muscle nerve, CVC cerebrovisceral connective, VG visceral ganglion.

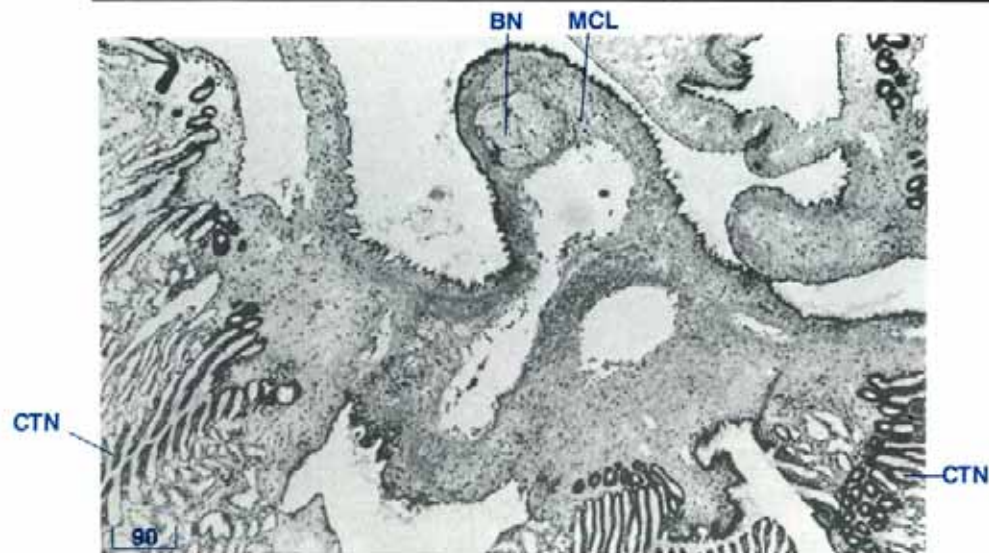


Figure 128 Branchial nerve in the middle ctenidial suspensory ligament (TS, H & E stain, shell length 5 cm).

BN branchial nerve, CTN ctenidia, MCL middle ctenidial suspensory ligament.

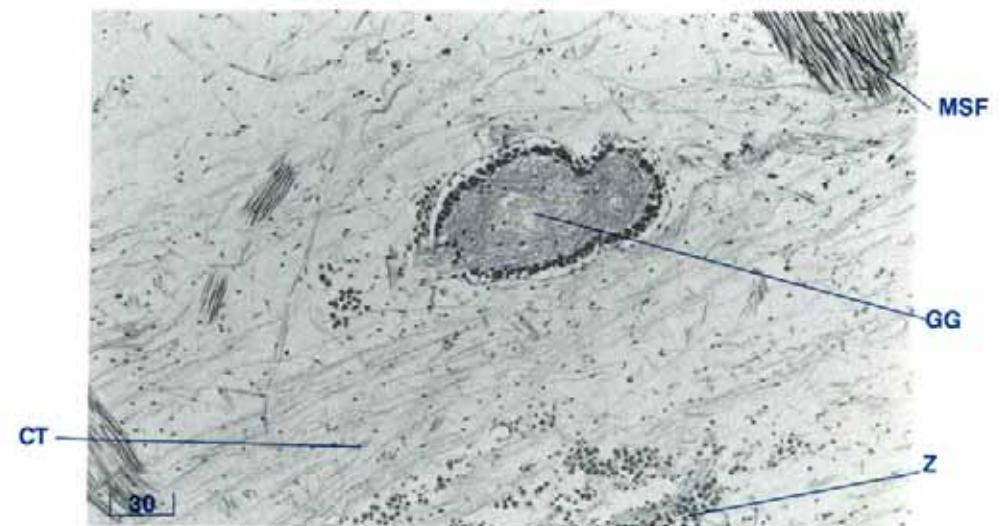


Figure 129 Ganglion in one of the nerves in the inner fold of the siphonal mantle (LS, H & E stain, shell length 14 cm).

CT connective tissue, GG ganglion, MSF muscle fibres, Z zooxanthellae.

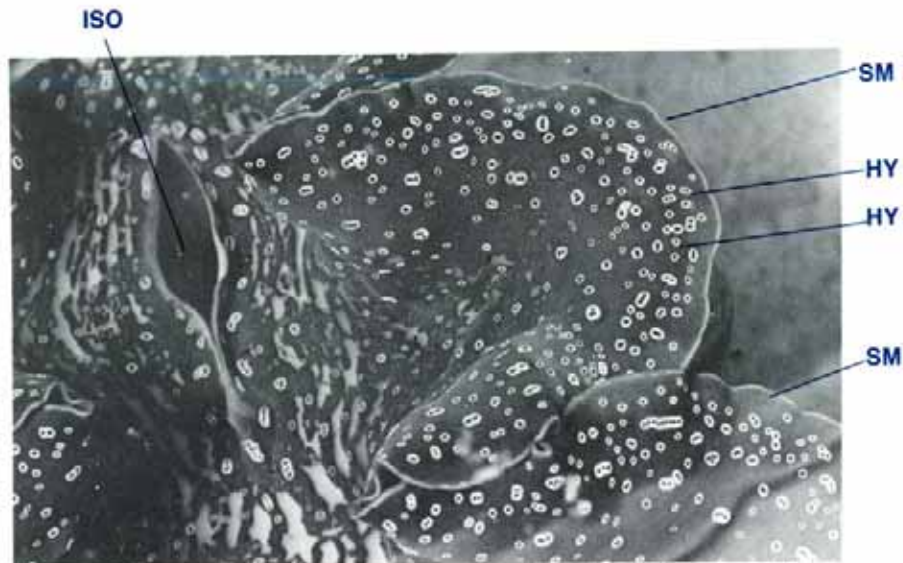

Figure 130 The hyaline organs or 'eyes' in the edge of the inner fold of the siphonal mantle (TS, H & E stain, shell length 35 cm).
 HY hyaline organ, ISO incurrent siphonal orifice, SM siphonal mantle.

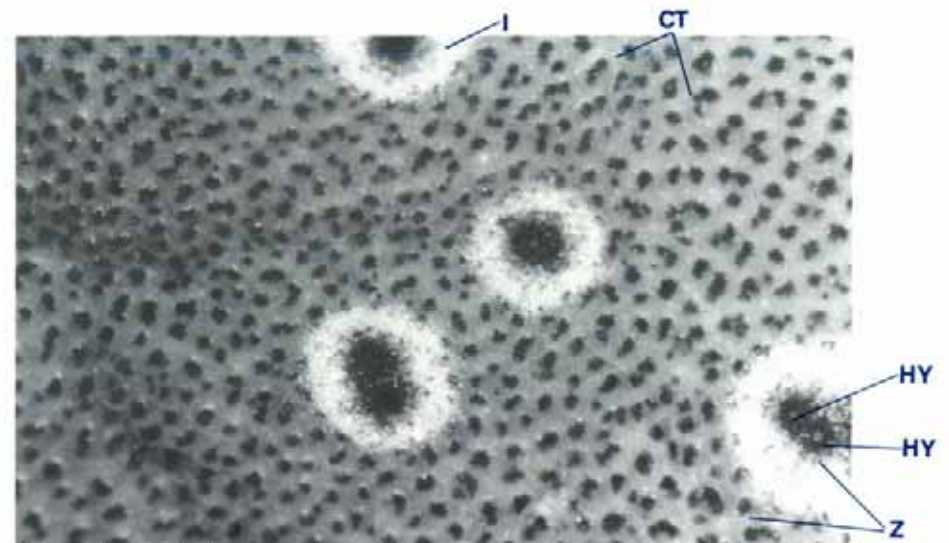


Figure 131 A close-up view of the surface of the siphonal mantle to show the hyaline organs, the zooxanthellae, and the circles of iridophores (shell length 35 cm).
 CT connective tissue, HY hyaline organ, I iridophores, Z zooxanthellae.

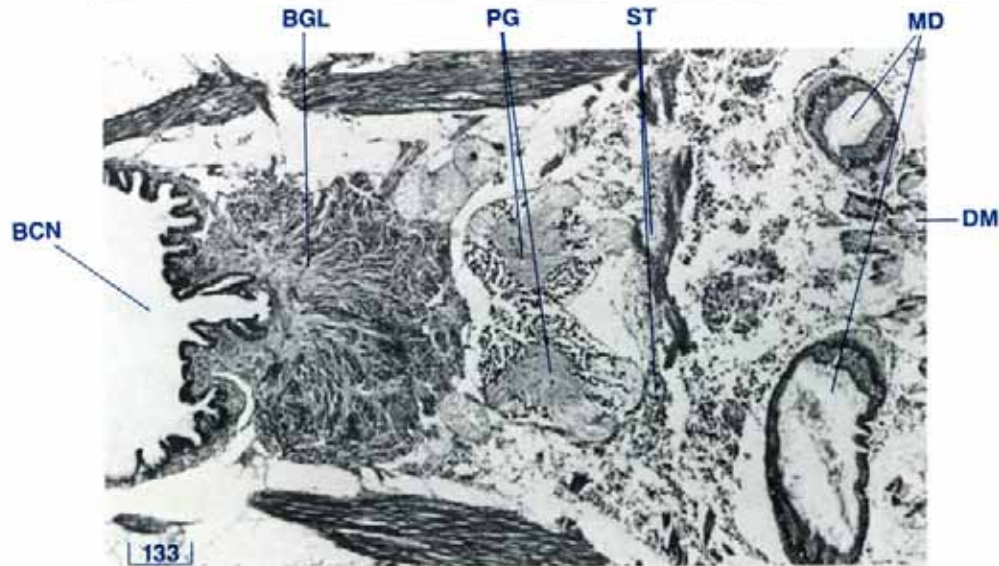


Figure 132 The paired statocysts adjacent to the paired pedal ganglia (HS, H & E Stain, shell length 8 cm).
 BCN byssal canal, BGL byssal gland, DM digestive mass, MD midgut, PG pedal ganglia, ST statocysts.

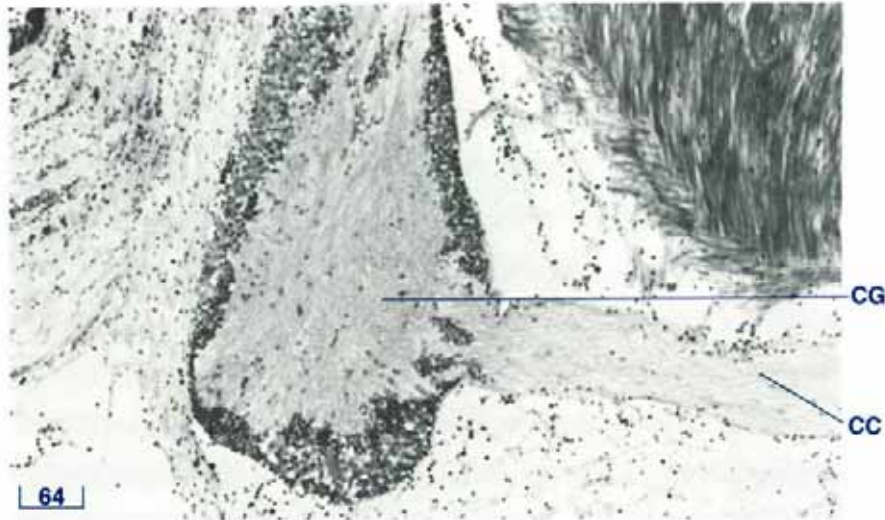


Figure 133 Cerebral ganglion (TS, H & E stain, shell length 3 cm).
CC cerebral commissure, CG cerebral ganglion.

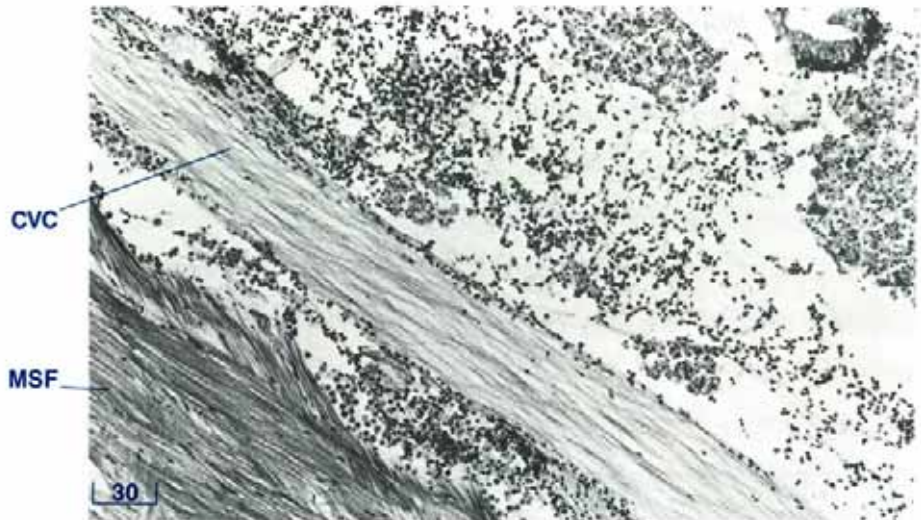


Figure 134 Cerebrovisceral connective (LS, H & E stain, shell length 3 cm).
CVC cerebrovisceral connective, DD digestive diverticula, MSF muscle fibres.

Nervous System — Histology

The central area or medulla of each nerve ganglion is composed of a pale eosinophilic reticular matrix (Fig. 133). This is surrounded by a cortex or outer layer of different types of cells. One cell type has small round black nuclei and no visibly defined cytoplasm. These are probably neuroglia or nerve support cells. Another cell type has large round or ovoid nuclei with a reticular pattern of chromatin. These neurones or nerve cells may or may not be associated with a visible cytoplasm which stains eosinophilic to pale purple. The whole ganglion is surrounded by a thin layer of fibrous tissue.

The nerves are composed of an eosinophilic matrix similar to that of the medulla of the ganglia (Fig. 134). They contain few cells, which if present, are of the nerve support type seen in the ganglia. The nerves are enclosed within a thin layer of fibrous tissue.

Hyaline Organs (eyes) — Histology

The hyaline organs or 'eyes' are ovoid with their longitudinal axes perpendicular to the surface of the inner fold of the siphonal mantle (Fig. 135). Each hyaline organ is composed of several hundred polygonal cells, called lens cells, contained

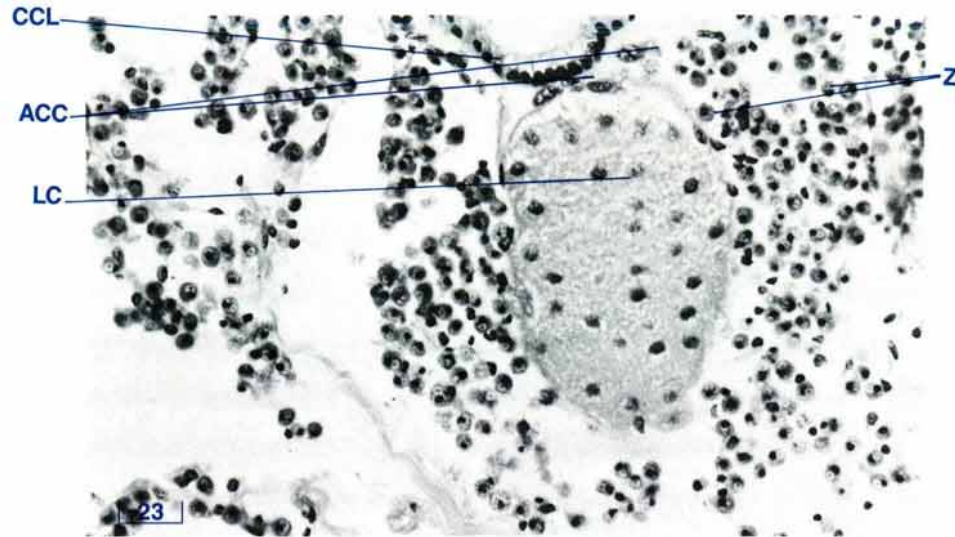


Figure 135 Section of a hyaline organ or 'eye' in the siphonal mantle (TS, H & E stain, shell length 10 cm).
ACC accessory cells, CCL ciliated columnar epithelium, LC lens cells,
Z zooxanthellae.

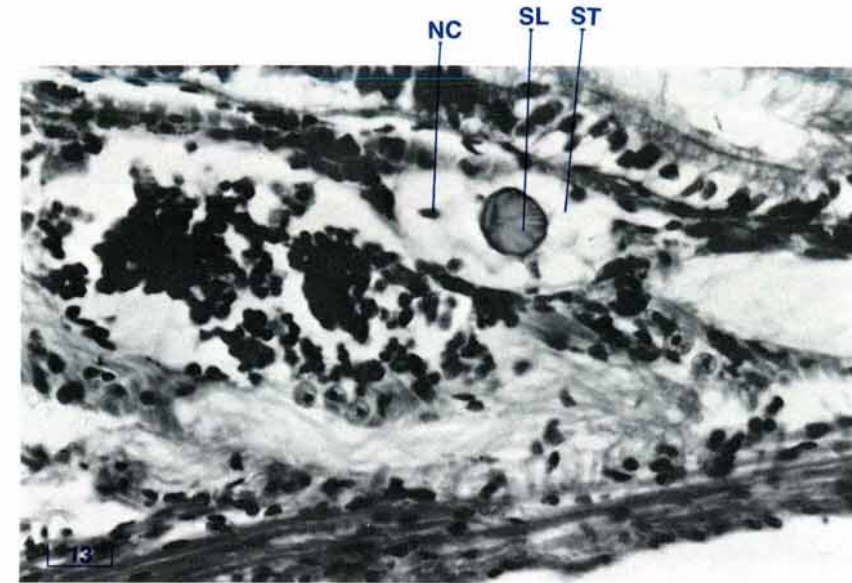


Figure 136 A close-up view of a statocyst with its statolith (LS, H & E stain, shell length 1 cm).
NC nucleus, SL statolith, ST statocyst.


within a thin envelope of connective tissue. The lens cells have dark nuclei and pale cytoplasm with indistinct boundaries.

At the mantle surface, above each hyaline organ, there is a layer of ciliated columnar epithelium. Between this epithelium and the hyaline organ, a variable number of accessory cells is present. Each cell has a large clear vesicular nucleus with a prominent nucleolus. The cytoplasm is basiphilic and has distinct angular boundaries.

A small nerve leaves the lower section of the hyaline organ. Each hyaline organ is surrounded by a zone of zooxanthellae.

Statocysts — Histology

The statocysts are type C (Morton 1985). Each statocyst in transverse section comprises several cells, each with little visible cytoplasm (Fig. 136). The nuclei are located at one corner of each cell so that the cells resemble swollen, empty sacs. In proportion to the statocyst, each basiphilic statolith is large and elliptical in shape and occupies much of the lumen of the statocyst.





THE GONADS

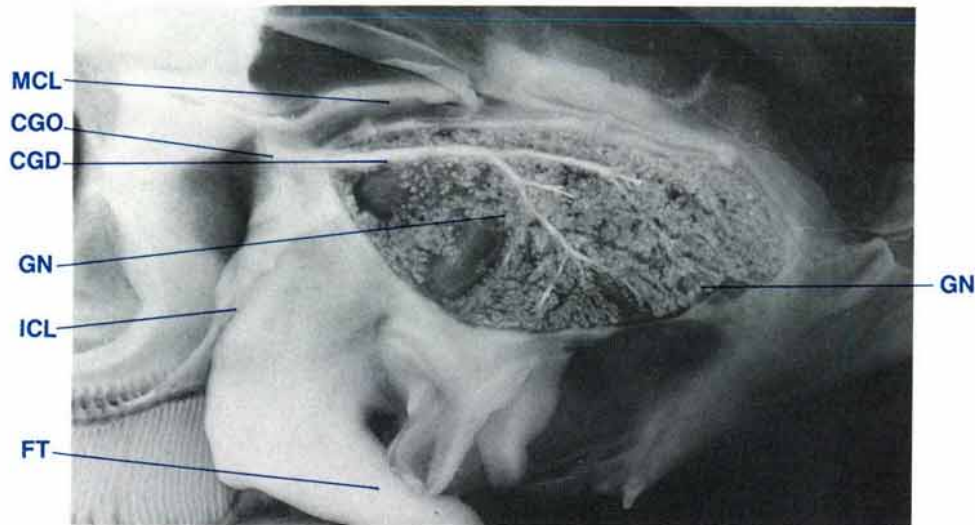


Figure 137 Lateral view of reproductive duct system showing genital orifice (shell length 35 cm, $MgCl_2$ sedated, latex injected).

CGD common genital duct, CGO common genital orifice, FT foot, GN gonad, ICL inner ctenidial suspensory ligament, MCL middle ctenidial suspensory ligament.

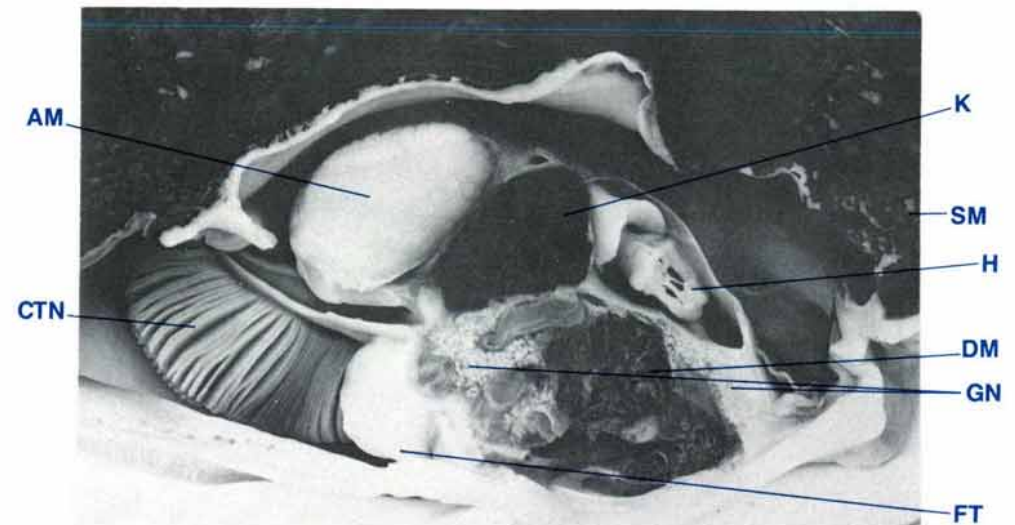


Figure 138 Longitudinal midsection of a clam showing the gonadal tissue (shell length 35 cm, $MgCl_2$ sedated, formalin fixed).

AM adductor muscle, CTN ctenidia, DM digestive mass, FT foot, GN gonad, H heart, K kidney, SM siphonal mantle.

Gonad — Anatomy

The reproductive system in the juvenile or pre-adult clam consists of paired common genital ducts which branch into a primitive network of ducts containing immature gonadal cells. With sexual maturation, this primitive network forms more branches and the immature gonadal cells develop into male follicles (testis) and later, also, into female follicles (ovary) so that the clam becomes a simultaneous hermaphrodite. The products of both the testes and ovaries empty into the same duct system and are discharged out of the paired common genital ducts (Fig. 137).

The gonadal tissue develops in the connective tissue zone between the digestive mass and the muscular wall which

encloses that mass (Fig. 138). It may surround most, if not all, of the digestive mass in a fully mature clam. The gonadal tissue has a cream to white colour which contrasts with the dark red-brown of the digestive diverticula (Figs 137, 138).

The paired common genital ducts pass through the muscular covering which encloses the reproductive organ and digestive mass and travel along the ventral aspect of the kidneys, adjacent to the kidney-byssal gland junction. They end near the intersection of the byssal organ, the posterior byssal/pedal retractor muscles and the postero-ventral aspect of the kidneys. The ducts run lateral to the cerebrovisceral connective nerve (Figs 120, 143). The common genital ducts open into the inner suprabrachial compartment of the excurrent water chamber (Fig. 59) via the common genital orifice.

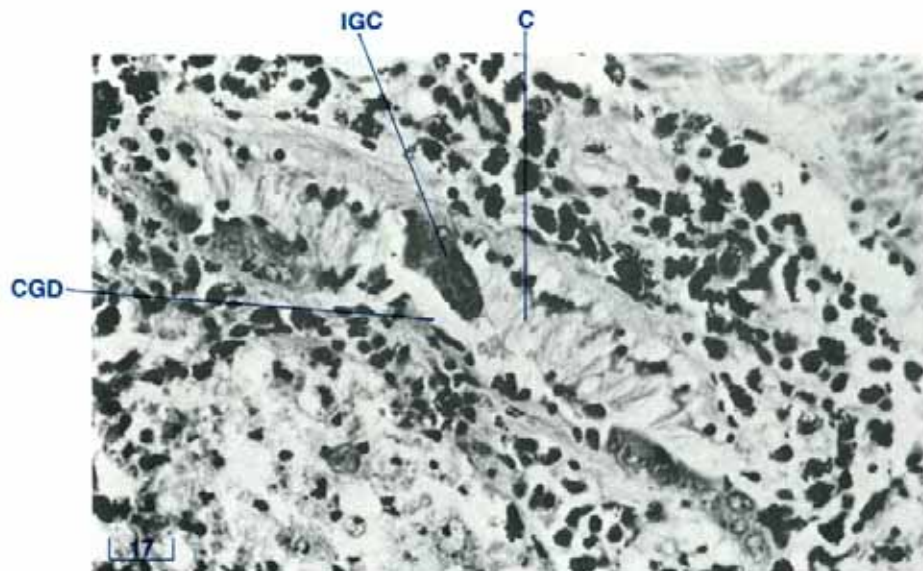


Figure 139 Immature ducts of the genital system of a young clam (LS, H & E stain, shell length 10 cm).

C cilia, CGD common genital duct, IGC immature gonadal cells.

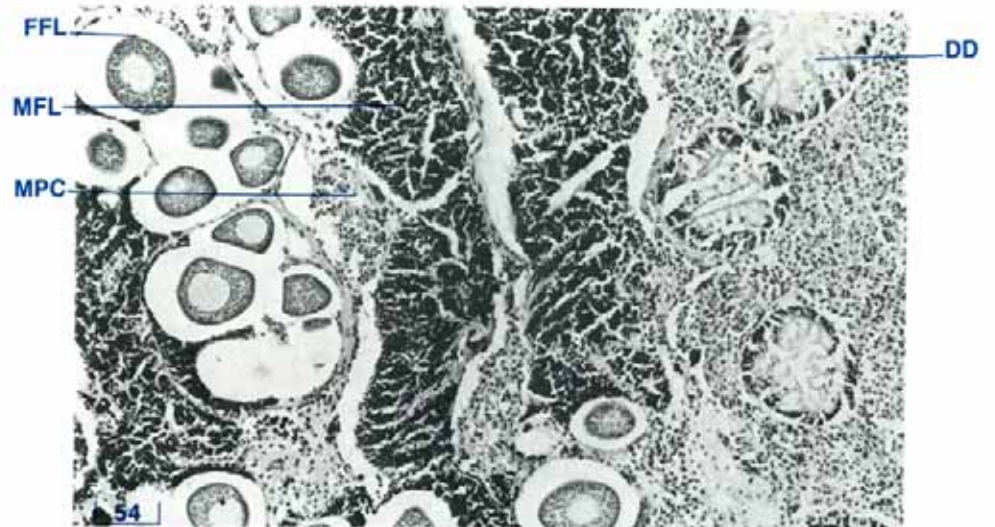


Figure 140 Gonad tissue containing male and female follicles (*T. maxima*, TS, H & E stain, shell length 15 cm).

DD digestive diverticulae, FFL female follicle, MFL male follicle, MPC macrophage centre.

Gonad — Histology

The development and microscopic appearance of the gonad varies with the species, age, degree of maturity, season and the prevailing environmental conditions. Secondary and tertiary genital ducts branch throughout the connective tissue surrounding the digestive diverticula and the midgut. The immature gonadal cells (Fig. 139) within the follicles multiply, grow and fill the lumen of the follicles. In giant clams, male follicles develop first, followed by female follicles. A sexually mature clam is a simultaneous hermaphrodite and its gonad contains both male and female follicles (Fig. 140).

A maturing male follicle contains cells at progressive stages of development. There is an outer layer of cells with large round,

dark-staining nuclei with blue granular contents but without visible cytoplasm, the spermatogonia. More centrally within the follicle there is another layer of smaller cells of similar appearance to the above, but with small nuclei, the spermatocytes. In the centre of the follicle and approaching the exit from the follicle, are rod-shaped bodies, the spermatozoa, with their thicker ends attached to fibrous partitions which converge towards the common exit from the follicle (Fig. 141). After spawning, there is a scarcity of the above stages which are replaced largely by interstitial connective tissue and granulocytes.

A maturing female follicle also contains cells in progressive stages of development. The undifferentiated cells or oocytes are attached to the follicular wall and develop into small, elongated

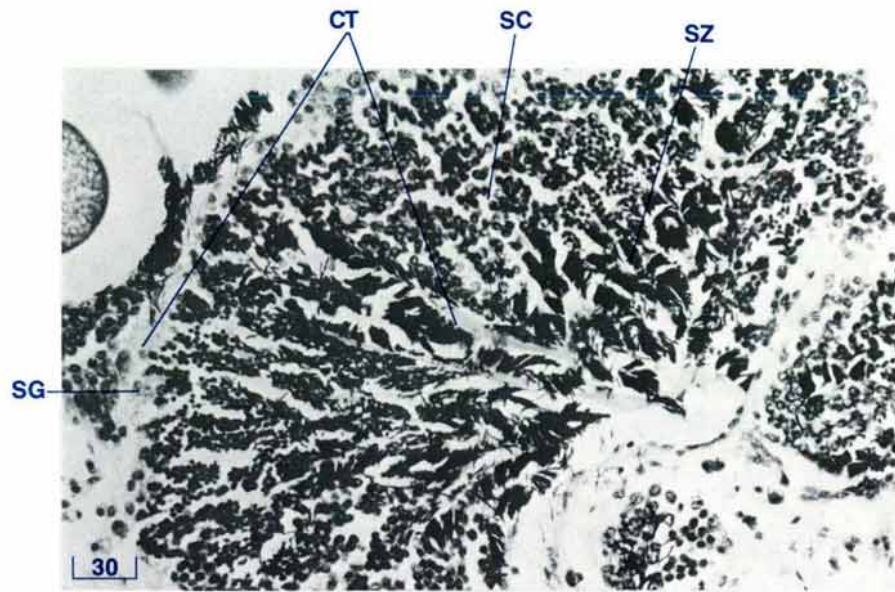


Figure 141 Male follicles of the testis (*T. crocea*, TS, H & E stain, shell length 9 cm).

CT connective tissue (wall), SC spermatocytes, SG spermatogonia, SZ spermatozoa.

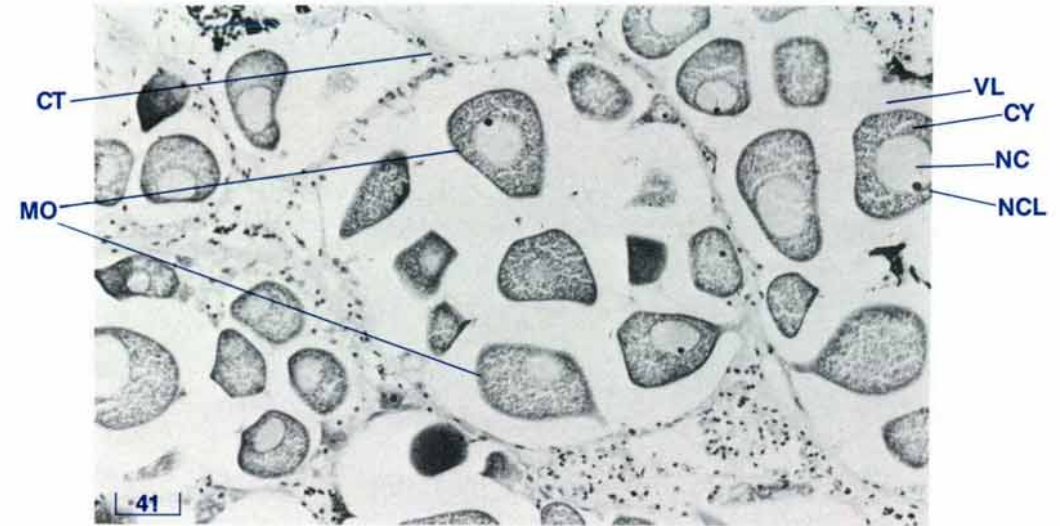


Figure 142 Female follicles of the ovary (*T. crocea*, TS, H & E stain, shell length 9 cm).

CT connective tissue, CY cytoplasm, MO mature ova, NC nucleus, NCL nucleolus, VL vitelline layer.

ova which fill the follicular lumen. The ova become round or elliptical and densely packed. The thick, smooth, follicular walls between individual ova become thinned and crenated. Mature ova are large cells approximately 100 μm in diameter (Fig. 142). The cytoplasm stains a mottled reddish-purple and white. The outer surface of the cell is covered with a purplish-staining membrane which forms a peduncle by which the ovum is attached to the connective tissue of the follicular wall. The nucleus is large and round to oval with a light grey, granular cytoplasm. The nucleolus is a small, round, dark purple body located to one side of the nucleus. Each ovum is surrounded by a wide, clear zone (vitelline layer) of type 3 mucin (see page 132). A thin membrane encloses each vitelline layer. After spawning, the follicles are

largely empty. The follicular walls are thin and crenate or missing, with some ova undergoing cytolysis. Finally, interstitial connective tissue and granulocytes predominate.

Since gonad maturation is a continuous process, all or any stages may be present in the gonad.

Surrounding the male and female follicles and frequently between the follicles, there is a network of connective tissue which may contain macrophage centres, haemolymph sinuses and scattered eosinophilic granulocytes (Fig. 140).

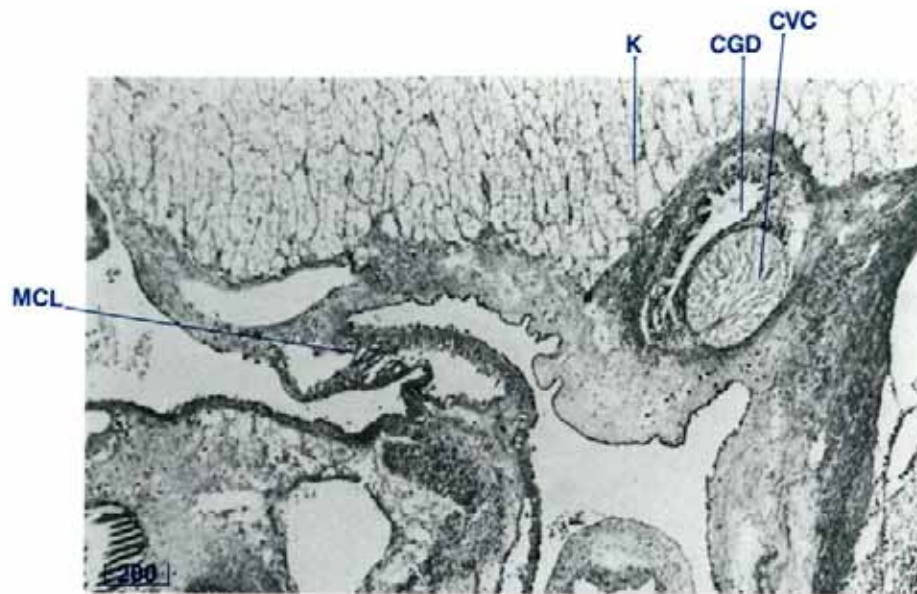


Figure 143 Common genital duct (TS, H & E stain, shell length 10 cm).

CGD common genital duct, CVC cerebrovisceral connective (nerve), K kidney, MCL middle ctenoidal suspensory ligament.

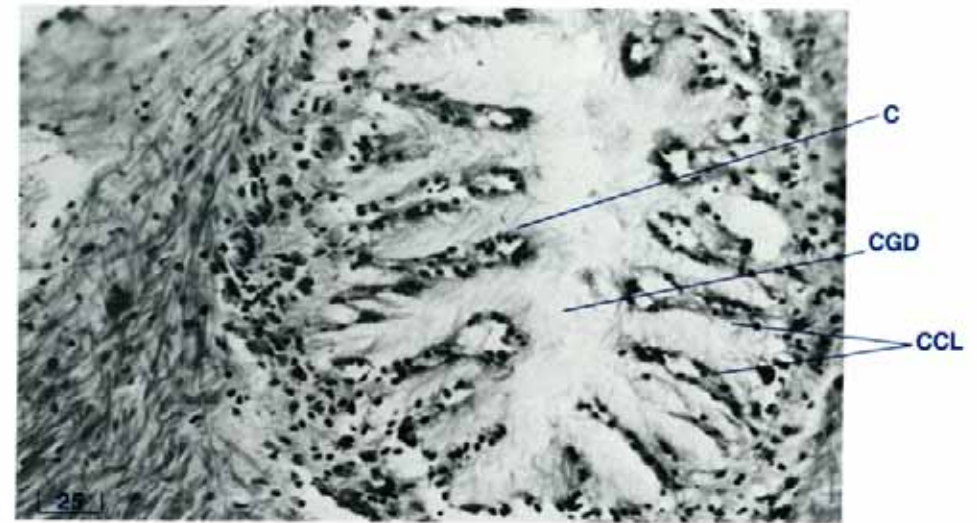



Figure 144 Common genital duct showing the heavily folded epithelium (TS, H & E stain, shell length 9 cm).

C cilia, CCL ciliated columnar epithelium, CGD common genital duct.

The sperm and ova are expressed from the clam via a branched network of ducts which coalesce to a common genital duct on each side of the clam (Figs 137, 143). Both male and female follicles are situated at the ends of branching ducts, like grapes on a vine. The common genital ducts are lined with a folded layer of ciliated columnar epithelium (Fig. 144).

In sexually immature clams, the precursor cells may be seen attached to the walls of elementary ducts in the tissue surrounding the digestive mass (Fig. 139). These precursor cells have large vesicular nuclei and dark staining cytoplasm with poorly defined boundaries.



**THE ZOOXANTHELLAL
TUBE SYSTEM AND
ZOOXANTHELLAE**

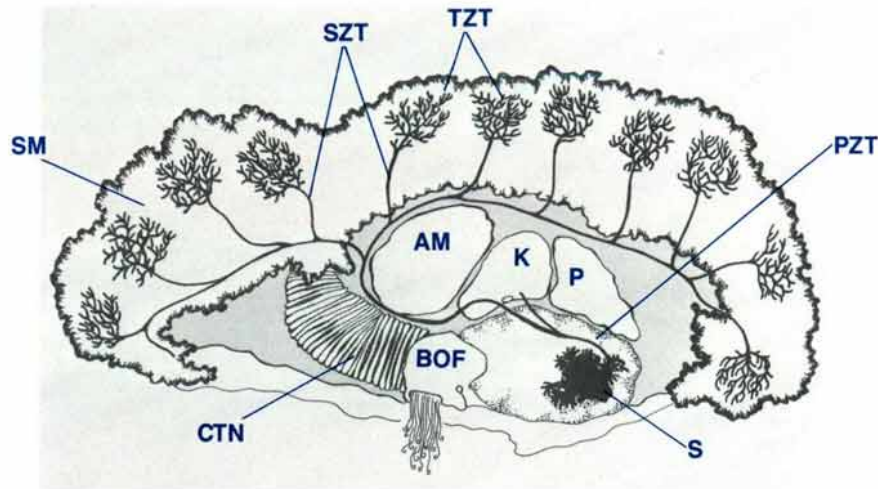


Figure 145 A diagrammatic view of a mid-longitudinal section of a clam to show the path followed by the main zooxanthellal tube through the clam.

AM adductor muscle, BOF byssal organ/foot, CTN ctenidia, K kidney, P pericardium, PZT primary zooxanthellal tube, S stomach, SM siphonal mantle, SZT secondary zooxanthellal tube, TZT tertiary zooxanthellal tube.

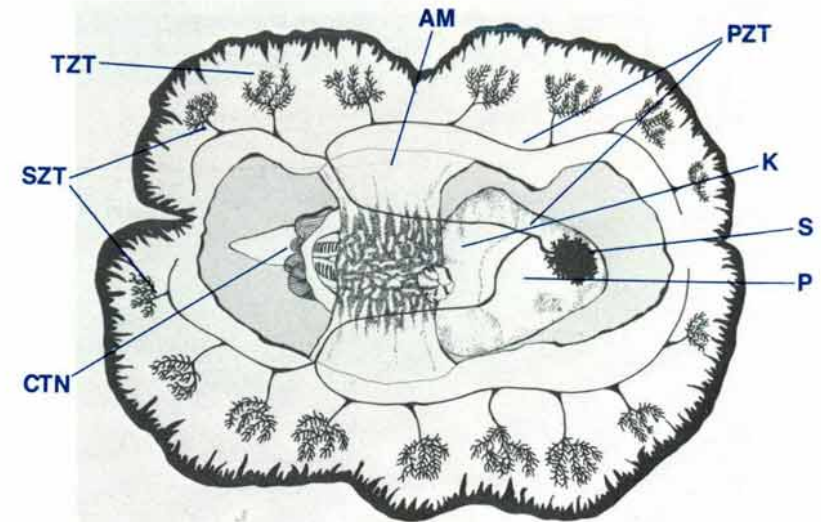


Figure 146 Dorsal diagrammatic view of a clam to show the path followed by the main zooxanthellal tube through the clam.

AM adductor muscle, CTN ctenidia, K kidney, P pericardium, PZT primary zooxanthellal tube, S stomach, SM siphonal mantle, SZT secondary zooxanthellal tube, TZT tertiary zooxanthellal tube.

Zooxanthellal Tube System — Anatomy

The zooxanthellal tube system originates as a single primary zooxanthellal tube. It arises from one of the digestive diverticular ducts from the stomach, in the left of the digestive mass (Figs 145, 146, 147, 149). It passes dorsally and posteriorly between the digestive diverticula (Fig. 148) and then between the crystalline style sac and the muscular wall which encloses the digestive mass and reproductive organ. Above the crystalline sac in the rear, lateral aspect of the digestive mass, the zooxanthellal tube divides into right and left tubes (Fig. 150). These tubes run close to the dorsal aspect of the muscular wall which encloses the digestive mass and reproductive organ prior to passing through this wall close to the visceral-renal haemolymph portals into the kidney parenchyme (Figs 151,

152). The tubes travel through the kidney in a ventral direction until they leave the kidney and travel through the root of the middle ctenidial suspensory ligament close to the cerebro-visceral connective (nerve) (Fig. 153). The tubes continue to travel posteriorly until they reach the adductor muscle where they are embedded in the connective tissue sheath which encloses that muscle (Fig. 154). While running around the posterior of the adductor muscle, each tube gives off a branch which lies in the floor of the excurrent water chamber. The primary zooxanthellal tube passes towards the ends of the adductor muscle and travels dorsally into the root of the siphonal mantle. The tube branches both anteriorly and posteriorly. One or more main branches run along in the root of the siphonal mantle close to the circumpallial artery, the circumpallial vein and the pallial nerves (Fig. 155). Secondary zooxan-

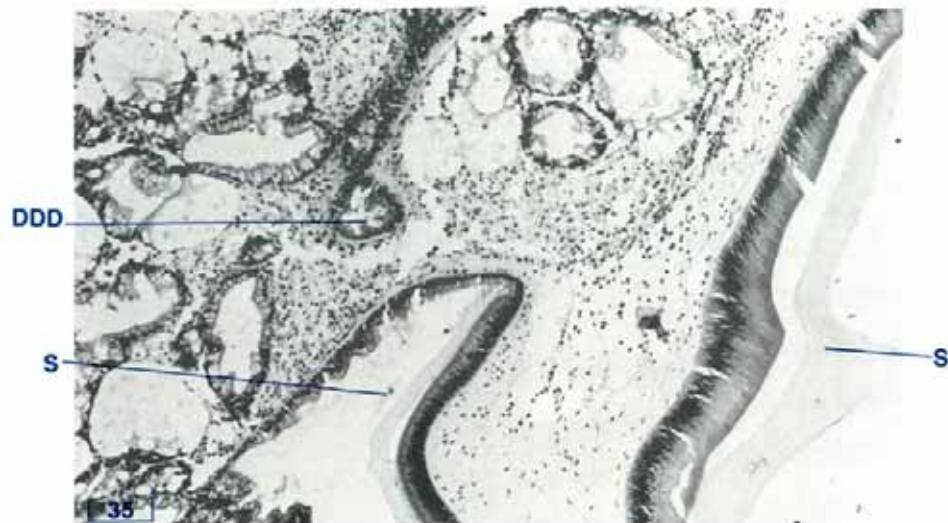

Figure 147 The digestive diverticular duct into which the zooxanthellal tube in Fig. 148 enters (DDD); Sections in Figs 147 and 148 are part of a series and are separated by 30 μm . (TS, H & E stain, shell length 5 cm). DDD digestive diverticular duct, S stomach.

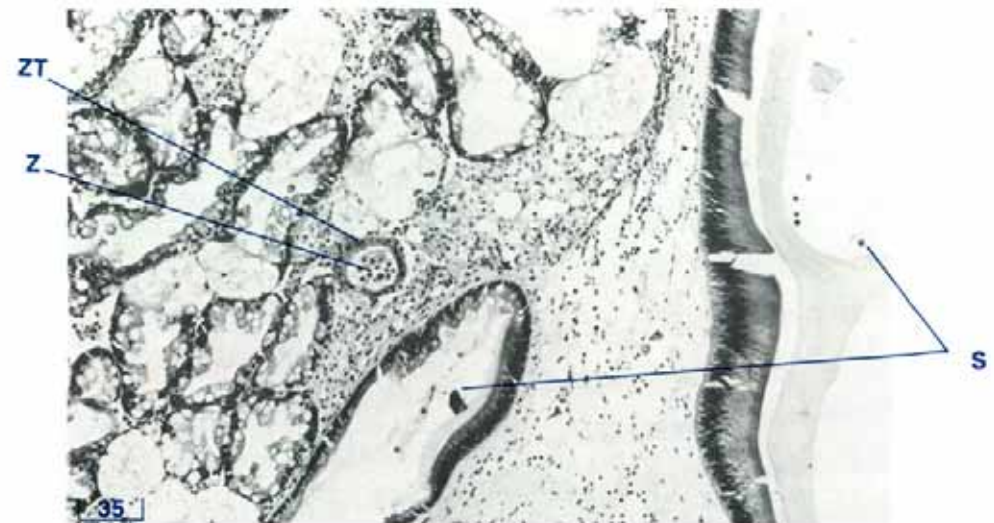


Figure 148 The zooxanthellal tube as it passes through the digestive diverticula; Sections in Figs 147 and 148 are part of a series and are separated by 30 μm . (TS, H & E stain, shell length 5 cm). S stomach, Z zooxanthellae, ZT zooxanthellal tube.

thellal tubes (Fig. 156) branch into the upper levels of the siphonal mantle where they terminate in convolutions of thin tubes, the tertiary (or terminal) zooxanthellal tubes, containing the zooxanthellae (Fig. 157). Other secondary zooxanthellal tubes branch off the primary zooxanthellal tube to form other tertiary (or terminal) zooxanthellal tubes in other organs such as the ctenidia, the surface of the adductor muscle, and some areas of the lateral mantle.

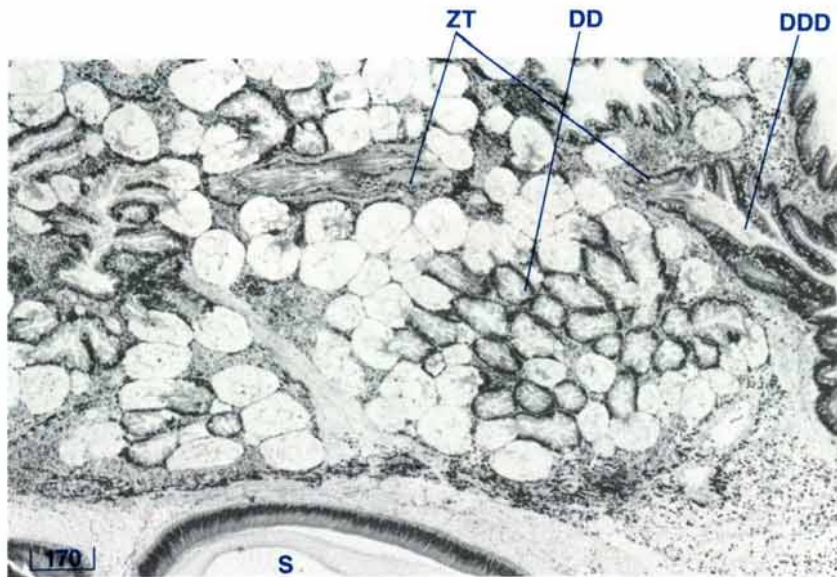


Figure 149 The zooxanthellal tube as it leaves one of the digestive diverticular ducts of the stomach (LS, H & E stain, shell length 11 cm).
 DD digestive diverticula, DDD digestive diverticular duct, S stomach, ZT zooxanthellal tube.

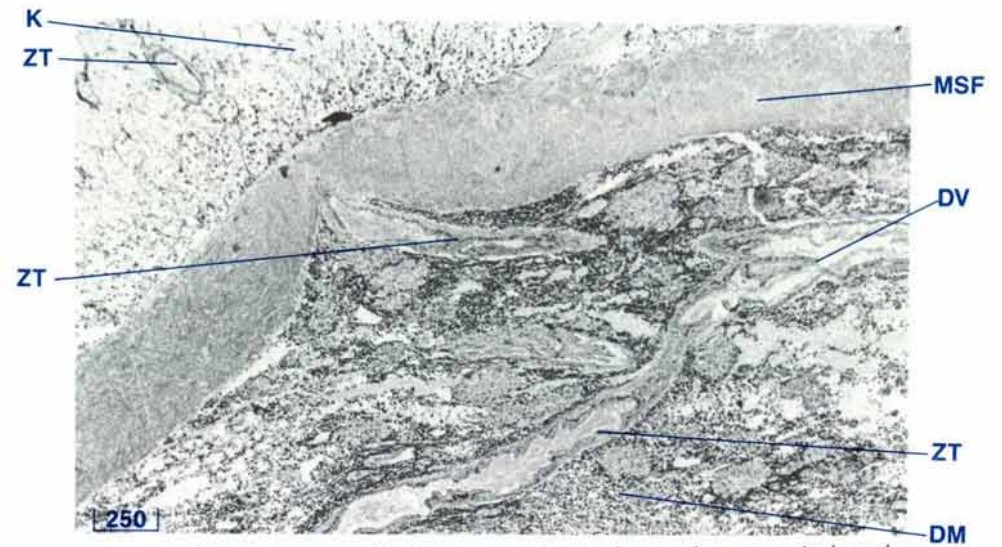


Figure 150 The zooxanthellal tube as it divides in the posterior dorsal aspect of the digestive mass prior to passing into the kidney (HS, H & E stain, shell length 10 cm).
 DM digestive mass, DV division (of zooxanthellal tube), K kidney, MSF muscle fibres, ZT zooxanthellal tube.

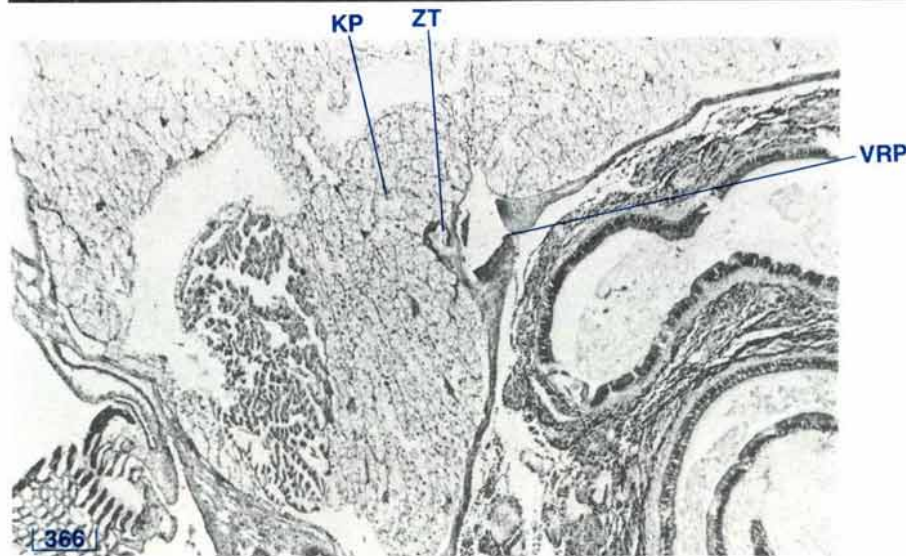


Figure 151 The zooxanthellal tube as it passes into the kidney (TS, H & E stain, shell length 10 cm).
 KP kidney parenchyme, VRP visceral-renal haemolymph portal, ZT zooxanthellal tube.

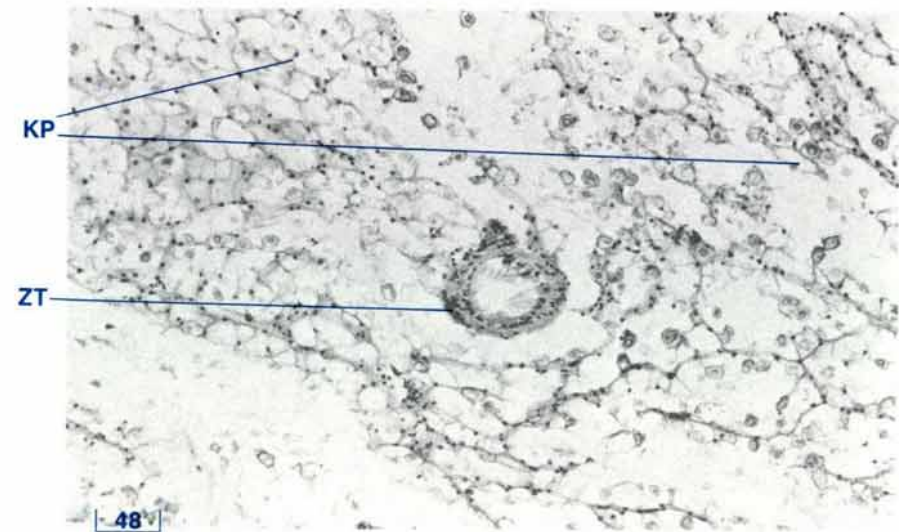


Figure 152 The zooxanthellal tube as it passes through the kidney (TS, H & E stain, shell length 10 cm).
 KP kidney parenchyme, ZT zooxanthellal tube.

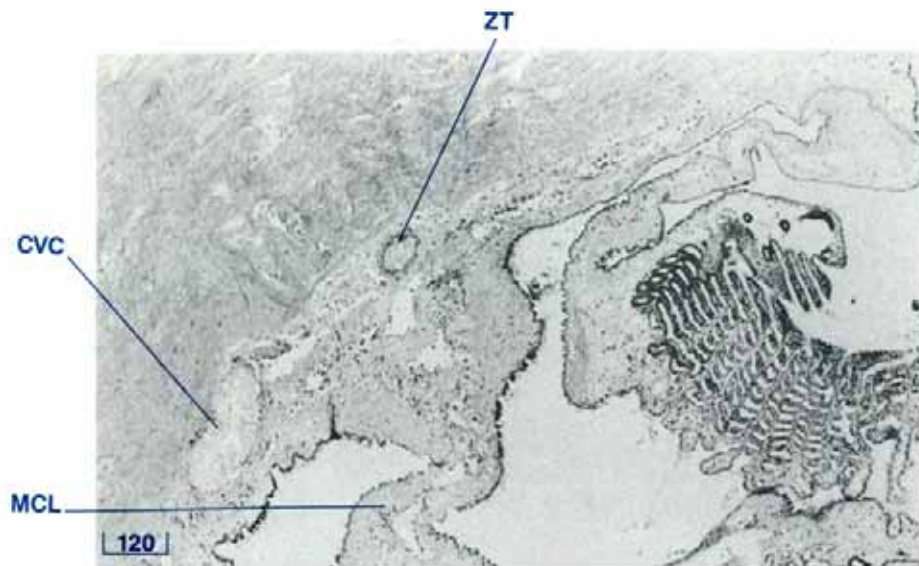


Figure 153 The zooxanthellal tube as it passes through the root of the middle ctenidial suspensory ligament (TS, H & E stain, shell length 10 cm).

CVC cerebrovisceral connective, MCL middle ctenidial suspensory ligament, ZT zooxanthellal tube.

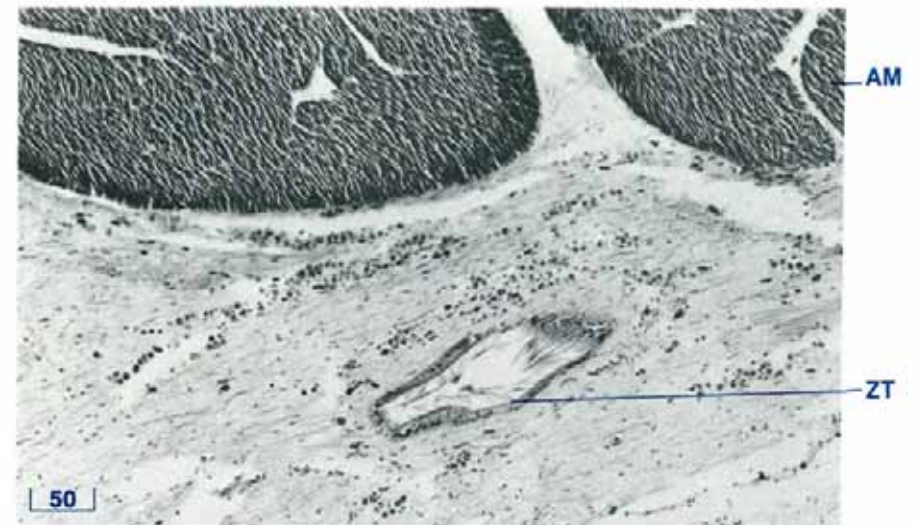


Figure 154 The zooxanthellal tube as it passes posteroventrally around the adductor muscle (LS, H & E stain, shell length 10 cm).

AM adductor muscle, ZT zooxanthellal tube.

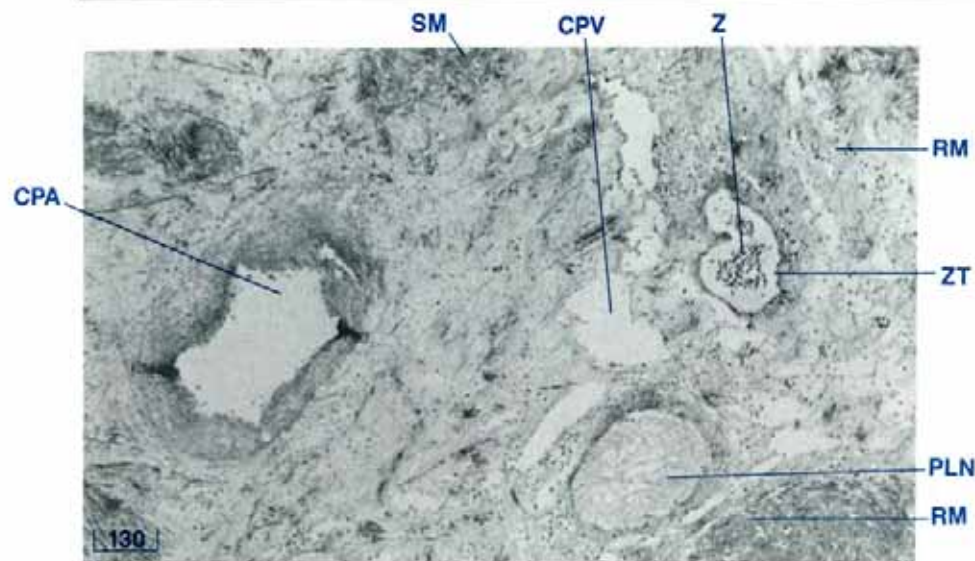

Figure 155 The zooxanthellal tube as it travels along parallel to the root of the siphonal mantle (TS, H & E stain, shell length 10 cm).

CPA circumpallial artery, CPV circumpallial vein, PLN pallial nerve, RM retractor muscles, SM siphonal mantle, Z zooxanthellae, ZT zooxanthellal tube.

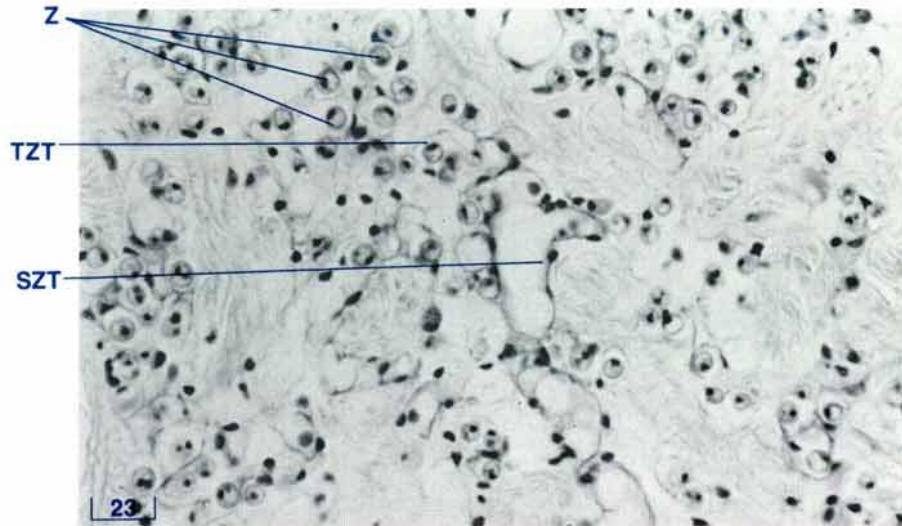


Figure 156 Secondary and tertiary zooxanthellal tubes in the siphonal mantle (TS, Alcian Blue stain, shell length 10 cm).

SZT secondary zooxanthellal tube, TZT tertiary (terminal) zooxanthellal tube, Z zooxanthellae.

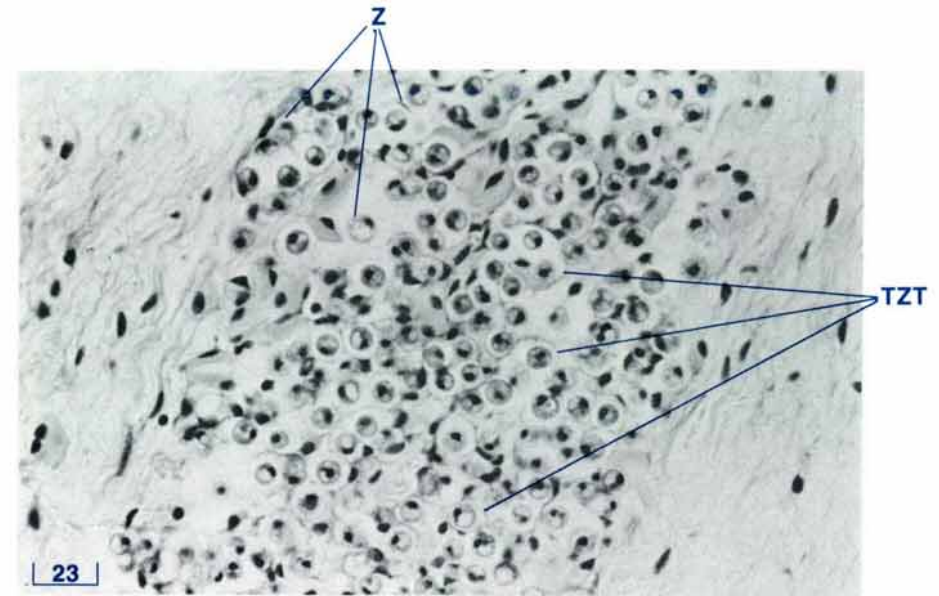


Figure 157 Zooxanthellae in the tertiary (terminal) zooxanthellal tubes in the upper siphonal mantle (TS, Alcian Blue stain, shell length 10 cm).

TZT tertiary (terminal) zooxanthellal tubes, Z zooxanthellae.

Zooxanthellal Tube — Histology

The primary zooxanthellal tube has a distinctive epithelial lining of cuboidal to low columnar cells with long cilia and is surrounded by a thin zone of muscle fibres (Fig. 158). The secondary zooxanthellal tube is thin-walled and is lined by tubular epithelial cells with thin cytoplasm and small, prominent dark nuclei (Fig. 156). Some cilia are present. Similar epithelial cells line the numerous tertiary or terminal zooxanthellal tubes which enclose the zooxanthellae (Fig. 157). The iridophores which are seen in close association with the zooxanthellae in the siphonal mantle (Fig. 26) are external to the zooxanthellal tube system.

Zooxanthellae — Histology

The zooxanthellae are spherical unicellular algae, dinoflagellates *Symbiodium microadriaticum*, which range from 7 to 8 μm in diameter. The normal zooxanthellae in the light-exposed tissues, such as the siphonal mantle, differ in their histology from those degenerate zooxanthellae found in the macrophages of the interdiverticular spaces of the digestive mass.

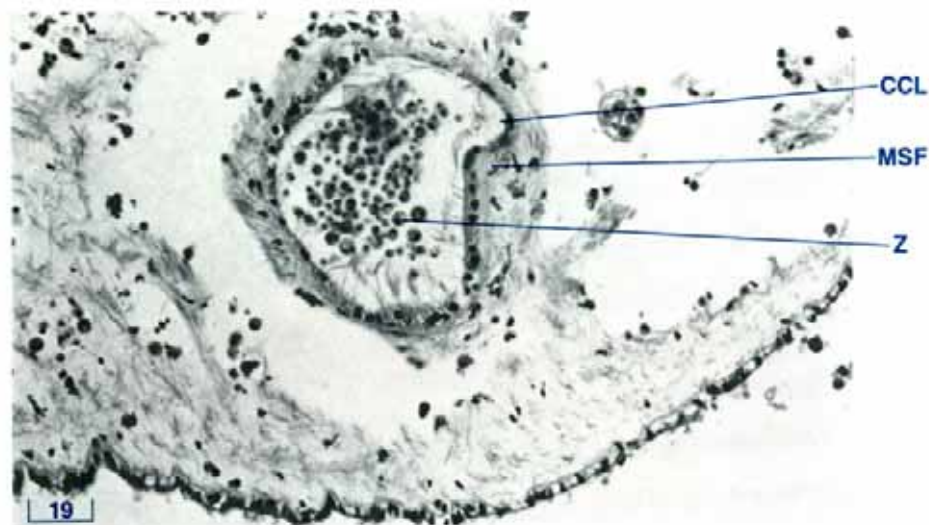


Figure 158 A high power view of a zooxanthellal tube near the posterior adductor muscle (TS, H & E stain, shell length 10 cm). CCL ciliated columnar epithelium, MSF muscle fibres, Z zooxanthellae.

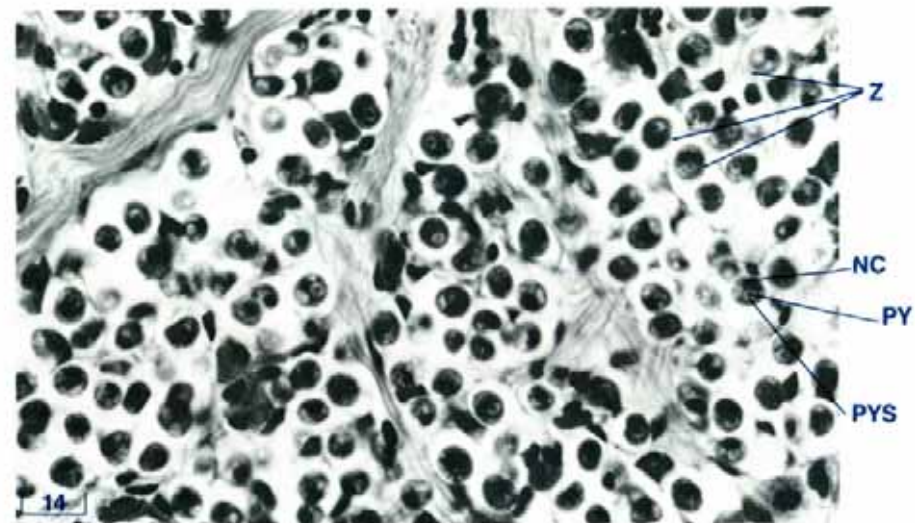


Figure 159 Zooxanthellae in good condition in the siphonal mantle (TS, H & E stain, shell length 6 cm). NC nucleus, PY pyrenoid, PYS pyrenoid sheath, Z zooxanthellae.

Normal Zooxanthellae

Normal symbiotic zooxanthellae (Fig. 159) live within the zooxanthellal tube system (Figs 157, 159). They are most numerous in those regions of the clam exposed to light, especially within the inner fold of the expanded siphonal mantle. Here they are arranged approximately perpendicular to the siphonal mantle's exposed surface. They also occur, in small numbers, beneath the epithelium which covers the dorsal surfaces of the visceral mass, the pericardium and the adductor muscle, and in sections of the gills. These algal cells are uniformly ovoid in shape.

The interior of a healthy zooxanthellal cell contains three principal structures: the nucleus, the pyrenoid and the accumulation body. These are approximately the same size and may be seen in histological sections. The cell cytoplasm has a vacuolated appearance. The spherical nucleus has a diameter of about one-third that of the algal cell and has a dark-staining, granular content which are the chromosomes during interphase. The pyrenoid appears as a round, eosinophilic structure surrounded by a clear zone, the pyrenoid sheath. This zone together with other particles in the algal cell are positive for glycogen (see page 132). A small percentage of the zooxanthellae contain type 2 mucins (see page 132) and are surrounded by a refractile capsule. The accumulation body is round and stains yellow-orange.

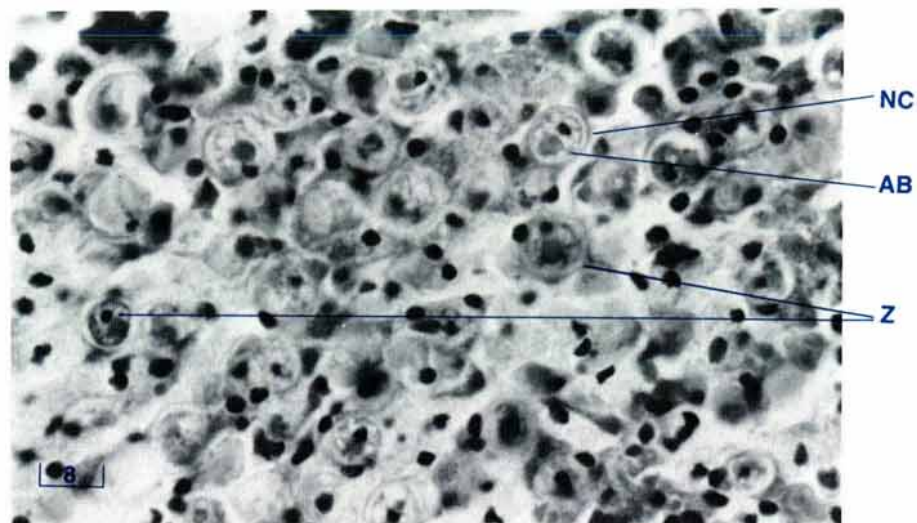



Figure 160 Zooxanthellae degenerating in a macrophage centre of the digestive mass (TS, H & E stain, shell length 6 cm).

AB accumulation body, NC nucleus, Z zooxanthellae (degenerating).

Degenerating Zooxanthellae

Degenerating zooxanthellae may be seen in phagocytes in macrophage centres around the digestive mass including the digestive diverticulae (Fig. 160) and the midgut. They may also be seen in macrophage centres in the kidney and lateral mantle. With ageing or starvation of the algal cells, there is loss of glycogen-like material from the cytoplasm and from the pyrenoid sheath. The degenerating zooxanthellae are surrounded by a refractile capsule and contain type 2 mucins (see page 132). There is a decrease in the size of the pyrenoid body, and an increase in the size of the accumulation body with an increase in the latter's content of calcium oxalate. The accumulation body may come to occupy most of the cell. In the latter stages of degeneration, the zooxanthellae show a loss of specificity for histochemical stains.



RELEVANT LITERATURE

Further reading on clam/molluscan anatomy and histology.

Introduction

- Govan, H. 1989. Vernacular names of tridacnid clams in the Pacific region. *Aquabyte* 2. 5-7.
- Rosewater, J. 1965. The family Tridacnidae in the Indo-Pacific. *Indo-Pacific Mollusca* 1. 347-396.
- Yonge, C.M. 1975. Giant clams. *Sci. Amer.* 232. 96-105.

Techniques

- Bancroft, J.D. and Stevens, A. (ed.) 1982. *Theory and Practice of Histological Techniques*. Churchill Livingstone, Edinburgh.
- Crowder, C.H. 1988. *Microwave and Conventional Procedures. A manual of histologic techniques*. Dept. of Vet. Pathology, School of Veterinary Medicine, Louisiana State University, Baton Rouge, Louisiana, U.S.A.
- Drury, R.A.B. and Wallington, E.A. 1980. *Carlton's Histological Technique*, 5th edition. Oxford University Press, Oxford.
- Luna, L.G. (ed.) 1968. *Manual of Histologic Staining Methods of the Armed Forces Institute of Pathology*, 3rd edition. McGraw-Hill Book Company, New York.
- Stasek, C.R. 1962. The form, growth and evolution of Tridacnidae (Giant Clams). *Arch. Zool. Exp. Gen.* 101. 1-40.

General Molluscan Anatomy, Histology, Etc.

- Barnes, R.D. 1974. *Invertebrate Zoology*, 3rd edition. W.B. Saunders Co., Philadelphia.
- Borradaile, L.A. and Potts, F.A. 1961. *The Invertebrata, A Manual for the Use of Students*. 4th edition. G.A. Kerkut (ed.). Cambridge Uni. Press.

- Copland, J.W. and Lucas, J.S. (ed.) 1988. *Giant clams in Asia and the Pacific*, ACIAR Monograph No. 9, Australian Centre for International Agricultural Research, Canberra. 274 p.
- Galtsoff, P.S. 1964. *The American Oyster, Crassostrea virginica* (Gmelin). *Fishery Bulletin of the Fish and Wildlife Service*. 64. 480 pp.
- Jamieson, S.C. 1976. Early life history of giant clams *Tridacna crocea* (Lamarck), *Tridacna maxina* (Roding), and *Hippopus hippopus* (Linnaeus). *Pacific Science* 30. 219-233.
- Lacaze-Duthiers, H. 1902. Morphologie de *Tridacna elongata* et de *Hippopus*. *Arch. Zool. Exp. Gen.* (3) 10. 99-212.
- Lawrence, E. 1989. *Henderson's Dictionary of Biological Terms*, 10th edition. Longmans Scientific and Technical, London.
- Meglitsch, P.A. 1972. Phylum Mollusca, Chapter 10. In: *Invertebrate Zoology*, 2nd edition. Oxford University Press.
- Phillips Dales, R. (ed.) 1969. *Practical Invertebrate Zoology — a laboratory manual*. Sidgwick and Jackson, London.

The Shell

- Fankboner, P.V. 1971. Self righting by tridacnid clams. *Nature*, London. 230. 579-580.
- Lucas, J.S., Ledua, E. and Braley, R.D. 1991. *Tridacna tevoroa* (Lucas, Ledua and Braley): A recently-described species of giant clam (Bivalvia; Tridacnidae) from Fiji and Tonga. *Nautilus* 105. 92-103.
- Rosewater, J. 1982. A new species of *Hippopus* (Bivalvia: Tridacnidae). *Nautilus* 96. 3-6.
- Rosewater, J. 1965. The family Tridacnidae in the Indo-Pacific. *Indo-Pacific Mollusca* 1. 347-396.

Yonge, C.M. 1980. Functional morphology and evolution in the Tridacnidae (Mollusca: Bivalvia: Cardiacea). *Records of the Australian Museum*. **33**(17). 735–777.

The Mantle and Water Chambers

Fankboner, P.V. 1971. Intracellular digestion of symbiotic zooxanthellae by host amoebocytes in giant clams (Bivalvia: Tridacnidae) with a note on the nutritional role of the hypertrophied siphonal epidermis. *Biol. Bull.* **141**. 222–234.

Goreau, T.F., Goreau, N.I. and Yonge, C.M. 1973. On the utilisation of photosynthetic products from zooxanthellae and of a dissolved amino acid in *Tridacna maxima f.elongata*. *J. Zool.*, London **169**. 417–454.

Grobber, C. 1898. Expedition S.M. Schiff "Pola" in das Rothe Meer. VIII. Zoologische Ergebnisse. Beitrage zur Morphologie und Anatomie der Tridacniden. *Denkschr. Math.-Naturwiss. Classe K. Acad. Wiss. Wien.* **65**. 433–444.

Kamishima, Y. 1990. Organization and development of reflecting platelets in iridophores of the giant clam, *Tridacna crocea* Lamarck. *Zool. Sci.* **7**. 63–72.

Kawaguti, S. 1966. Electron microscopy on the mantle of the giant clam with special references to zooxanthellae and iridophores. *Biol. J. Okayama Univ.* **12**. 81–92.

Mansour, K. 1946. Mantle chambers of *Tridacna elongata*. *Nature*, London. **158**. 523–524.

Purchon, R.D. 1954. A note on the biology of *Tridacna crocea* Lam., *Proceedings of the Malacological Society of London.* **31**. 95–110.

Yonge, C.M. 1953. Mantle chambers and water circulation in the Tridacnidae (Mollusca). *Proc. Zool. Soc.*, London. **123**. 551–561.

Yonge, C.M. 1980. Functional morphology and evolution in the Tridacnidae (Mollusca: Bivalvia: Cardiacea). *Records of the Australian Museum*. **33**(17). 735–777.

The Ctenidia and Labial Palps

Aitkens, D. 1937. On the ciliary mechanisms and inter-relationships of Lamellibranchs. Part IV: Cuticular fusion, with special reference to the fourth aperture in

certain lamellibranchs. *Quarterly Journal of Microscopical Science.* **79**. 423–445.

Goreau, T.F., Goreau, N.I. and Yonge, C.M. 1973. On the utilisation of photosynthetic products from zooxanthellae and of a dissolved amino acid in *Tridacna maxima f.elongata*. *J. Zool.*, London. **169**. 147–454.

Stasek, C.R. 1962. The form, growth and evolution of Tridacnidae (Giant Clams). *Arch. Zool. Exp. Gen.* **101**. 1–40.

The Adductor Muscle

Bowden, J. 1958. The structure and innervation of lamellibranch muscle. *Int. Review of Cytology.* **7**. 295–335.

Matsuno, A. and Kuga, H. 1989. Ultrastructure of muscle cells in the adductor of the boring clam *Tridacna crocea*. *J. Morph.* **200**. 247–253.

Philpott, D.E., Kahlbrock, M. and Szent-Gyorgyi, A.G. 1960. Filamentous organisation of molluscan muscles *J. Ultrastructure Research* **3**. 254–269.

Yonge, C.M. 1953. The monomyarian condition in the Lamellibranchia. *Trans. R. Soc. Edinburgh.* **62**. 443–478.

The Byssal Organ and Foot

Goreau, T.F., Goreau, N.I. and Yonge, C.M. 1973. On the utilisation of photosynthetic products from zooxanthellae and of a dissolved amino acid in *Tridacna maxima f.elongata*. *J. Zool.*, London. **169**. 417–454.

The Digestive System

Fankboner, P.V. and Reid, R.G.B 1990. Nutrition in giant clams (Tridacnidae) In: *The bivalvia — Proceedings of a Memorial Symposium in Honour of Sir Charles Maurice Yonge, Edinburgh, 1986*. B. Morton (ed.). Hong Kong University Press, Hong Kong.

Goreau, T.F., Goreau, N.I. and Yonge, C.M. 1973. On the utilisation of photosynthetic products from zooxanthellae and of a dissolved amino acid in *Tridacna maxima f.elongata*. *J. Zool.*, London. **169**. 417–454.

Graham, A. 1949. The molluscan stomach. *Trans. Roy. Soc. Edinburgh.* **61**. 737–778.

- Morton, B. 1978. The diurnal rhythm and the processes of feeding and digestion in *Tridacna crocea* (Bivalvia: Tridacnidae). *J. Zool.*, London. **185**. 371–387.
- Morton, B. 1983. Feeding and digestion in bivalvia. In: *The Mollusca*, Vol 5, Physiology, Part 2, Academic Press, Saleuddin, A.S.M., and Wilbur, K.M., (ed.). 65–147.
- Purchon, R.D. 1954. A note on the biology of *Tridacna crocea* Lam., *Proc. Malacol. Soc.* **31**. 95–110.
- Yonge, C.M. 1936. Mode of life, feeding, digestion and symbiosis with zooxanthellae in the Tridacnidae. *Great Barrier Reef Expedition (1928–1929) Scientific Reports*. London. **1**. 283–331.

The Heart and Haemolymph System

- Cheng, T.C. 1981. Bivalves, Ch 8. In: *Invertebrate Blood Cells*, Vol I, Ratcliffe, N.A. and Rowley, A.F. (ed.). Academic Press, New York. 233–300.
- Grobber, C. 1898. Expedition S.M. Schiff "Pola" in das Rothe Meer. VIII. Zoologische Ergebnisse. Beitrage zur Morphologie und Anatomie der Tridacniden. *Denkschr. Math.-Naturwiss. Classe K. Acad. Wiss. Wien.* **65**. 433–444.
- Mansour, K. 1945. The zooxanthellae, morphological peculiarities and food and feeding habits of the tridacnidae with reference to other lamellibranchs. *Proc. Egypt. Acad. Sci.* **1**. 1–13.
- Mansour, K. 1946. Source and fate of zooxanthellae of the visceral mass of *Tridacna elongata*. *Nature*, London. **158**. 130.
- Reade, P. and Reade, E. 1976. Phagocytosis in invertebrates: Studies on the hemocytes of the clam *Tridacna maxima*. *J. Invert. Pathol.* **28**. 281–290.

The Kidney and Pericardial Glands

- Mansour, K. 1949. The morphological and biological peculiarities of *Tridacna elongata* and *T. squamosa*. *XIII Congr. Int. Zool.*, Paris, 1948. 441–444.
- Morton, B. 1978. The diurnal rhythm and the processes of feeding and digestion in *Tridacna crocea* (Bivalvia: Tridacnidae). *J. Zool.*, London. **185**. 371–387.
- Reid, R.G.B., Fankboner P.V. and Brand D.G. 1984. Studies on the physiology of the giant clam *Tridacna gigas*. *II*.

Kidney function. *Comp. Biochem. Physiol.* **78A**. 103–108.

- Trench, R.K., Wethey, D.S. and Porter, J.W. 1981. Observations on the symbiosis with zooxanthellae among the Tridacnidae (Mollusca, Bivalvia). *Biol. Bull.* **161**. 180–198.
- White, K.M. 1942. The pericardial cavity and the pericardial gland of the lamellibranchia. *Proc. Malacol. Soc., London.* **25**. 37–88.

The Nervous System, The Hyaline Organs and The Statocysts

- Fankboner, P.V. 1981. Siphonal eyes of giant clams (Bivalvia: Tridacnidae) and their relationship to adjacent zooxanthellae. *Veliger* **23**. 245–249.
- Kawaguti, S. and Mabuchi K. 1969. Electron microscopy on the eyes of the giant clam. *Biol. J. Okayama Univ.* **15**. 87–100.
- Morton, B. 1985. Statocyst structure in the Anomalodesmata (Bivalvia) *J. Zool.*, London. **206**. 23–34.
- Stasek, C.R. 1966. The eye of the giant clam (*Tridacna maxima*). *Occasional Papers California Academy of Science.* **58**. 1–9.
- Wilkins, L.A. 1986. The visual system of the giant clam *Tridacna*; behavioral adaptations. *Biological Bulletin.* **170**. 393–408.
- Yonge, C.M. 1936. Mode of life, feeding, digestion and symbiosis with zooxanthellae in the Tridacnidae. *Scientific Report, Great Barrier Reef Expedition, (1928–1929)*. **1**. 283–331.
- Yonge, C.M. 1953. Mantle chambers and water circulation in the Tridacnidae (Mollusca). *Proceedings of the Zoological Society of London.* **123**. 551–561.

The Gonads

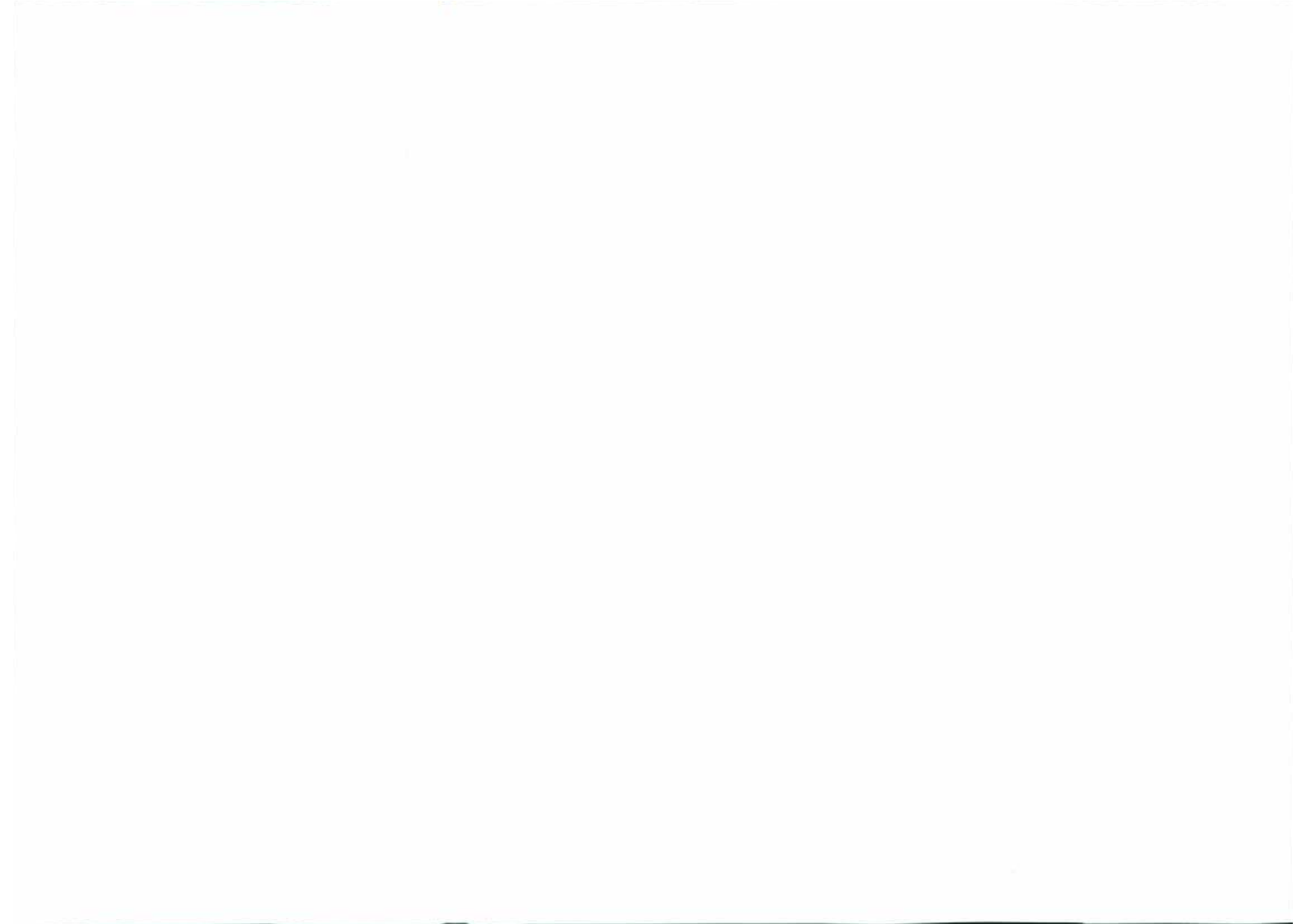
- Kawaguti, S., Masuda Y. and Murakoshi M. 1982. Electron microscopic studies on the gonad of the boring clam, *Tridacna crocea*. *Bull. Kawasaki College of Applied Health Professions*, No. 2. 101–107.
- Nash, W.J., Pearson, R.G. and Westmore, S.P. 1988. A histological study of reproduction in the giant clam

Tridacna gigas in the north-central Great Barrier Reef in Giant Clams in Asia and the Pacific, Copland, J.W. and Lucas, J.S. (ed.), ACIAR monograph no 9, Canberra. Australian Centre for International Agricultural Research. 89–94.

The Zooxanthellal Tube System and Zooxanthellae

- Bishop, D.G., Bain, J.M. and Downton, W.J.S. 1976. Ultrastructure and lipid composition of zooxanthellae from *Tridacna maxima*. *Aust. J. Plant Physiol.* **3**. 33–40.
- Fankboner, P.V. 1971. Intracellular digestion of symbiotic zooxanthellae by host amoebocytes in giant clams (Bivalvia: Tridacnidae) with a note on the nutritional role of the hypertrophied siphonal epidermis. *Biol. Bull.* **141**. 222–234.
- Fankboner, P.V. and Reid, R.G.B. 1990. Nutrition in giant clams (Tridacnidae) In: *The Bivalvia — Proceedings of a Memorial Symposium in Honour of Sir Charles Maurice Yonge, Edinburgh, 1986*. B. Morton (ed.). Hong Kong University Press, Hong Kong.
- Fitt, W.K. and Trench, R.K. 1981. Spawning, development, and acquisition of zooxanthellae by *Tridacna squamosa* (Mollusca, Bivalvia). *Biol. Bull.* **161**. 213–235.
- Goreau, T.F., Goreau N.I. and Yonge C.M. 1973. On the utilisation of photosynthetic products from zooxanthellae and of a dissolved amino acid in *Tridacna maxima* f. *elongata*. *J. Zool., London.* **169**. 417–454.
- Kawaguti, S. 1966. Electron microscopy on the mantle of the giant clam with special reference to zooxanthellae and iridophores. *Biol. J. Okayama Univ.* **12**. 81–92.

- Lee, P.S. 1990. *Aspects of the Biology of Metamorphosis in Tridacnoid clams, with Particular Reference to Hippopus hippopus*. M.Sc. Thesis, James Cook University, Townsville, Australia.
- Mansour, K. 1945. The zooxanthellae, morphological peculiarities and food and feeding habits of the tridacnidae with reference to other lamellibranchs. *Proc. Egyptian Academy of Science.* **1**. 1–13.
- Mansour, K. 1946. Communication between the dorsal edge of the mantle and the stomach of *Tridacna*. *Nature, London.* **157**. 844.
- Mansour, K. 1946. Source and fate of zooxanthellae of the visceral mass of *Tridacna elongata*. *Nature, London.* **158**. 130.
- Mansour, K. 1949. The morphological and biological peculiarities of *Tridacna elongata* and *T. squamosa*. *XIII Congr. Int. Zool., Paris 1948.* 441–444.
- Muscatine, L. 1967. Glycerol excretion by symbiotic algae from corals and *Tridacna* and its control by the host. *Science* **156**. 516–519.
- Taylor, D.L. 1968. *In situ* studies on the cytochemistry and ultrastructure of a symbiotic marine dinoflagellate. *J. Marine Biology Association U.K.* **48**. 349–366
- Trench, R.K., Wethey, D.S. and Porter, J.W. 1981. Observations on the symbiosis with zooxanthellae among the tridacnidae (Mollusca, Bivalvia). *Biol. Bull.* **161**. 180–198.
- Yonge, C.M. 1936. Mode of life, feeding, digestion and symbiosis with zooxanthellae in the Tridacnidae. *Scientific Report, Great Barrier Reef Expedition, (1928–1929).* **1**. 283–331.



GLOSSARY

accumulation body a body in the zooxanthellae in which waste material gathers or collects.
acid a substance which releases H⁺ ions in solution or which has a low pH.
adductor a muscle which brings one part towards another.
afferent conveying towards a centre.
agar a gelatinous or jelly-like compound extracted from red algae.
alkali a substance which has a high pH.
amorphous of irregular shape or form.
anaesthesia induction of a state of reduced response to, or absence of response to pain or sensory stimuli.
anal relating to the anus, the terminal orifice of the gastrointestinal or alimentary tract.
anterior nearer the head end.
aorta the major artery which carries blood or haemolymph from the heart.
artery vessel carrying haemolymph from the heart to the rest of the body.
atrophy to waste away.
auricle the anterior chamber of the heart.
axis the central line of a structure.
basement membrane a layer separating many types of epithelia from underlying tissue, consisting of basal lamina, mucopolysaccharides and a fine fibrous network.
basiphil staining readily with basic dyes.
bivalve a mollusc with two shell valves joined by a hinge.
bladder a membranous sac filled with air or fluid.
branchial pertaining to the ctenidia or gills.
bulbus arteriosus arterial bulb.
byssal pertaining to the byssus
byssus tuft of strong filaments which are secreted by the byssal gland and by which the mollusc is attached to the substrate.
caecum a blind-ended diverticulum or pouch from part of the alimentary canal.

capsule sac-like membrane enclosing an organ.
cardinal that upon which something depends or hinges.
cerebral pertaining to the brain or to the higher nervous centres (in molluscs).
cerebropedal nerve fibres connecting cerebral and pedal ganglia.
chromatin the dark staining material in the nucleus.
chromosomes the small, rod-shaped, deeply staining bodies which become visible in the eukaryotic cell nucleus at mitosis and meiosis and which carry the genes in linear order.
cilia motile, hair-like outgrowths from the surface of a cell.
circumpallial around the mantle.
coalesce to come together to unite.
collagenous containing collagen, a fibrous protein.
columnar column-shaped; e.g. cells longer than broad.
commissure a connecting band of nerve tissue.
connective a connecting band of nerve fibres between two ganglia.
connective tissue the supporting tissues of the animal body, usually applied to fibrous tissue.
cortex the outer layer of a structure or organ.
crenate a notched, indented, scalloped margin.
crenate shaped like a new moon.
crypt a simple glandular tube or cavity.
crystalline style a translucent proteinaceous rod containing carbohydrates and involved in carbohydrate digestion in the alimentary canal.
crystalline style sac a tubular cavity containing the crystalline style.
ctenidia a comb-like structure; applied to the gills.
cuboidal shaped like a cube.
cuticular made of epithelial cells.
cytolysis cell lysis or disintegration.
cytoplasm all the living parts of a cell outside of the nucleus.
degenerating losing its normal functions and structures.

demibranch half of a gill.
digestive gland sac-like portion of intestine which produces digestive enzymes and in which food is digested.
dinoflagellates group of unicellular organisms having two flagellae, one pointing forward and the other wrapping around the body of the organism.
dissection a cutting into pieces to show its parts.
diverticulum a blind-ended tube or sac opening off a canal or cavity.
dorsal upper aspect.
duct a tube which conveys fluid or other material.
efferent conveying away from a centre.
endomysium connective tissue binding muscle fibres.
endothelium cell layer lining the internal surfaces of fluid-filled cavities.
eosinophilic staining readily with eosin (a rose-red dye).
epimysium sheath of areolar connective tissue which encloses the entire muscle.
epithelium sheets of cells tightly bound together, lining any external or internal surface of an organ.
excretory pertaining to the discharge of waste products.
excurrent outgoing current.
fascial pertaining to fascia or bandage-like wrapping of connective tissue.
filament a slender, thread-like structure.
fixation treatment of specimens to preserve structure for microscopy.
follicle bag or sac-like structure.
ganglion structure within the nervous system formed of a mass of nerve cell bodies.
gape to open wide; the distance between the edges of the shell valves when open.
gastric shield a horny structure in the stomach against which the crystalline style rubs and is worn away, releasing amylase.
genital relating to the reproductive system.
gland a single cell or mass of cells specialised to secrete substances either into the body or to the exterior of the body.
globular spheroid or globe-shaped.
glomerular like a glomerulus, a network of blood capillaries.

glycogen a polysaccharide made up of glucose units.
glycoprotein a protein containing a carbohydrate group.
gonad reproductive organ.
gonadal relating to the gonad.
granulocytes cells containing granular structures.
haemolymph blood-like fluid.
hermaphrodite having both male and female reproductive organs.
hinge a movable joint.
histochemical the use of chemicals to demonstrate selected microscopic components of tissues.
histological related to a microscopic study of the detailed structure of cells and tissues.
holocrine a type of cell secretion in which the entire secretory cells are disintegrated and form part of the secretion.
horizontal section a section cut parallel to the plane of the horizon of the organ or clam.
hyaline having the appearance of glass.
inconspicuous not easily seen.
incurrent incoming current.
interdigitating between finger-like processes.
interdiverticulum between the blind-ending tubes or sac openings off a canal or cavity.
interstices intervening crevices, gaps or spaces.
iridophores guanine containing granules, bodies or plates giving a silvery or iridescent reflection.
isthmus a narrow structure connecting two larger parts.
juvenile immature or young.
kidney organ associated with the excretion of wastes.
labia lips.
labial palp lobe-like structure near mouth.
lamella leaf-like structure.
latex a rubber compound.
ligament a strong fibrous band of tissue connecting two or more moveable structures.
lobe a round, projecting part of an organ.
lobular arranged in lobes.
longitudinal section a section cut parallel to the length of the organ or clam.
lumen the internal space of any tubular or sac-like organ.
macrophage large cell which ingests foreign material.

mantle outer (covering) layer of tissue enclosing the clam.
marginal near or pertaining to the edge.
matrix a medium in which a substance is embedded.
maturation the process of becoming fully differentiated and fully functional.
medial situated in the middle.
medulla the central part of an organ or tissue.
membrane sheet-like tissue.
mollusc a soft bodied, usually unsegmented, coelomate animal, many of which are enclosed in a hard shell.
mucin a general term for various glycoproteins found in secretions such as mucus.
mucopolysaccharide sugar or carbohydrate compounds with or without protein.
mucous secreting or containing mucus.
mucus slimy material rich in glycoproteins.
nephridium excretory organ or kidney.
nephridiopore small excretory orifice of kidney (nephridia).
nephrocyte kidney cell which stores and discharges waste products.
nephrolith kidney stone or concretion.
nephrostome opening of nephridial tubule (of kidney) into the body cavity.
neuroglia cells other than neurones found in the nervous system.
neurones nerve cells, the basic unit of the nervous system.
nucleus a large dense organelle bounded by a double membrane which contains the chromatin.
oesophagus that part of the alimentary canal between the mouth (in molluscs) and the stomach.
oblique neither perpendicular nor parallel.
oocyte female ovarian cell in which meiosis occurs to form the egg or ovum.
oral pertaining to the mouth.
orifice opening or mouth of cavity.
ornament something which decorates or adorns.
ovary the female reproductive or sex organ in which ova are produced.
ovum egg.
pallial pertaining to the mantle.
papilla nipple-like projection.

parenchyme the functional or essential elements of an organ.
pedal pertaining to the foot.
pericardial pertaining to the sac or membrane around the heart and enclosing the pericardial cavity.
perimysium connective tissue binding numbers of fibres into bundles and muscles, and continuing into tendons.
periostracal associated with the periostracum.
periostracum the external, non-calcareous, layer of a shell.
perpendicular at right angles to a given line or plane.
plantar the sole or undersurface of the foot.
portal gateway or entrance.
posterior nearer the tail or rear end.
precursor cells cells from which other cells will develop.
primary first, principal, original.
protruberances things bulging out, prominent.
pseudostratified having the appearance of several layers.
pyrenoid a protein body in the chloroplast which is the centre of starch formation.
radial extending out, like rays from a centre.
rectum the posterior part of the intestine or midgut ending in the anus.
refractile ability to deflect light.
renal pertaining to the kidney.
reproductive pertaining to the production or generation of sex cells, including ova and sperm
reticular pertaining to the formation of a network.
retractor muscle a muscle which when contracting, withdraws the parts attached to it towards the body.
rugose with many wrinkles or ridges.
scute a plate of shell.
secondary second in importance or position.
secretory pertaining to secretion, that is the production and release of a material or fluid from a cell or gland.
sheath an outer protective covering.
sinus cavity, depression, groove, hollow.
siphonal shaped like a pipe or tube.
socket a hollow into which something fits.
spawning the act of discharging sperm and ova.
sperm the male reproductive or sex cells produced in the testis.

spermatocyte a male cell in which meiosis occurs to form sperm.

spermatogonium primordial male germ cell, diploid stem cell precursor of male germ cells.

spermatozoa mature sperm or male gamete.

spindle a long slender stalk.

starch a storage carbohydrate found in plants; found in zooxanthellae.

statocyst an organ of balance and gravity detection.

statolith particle of inorganic matter in fluid of statocyst.

stomach the large pouch of the alimentary tract between the oesophagus and the small intestine or midgut.

striations marked with stripes.

subepithelial beneath the covering epithelium of an organ.

suprabranchial above the ctenidia (gills).

supraligamental above the ligament.

symbiotic a close and usually obligatory association of two organisms of different species living together, not necessarily to their mutual benefit.

tentacle slender, flexible process used as a sensory organ.

tertiary third in importance or position.

testis the male reproductive or sex organ in which sperm or spermatozoa are produced.

translucent allowing light to pass through.

transverse section a section cut across the length of the organ or clam.

tubule small tube.

typhlosole median longitudinal fold of the intestine projecting into the lumen of the gut.

umbo a protuberance like a boss on a shield; beak or older part of shell valve of a bivalve mollusc.

vein vessel carrying haemolymph to the heart from the body.

ventral lower aspect; nearer the underside or understructure.

ventricle a small cavity or chamber; one of the heart chambers.

vesicular like a bladder, blister or bubble.

visceral pertaining to the internal organs.

vitelline layer thick transparent layer surrounding the plasma membrane of the ovum.

zooxanthellae small (7-8 μm) brown, single-celled algae (dinoflagellates, *Symbiodinium microadriaticum*) which live within the bodies of animal hosts.

APPENDIX

HISTOLOGICAL STAINS

The histological methods used in this manual are common and can be found in most histotechnological texts e.g. Luna 1968, Drury and Wallington 1980, Bancroft and Stevens 1982 and Crowder 1988.

H & E	Haematoxylin and eosin stain — used routinely for most sections. Harris haematoxylin and eosin — phloxine stain — used for deeper colours for photography.	Alcian blue	Alcian blue stain (pH 2.5) — used for mucosubstances and mucopolysaccharides.
PAS	Periodic acid schiff stain — used for glycogen, mucoid substances and mucopolysaccharides.	Toluidine blue	Toluidine blue stain — used for sulphated acidic mucopolysaccharides.
PAS/diastase	Periodic acid schiff stain/diastase digestion — used to confirm the presence of glycogen; diastase will extract the glycogen and the PAS/diastase stain will be negative. Conventional method using human saliva at room temperature for 30 minutes in place of malt diastase.	PTAH	Mallory's Phosphotungstic acid haematoxylin stain — used to detect striations in muscle.
		Von Kossa	Von Kossa stain used to identify calcium.
		Trichrome	Modified Masson's Trichrome stain used to differentiate connective tissue from muscle tissue.

The following table lists the 'mucin' stains.

Histochemical Identification of the Type of Mucin Present in a Tissue

Stain	Mucin Type			
	Type 1 glycogen (clam) starch (zooxanthellae)	Type 2 neutral mucopolysaccharides & glycoproteins	Type 3 carboxylated and weakly sulphated acid mucopolysaccharides	Type 4 strongly acid mucopolysaccharides
PAS	+	+	+	-
PAS/Diastase	-	+	+	-
Alcian Blue	-	-	+	+/-
Toluidine Blue	-	-	+/-	+

+ = positive; +/- = weak reaction; - = negative



TECHNIQUES

ANAESTHESIA

Anaesthesia induces muscle relaxation and a reduced response or a lack of response when the siphonal mantle is touched. This state may be induced slowly so that the siphonal mantle is fully relaxed and exposed or it may be induced rapidly so that the siphonal mantle is withdrawn.

Slow Method

The aim is to introduce magnesium chloride to make a 10% concentration in the final solution in which the clam is held. For example, if 5 litres of sea water are needed to cover the clam and another 1 litre of distilled (or fresh) water is needed to dissolve the magnesium chloride, the final volume of water will be 6 litres. 10% of 6 litres is 600 grams of magnesium chloride. This is dissolved in the 1 litre of distilled (or fresh) water and then dripped into the 5 litres of sea water containing the clam, at a rate of 5 to 10 ml a minute. A medical or veterinary fluid therapy drip set may be used for convenience. If the rate is too fast, the clam will close its shell valves rapidly and squirt water out of its siphonal orifices. It is ideal to start with the lower rate of 5 ml per minute and as the clam relaxes (becomes less reactive to touch), the rate can be increased. The time to anaesthesia will be about 3 hours.

The magnesium chloride can be of industrial grade or stock feed quality as it is much cheaper than the laboratory or technical grade material. Magnesium sulphate may also be used although it may be a little slower to act than magnesium chloride.

Fast Method

Prepare a saturated solution of magnesium chloride in distilled water. This is done by continuing to add the magnesium chloride until no more dissolves.

Mix equal volumes of saturated magnesium chloride solution and seawater. The mixture should cover the clam. Clams will be anaesthetised in about 15 minutes. This will depend on whether the clam closes its shell valves or not during the procedure.

Another Method of Anaesthesia

Stasek (1962) recommends leaving clams overnight in a 1:1 mixture of isotonic magnesium chloride and sea water. For an isotonic magnesium salt solution, use 7.5% $MgCl_2 \cdot 6H_2O$ or 20% $MgSO_4 \cdot 7H_2O$.

DISSECTION

The adductor muscle, which holds the clam's shell valves closed, must be cut. This may be done by either: (i) anaesthetising the clam or (ii) placing a strong wedge, e.g. of wood, between the dorsal shell valves while they are open. Then slide a long, thin knife or scalpel along the inside surface of one of the shell valves to cut the adductor and byssal-pedal retractor muscles where they attach to the shell (Figs 11, 16, 21, 22). Once this is done, the tension on the shell valves will be relaxed. The attachments of the siphonal retractor muscles to the shell valve along the pallial line (Figs 11, 16) can then be cut free so that the shell valve can be removed after the hinge ligament (Fig. 12) is cut or broken by bending the shell valve back and forth.

The above procedure may be repeated for the remaining shell valve so that all the soft tissues of the clam are removed as a unit from the shell valves. The organs of the clam may be dissected out in the following order: the lateral mantle (Figs 16, 17), the siphonal mantle (Figs 15,

16), the ctenidia and labial palps (Figs 34, 37), the pericardial cavity and heart (Figs 86, 88), the kidneys (Figs 89, 105), the reproductive organ (Figs 137, 138), the digestive mass (Figs 68, 69, 72), the byssal organ and foot (Figs 58, 59, 60) and the adductor muscle (Figs 53, 54).

FIXATION

The major aims of fixation are:

- 1 To prevent autolysis or decomposition due to bacterial and osmotic changes.
- 2 To preserve the tissue as near to its original form as possible.
- 3 To prevent loss of tissue constituents and change in spatial relationships between organelles and macromolecules.
- 4 To protect the tissue against subsequent changes during processing and embedding.
- 5 To give the tissue a texture that facilitates sectioning.
- 6 To render the various tissue constituents reactive to proposed stains.

The procedure for histological examination is as follows. Cut sections of each organ or tissue, not more than 0.5 cm thick, using a new scalpel blade or razor blade. This thickness is important as this is generally the maximum depth into which the preservative will penetrate before the cells deep in the tissue start to degenerate. The area is not as important and a piece of tissue 1 cm by 1 cm would be more than adequate. Place the sections in 10% seawater formalin (see below) in a wide mouthed container for ease of removal when fixed. Ensure there is 10 times the volume of preservative for each volume of tissue.

After the tissues have been in the preservative for 2 or 3 days, they may be taken out, wrapped in paper or cloth dampened with preservative, and placed in double, strong plastic bags, each of which is sealed with packing tape. The tissues may then be placed in a strong container (e.g. cardboard box) to prevent crushing and mailed or sent by courier to a laboratory for histological processing.

IMPORTANT

- 1 Do not send any free formalin through the mail.
- 2 Larval or young juvenile clams up to about 4 months of age should be fixed in 3 to 5% seawater formalin as the 10% seawater formalin will dissolve them.

10% seawater formalin is prepared as follows:

Formalin (40% w/v formaldehyde solution)	100 ml
Filtered seawater	900 ml

Health Precautions when Handling Formalin (or Formaldehyde Solution)

Hazards

- suspected human carcinogen
- flammable
- serious risk of poisoning by inhalation or swallowing
- irritation to skin, eyes and respiratory system
- allergies

Precautions

- 1 Avoid breathing the vapour
- 2 Use in well ventilated area
- 3 Avoid contact with eyes or skin. Wear protective gloves or barrier creams when handling preserved material.
- 4 Wear a cannister respirator during prolonged exposure to fumes or during clean up of a spill.

LATEX INJECTION

Latex injection is a simple and useful method for tracing vessels, small cavities and ducts within the clam. Once set, the elastic nature of the latex enables you to dissect out the vessels and ducts with minimal risk of severing them. The latex can easily be coloured allowing you to inject different pathways with different colours.

Preparation

Latex may be used raw or it may be diluted with distilled water or a weak solution of aqueous ammonia to give a more dilute solution. Water-based paint dyes may be used to colour the latex.

The clam must be fully relaxed and in a fresh state (not fixed). Anaesthetise the clam using the slow method as previously described. Dissect the clam out of the shell taking care not to cut the lateral mantles. This gives you better access to the vessels, ducts or cavities.

Technique

The latex is most easily injected from a 5 or 10ml plastic disposable syringe and needle (18g/16g). The sharp tip of the needle should be broken or cut off to leave a smooth round end to avoid puncture of blood vessels.

Once the desired vessel has been located, place a small incision in it using dissecting scissors. Insert the blunt end of the needle and tie or clamp it in place. For larger vessels finger pressure around the needle may be adequate to prevent the latex from leaking back.

Fill the syringe with latex, connect to the needle, and with a firm even pressure inject the latex into the vessel.

Observe the flow of latex and if a rupture occurs this can be controlled by applying an acidic solution, e.g. acetic acid to the site of the leak. This will cause the latex to set and prevent further leakage.

The key to a successful injection seems to lie in having the clam relaxed. Injection of fixed tissue is often not as successful as the acidic nature of the fixative will tend to set the latex before it penetrates the vessels very far. The addition of a small quantity of alkaline aqueous ammonia may help to overcome this problem.

AGAR EMBEDDING

Embedding a whole clam in agar is a useful technique for studying the gross anatomy of larger clams and for preparing small clams (< 5 cm) for serial sectioning and later histological examination. The agar is used to fill the water cavities of the clam and so support the clam's tissues when the valves are removed. The agar also helps retain the relative position of the organs within the clam.

Preparation

The agar is a simple 4% agar. Heat to dissolve e.g. 65 °C.

i.e.	agar	4 g
	tap water	100 ml

This concentration of agar is rigid enough to support the clam when being cut with a knife or scalpel.

Large Clams

The clam should be anaesthetised using the slow method described above so that it is fully relaxed. The whole clam can then be fixed using 10% sea water formalin. Once fully fixed (3–5 days) the clam can then be embedded in the agar.

First inject the liquid agar into the excurrent orifice. Inject the agar both back over the adductor muscle into the suprabranchial water chamber over the gills, and into the anterior portion of the excurrent water chamber. Rock the clam back and forth to ensure all air bubbles have been removed.

With the clam in as small a container as possible, pour liquid agar into the incurrent orifice, around the gills and let it fill up over the mantle until all the clam is covered. Let the agar set. Once set, the agar over the mantle can be removed and the shells dissected away. The clam is then presented with the mantles fully supported. Thick sections may then be cut to reveal the internal organs with their natural relationships retained.

Small Clams

Anaesthetise the clams. Fill the cavities of the small clams, e.g. 3 to 5 cm shell length, as for the large clams. Allow the agar to set. Use a scalpel blade to remove the shell valves from the soft tissues. Place the clam with its agar contents into 10% formalin saline for a day prior to cutting into slices and processing for histology.

INDEX

A

- abbreviations, 12, 13
- adductor muscle, 17, 28, 29, 39, 50, 65, 76, 77, 110, 115
 - endomysium, 51
 - epimysium, 51
 - fascial sheath, 51
 - perimysium, 51
 - scar, 17
 - visceral ganglion, 50
- algae (*see* zooxanthellae)
- anus, 64, 67, 68
 - mucous gland, 67
 - papilla, 29, 65, 67
- arteries
 - adductor muscle, 75
 - byssal gape, 76
 - byssal-pedal, 75
 - circumpallial, 33, 76, 77, 95, 110
 - pallial, 76
 - pedal, 59
 - pericardial, 76, 79
 - supraligamental (hinge) gland, 76
 - visceral, 75

B

- bulbus arteriosus, 65, 74, 79
- byssus, 11, 28
 - byssal canal, 56, 58
 - crypts, 56, 58
 - ducts, 58
 - gape, 11, 26, 76, 94
 - gape edge, 11, 27
 - glands, 56, 58
 - groove, 56, 59
 - margin, 16
 - organ, 11, 28, 29, 39, 57, 65
 - orifice, 16

- pedal artery, 59
 - ganglia, 56
 - retractor muscles, 18, 56, 59

C

- cerebral commissure, 94
- cilia, 68, 114
 - ciliated crypts, 68
 - ciliated cells, 68
- ctenidia (gills), 11, 28, 29, 38, 44, 76, 78, 111
 - branchial filaments, 42
 - ctenidial axis, 38, 43
 - suspensory ligaments, 39, 43, 44, 50, 57, 110
- demibranchs, 38
 - dorsal, 38
 - ventral, 38
- marginal food groove, 38, 43
- central food groove, 38, 43
- crystalline style, 56, 65
- sac, 56, 64, 65, 110

D

- demibranchs, 38, 39
 - dorsal, 38, 39
 - ventral, 38, 39
- digestive mass (*see also* stomach), 18, 26, 29, 39, 40, 57, 64, 66
 - digestive gland, 11, 64
 - diverticula, 65, 66, 68
 - food grooves, 39, 43
 - gastro-intestinal tract, 66
 - intestinal groove, 64, 68
 - intestine, 11
 - labia, 64
 - mouth, 11, 64

oesophagus, 64, 68
oral groove, 29, 64, 68
dinoflagellates (zooxanthellae), 10, 114

E

endomysium, 51
eosin, 12
epimysium, 51
epithelium, 31–32, 42, 44, 59, 66, 67, 79
 ciliated cuboidal epithelial cells, 34, 43, 52, 66, 67, 87, 100, 114
 columnar cells, 32, 33, 44, 58
 stomach, 67
 tubule, 68
eyes (see hyaline organs)

F

follicles (see reproductive systems)
foot, 26, 28
 pedal artery, 59
 pedal cavity, 26
 pedal nerve, 59

G

glands
 accessory byssal, 59
 anal mucous, 67
 byssal, 56, 58
 digestive, 11, 64
 hinge (supraligamental), 26, 34
 pallial mucous, 27, 35
 pericardial (Kerber's), 28, 85, 88
 auricular, 85
 mantle, 85
 periostacal, 26, 33, 34
 accessory, 33
 glomerular, 33
 plantar, 58
 subepithelial, 32
gonads (see reproductive system), 11, 66, 104
granulocytes, 31, 33, 44, 69, 76, 79, 87, 88, 106

H

haemolymph sinuses, 31, 33, 43, 44, 52, 59, 66, 69, 79, 80, 87
 haemolymph portals, 77

haemotoxylin, 12
heart (see also arteries and veins), 11, 65
 anterior aorta, 74, 79, 80
 auricle, 74, 79
 bulbus arteriosus, 65, 74
 flap valves, 79
 pericardial chamber, 74
 pericardial gland, 85
 pericardium, 29, 74, 115
 posterior aorta, 75, 79
 ventricle, 65, 74, 79

hermaphrodite, 104

hinge, 10, 11, 17
 gland, 26, 34
 ligaments, 18
 margin, 16
 teeth, lateral, 17
 teeth, cardinal, 17, 18, 57

Hippopus hippopus, 8, 30

Hippopus porcelanus, 8, 30

histological stains, 12, 131–132

holocrine secretory cells, 68

hyaline organs, (eyes), 26, 31, 96
 accessory cells, 100
 lens cells, 99

I

iridophores, 26, 31, 114

K

Kerber's glands (see glands, pericardial)

kidneys, (organs of Bojanus), 11, 29, 39, 66, 75, 84–88
 bladder, 84, 87
 nephrocytes, 87
 nephrolyths, 87
 pericardial gland, 85
 renal excretory ducts, (nephridiopores), 84
 renal parenchyme, 84, 110
 renopericardial ducts, (nephrostomes), 84, 87
 visceral-renal haemolymph portals, 77, 84, 88

L

lamella, 38, 42–43, 77, 78

labia, 64, 66, 68

 labial palps, 28, 39, 40, 44, 64, 94
 palp nerve, 94

M

- macrophage, 66, 114
 - centres, 33, 69, 88, 106, 116
- mantle (*see also* pallium)
 - byssal gape, 11, 18, 26, 76
 - dorsal (*see* siphonal)
 - guard tentacles, 26, 28
 - hyaline organs, 26, 31, 99–100
 - incurrent siphonal orifice, 28
 - iridophores, 26
 - isthmus, 26, 34
 - lateral, 17, 26, 28, 33
 - pericardial gland (*see* glands)
 - periostracal gland (*see* glands)
 - periostracal groove, 20
 - siphonal, 11, 17, 26, 28, 33, 39, 74, 76, 77, 110
 - siphonal orifice, 26, 29
 - zooxanthellae, 26
- mouth, 11, 64
 - oral groove, 28, 64, 68
- mucins, 32, 35, 42–44, 52, 58, 66, 87
- muscle (*see also* adductor muscle)
 - anterior byssal/pedal retractor, 28
 - bands, 18, 69
 - bundles, 59
 - fibres, 44, 52, 67, 69, 79, 80, 87, 114
 - posterior pedal/byssal retractor, 17, 28, 56
 - scars (*see* shell)
 - siphonal mantle retractor, 17

N

- nephridia (*see* kidneys)
- nephrocytes (*see* kidneys)
- nephrolith, 87
- nephrostomes (renopericardial orifices), 84
- nervous system, 94
 - cerebral commissure, 94
 - cortex, 99
 - ganglia
 - cerebral, 94
 - pedal, 56, 59, 94
 - visceral, 50, 94
 - medulla, 99

nerves

- branchial, 95
- cerebrovisceral connective, 110
- pallial, 33, 77, 95, 110
- palp, 94

O

- organs of Bojanus (*see* kidneys)
- orientation, 11

P

- pallium (*see also* mantle)
 - circumpallial artery, 33, 95
 - circumpallial vein, 33, 95
 - pallial arteries, 77
 - line, 17, 26, 66, 77
 - mucous gland, 26
 - nerves, 33, 77, 95, 110
 - vein, 76
 - visceral-pallial attachment lines, 18, 28, 66
- pericardium, 29, 66, 75, 79, 115
 - pericardial chamber, 74
- perimysium, 51
- periostracum, 33
- photographs, orientation, 13

R

- rectum, 67, 68
- reproductive systems, 11, 18, 26, 29, 57, 104–107
 - genital ducts, 104, 107
 - gonads, 11, 104–107
 - hermaphrodite, 104
 - oocytes, 105
 - ova, 106
 - ovary, 104
 - peduncle, 106
 - precursor cells, 107
 - spermatocytes, 105
 - spermatogonia, 105
 - spermatozoa, 105
 - testis (male follicles), 104
- retractor muscle, 28, 29
 - byssal-pedal, 28, 56
 - byssal-pedal scar, 17

S

- shell, 16–22
 - adductor muscle scar, 17
 - byssal margin, 16
 - dorsal margins, 16
 - hinge, 17, 18
 - morphology, 21
 - posterior pedal/byssal retractor muscle scar, 17
 - umbos, 16
 - valves, 11, 16, 17, 26, 57
- statocysts, 96, 100
 - basiphilic statolith, 100
 - lumen, 100
- stomach, (*see also* digestive system), 11, 64, 68
 - caeca, 65, 68
 - crystalline style sac, 56, 64, 65, 68
 - gastric shield, 65
 - midgut, 64, 66, 68
 - pouch, 65, 68
 - typhlosole, 65
- supraligamental gland (*see* hinge gland)

T

- techniques
 - agar embedding, 137
 - anaesthesia, 135
 - dissection, 135
 - fixation, 136
 - health precautions, 136
 - latex injection, 136
- teeth, cardinal, 18
 - lateral, 17
- tentacles, (*see also* mantle), 28
- tissues, sectioning of, 13
- Tridacna crocea*, 10, 30
- Tridacna squamosa*, 10, 30

- Tridacna derasa*, 10, 30
- Tridacna gigas*, 10, 11, 30, 96
- Tridacna maxima*, 10, 30
- Tridacna tevoroa*, 10, 30
- typhlosole, 65

U

- umbo, 16, 17, 18
 - umbonal cavity, 17, 57

V


- veins
 - afferent branchial, 76, 77, 78
 - afferent ctenidial, 76, 77
 - afferent venous system, 76
 - circumpallial, 33, 76, 95, 110
 - efferent branchial, 74, 76
 - efferent ctenidial, 76, 77
 - pallial, 77

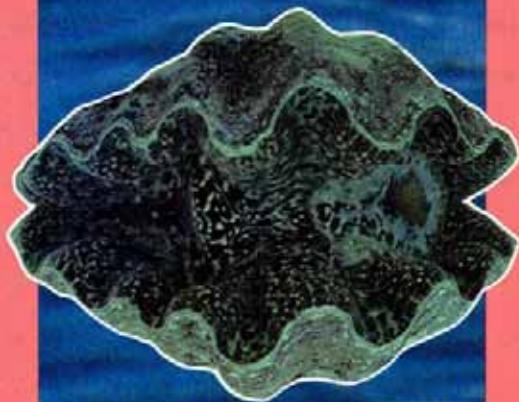
W

- water chambers, 28
 - excurrent, 28, 29, 40, 43, 110
 - incurrent, 28, 29, 40, 43, 57
 - inter-water chamber membrane, 29
 - suprabranchial water compartment, 29, 39, 43, 57

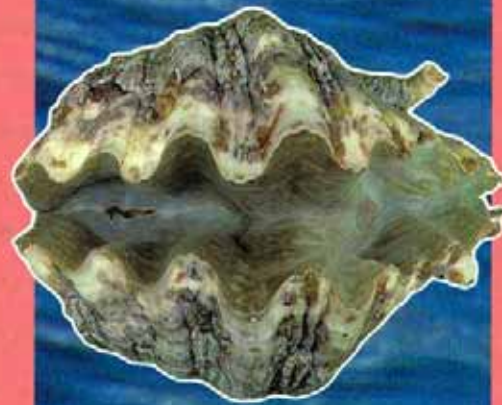Z

- zooxanthellae (dinoflagellates), 10, 11, 26, 31, 44, 52, 69, 79, 100, 111, 114
- zooxanthellal tube system, 30, 44, 52, 77, 87, 95, 110, 114
 - zooxanthellal cell structure, 115
 - accumulation body, 115
 - nucleus, 115
 - pyrenoid, 115





HIPPOPUS PORCELLANUS



HIPPOPUS HIPPOPUS



TRIDACNA TEVOROA



TRIDACNA